

COMPARATIVE HEPATOPROTECTIVE EFFICACY OF KUMARYASAVA AND LIVFIT AGAINST CARBON TETRACHLORIDE INDUCED HEPATIC DAMAGE IN RATS

**Latha T.B¹, Srikanth A¹, Eswar Kumar K², Mastan SK^{3,4*},
Srinivasa Rao Y⁴ and Bhavani B⁴**

¹ Sri Venkateshwara College of Pharmacy, Hi-Tech City Road, Madhapur,
Hyderabad-500 081, Andhra Pradesh, India

¹ Pharmacology Division, University College of Pharmaceutical Sciences, Andhra University,
Visakhapatnam – 530 003, Andhra Pradesh, India

³ Department of Pharmacology, Roland Institute of Pharmaceutical Sciences, Ambapua,
Berhampur (GM) - 760 010, Orissa, India

⁴ Vignan Institute of Pharmaceutical Technology, Duvvada, Vadlapudi Post, Gajuwaka,
Visakhapatnam – 530 046, Andhra Pradesh, India

* Corresponding author, E-mail: shkmastan@gmail.com

Summary

Livfit and Kumaryasava are polyherbal hepatoprotective formulations used in Indian system of medicine. Livfit and Kumaryasava were evaluated for their hepatoprotective efficacy against carbon tetrachloride (CCl₄) induced hepatic injury in rats. Biochemical parameters like total bilirubin, serum glutamic oxaloacetic transaminases (SGOT), serum glutamic pyruvate transaminases (SGPT) and alkaline phosphatase (ALP) and total proteins were estimated to assess liver function. Silymarin used as reference standard also exhibited hepatoprotective activity against carbon tetrachloride. The biochemical observations were supplemented with histopathological examination of rat liver sections. It was concluded from the study that Livfit has shown more significant hepatoprotective activity against CCl₄ induced hepatic damage in rats.

Key words: Hepatoprotective activity, Liver, Kumaryasava, Livfit

Introduction

Liver is the major organ for metabolism and excretion. About 20,000 deaths found every year due to liver disorders. In India, about 40 polyherbal commercial formulations reputed to have hepatoprotective action are being used. It has been reported that 160 phytoconstituents from 101 plants have hepatoprotective activity (1). There are different marketed formulations available for treating liver diseases, viz Livfit, Livomyn, Kumaryasava, Liv-52, Liver cure, Livol, Jigrine and Livogen etc. Livfit and Kumaryasava are popular herbal formulations indicated for liver diseases (2).

Hepatoprotective efficacy of some of the individual herbal ingredients of both the formulations was reported in literature (3-6). The aim of the present study was to compare the hepatoprotective efficacy of two marketed formulations, Livfit and Kumaryasava against carbon tetrachloride induced hepatic damage in rats.

Material and Methods

Animals

Albino rats (175-200 g) procured from Mahaveer Enterprises, Hyderabad, India were used in the study. They were maintained under standard laboratory conditions at ambient temperature of $25\pm 2^{\circ}\text{C}$ and $50\pm 15\%$ relative humidity with a 12-h light/12-h dark cycle. Rats were fed with a commercial pellet diet (Rayans Biotechnologies Pvt Ltd., Hyderabad) and water *ad libitum*. The experiments were performed after prior approval of the study protocol by the institutional animal ethics committee of our institute. The study was conducted in accordance with the guidelines provided by Committee for the Purpose of Control and Supervision of Experiments on Animals (CPCSEA).

Chemicals and Drugs

Livfit (Dabur Ltd, India) and Kumaryasava (Dabur Ltd, India) were used to evaluate the hepatoprotective activity. Silymarin (Micro labs, Tamil Nadu, India) was used as a standard. CCl_4 (E-Merck, Mumbai, India) was used to induce hepatic toxicity. All the biochemicals and chemicals used were of analytical grade.

Evaluation of hepatoprotective activity

The animals were divided into five groups of six rats each. The animals in group I served as control and received distilled water p.o for 14 days. All the animals of group II to V received CCl_4 (0.1 ml/Kg/day; i.p) for 10 days (7). Group III, IV and V animals received the standard drug Silymarin (100 mg/Kg/day; p.o), Livfit (2.85 ml/Kg/day; p.o) and Kumaryasava (3.5 ml/Kg/day; p.o) for 14 days respectively. The CCl_4 , Silymarin, Livfit and Kumaryasava were administered concomitantly to the respective group of animals.

Assessment of hepatoprotective activity

All the animals were sacrificed on day 14 under light ether anesthesia. The blood samples were collected separately by carotid bleeding into sterilized dry centrifuge tubes and allowed to coagulate for 30 min at 37°C . The clear serum was separated at 2500 rpm for 10 min and biochemical investigations were carried out to assess liver function viz., total Bilirubin (8), total protein (9), serum transaminases (10) and serum alkaline Phosphatase (11).

Statistical Analysis

The results are expressed as mean \pm SEM of six animals from each group. The data were evaluated by one-way ANOVA followed by Tukey's multiple comparison test. P values ≤ 0.01 were considered statistically significant.

Histopathology: The liver from all the animals was isolated and washed with the normal saline, blotted with filter paper and weighed (12). Liver was sliced and pieces were fixed in 10% buffered neutral formalin for 48 h and processed for paraffin embedding. The sections were taken at 5 μ thickness using microtome, processed in alcohol-xylene series and were stained with alum-haemotoxylin and eosin (13). The sections were examined microscopically for the evaluation of histological changes.

Results

The results of CCl₄ induced hepatotoxicity are shown in table 1. At the end of 14 days treatment, blood samples of CCl₄ treated animals showed significant increase in the levels of total bilirubin, serum glutamic oxaloacetic transaminases (SGOT), serum glutamic pyruvate transaminases (SGPT) and alkaline phosphatase (ALP) compared to normal control groups but the total protein level decreased reflecting the liver injury caused by CCl₄. Where as blood samples from the animals treated with Livfit and Kumaryasava showed significant decrease in the levels of serum markers and significant increase in total protein to the near normal which are comparable to the values registered in the standard drug treated group of animals, indicating the protection of hepatic cells. It was observed that the size of the liver was enlarged in CCl₄ treated rats but it was normal in drug-treated groups. A significant reduction in liver weight supports this finding.

Histological profile of the control animals showed normal hepatocytes (Figure 1). The section of liver of the group II animals showed severe intense centrilobular necrosis, vacuolization and macro vesicular fatty changes (Figure 2). The liver sections of Silymarin-treated animals showed normal hepatic architecture (Figure 3). Significant liver protection was observed in the liver sections of Livfit treated animals as evident by the presence of normal hepatic cords, absence of necrosis with few fatty lobules and regenerative activity of hepatocytes (Figure 4). However, the liver sections of the animals treated with Kumaryasava exhibited moderate accumulation of fatty lobules (Figure 5).

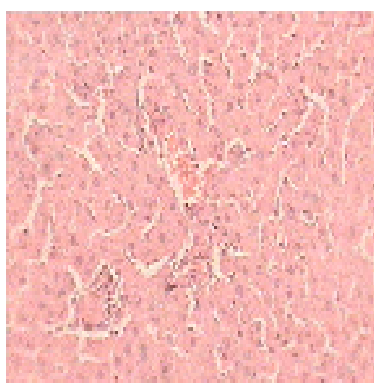


Figure 1: Histopathological examination of liver section of control group

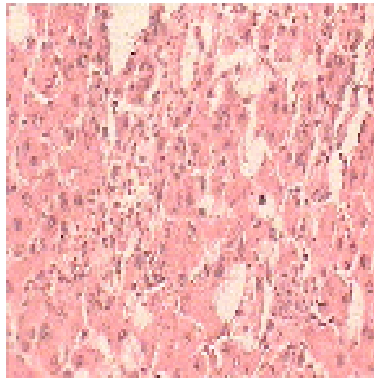


Figure 2: Histopathological examination of liver section of CCl₄ treated group

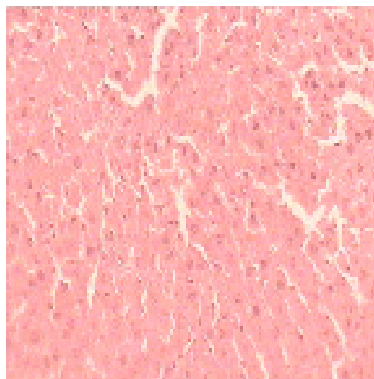


Figure 3: Histopathological examination of liver section of Silymarin treated group

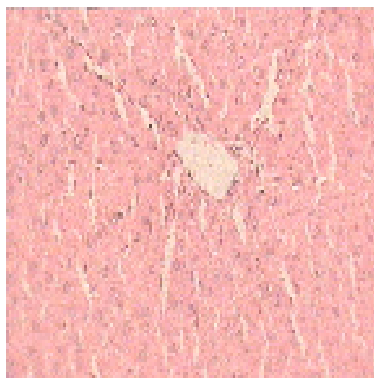


Figure 4: Histopathological examination of liver section of Livfit treated group

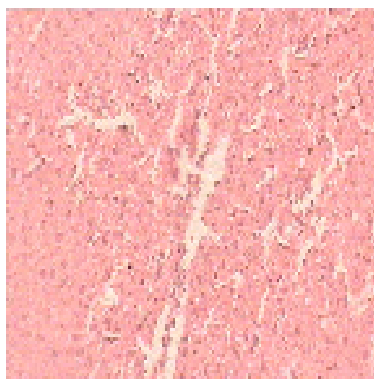


Figure 5: Histopathological examination of liver section of Kumaryasava treated group

Table 1: Effect of Livfit and Kumaryasava on CCl₄ induced hepatotoxicity in rats

Treatment	Dose	Liver (wt/100 g b.wt)	SGPT (U/L)	SGOT (U/L)
Control	-	3.8 ± 0.14	133.7 ± 1.98	46.4 ± 0.82
CCl ₄	0.1 ml/kg	6.8 ± 0.32*	219.4 ± 4.22*	342.7 ± 2.62*
CCl ₄ + Silymarin	100 mg/kg	3.8 ± 0.30**	140.2 ± 2.18**	83.4 ± 4.22**
CCl ₄ + Livfit	2.85 ml/kg	4.5 ± 0.09**	160.2 ± 1.16**	91.7 ± 6.14**
CCl ₄ + Kumaryasava	3.5 ml/kg	4.8 ± 0.08**	168.2 ± 1.22**	100.4 ± 7.10**

* p<0.01 compared to control group ** p<0.01 compared to CCl₄ treated group

Table 2: Effect of Livfit and Kumaryasava on CCl₄ induced hepatotoxicity in rats

Treatment	Dose	ALP (U/L)	Total Bilirubin (mg %)	Total Protein (g %)
Control	-	174.5 ± 1.24	0.50 ± 0.05	9.27 ± 0.14
CCl ₄	0.1 ml/kg	443.3 ± 2.08*	2.24 ± 0.15*	5.10 ± 0.34*
CCl ₄ + Silymarin	100 mg/kg	184.8 ± 1.22**	0.52 ± 0.02**	8.74 ± 0.03**
CCl ₄ + Livfit	2.85 ml/kg	204.6 ± 2.22**	0.67 ± 0.06**	8.19 ± 0.05**
CCl ₄ + Kumaryasava	3.5 ml/kg	238.8 ± 2.32**	0.69 ± 0.06**	8.14 ± 0.06**

* p<0.01 compared to control group ** p<0.01 compared to CCl₄ treated group

Discussion

Carbon tetrachloride is one of the most commonly used hepatotoxins in experimental study of liver disease (14). The lipid peroxidative degradation of biomembrane is one of the principle causes of hepatotoxicity of CCl₄ (15). The hepatotoxic effect of CCl₄ are largely due to its active metabolite trichloromethyl radical (16), which binds to the macromolecule and induce peroxidative degradation of membrane lipids of endoplasmic reticulum rich in polyunsaturated fatty acids. This leads to the formation of lipid peroxide which in turn gives toxic aldehyde that causes damage to liver. This is evident from an elevation in the serum marker analysis (SGOT, SGPT, ALP and total bilirubin). This is indication of cellular leakage and loss of the functional integrity of the cell membrane in liver (17). The biochemical studies in wistar albino rats revealed that CCl₄ induced hepatic injury was significantly inhibited by Livfit and Kumaryasava. All these results were comparable with the standard drug Silymarin.

The comparative Histopathological study of the liver from different groups of rats corroborated the hepatoprotective efficacy of polyherbal formulations. Various pathological changes such as steatosis, centrilobular necrosis and vacuolization observed in CCl₄ treated rats were prevented to a moderate extent in group III, IV and V. All the effects of Livfit and Kumaryasava were comparable with Silymarin as a positive control.

Above results showed that Livfit has shown significant hepatoprotective activity in comparison to Kumaryasava against carbon tetrachloride induced hepatic damage in rats.

Conclusion

Overall, the present study indicates that Livfit and Kumaryasava demonstrated a significant hepatoprotective activity against carbon tetrachloride induced hepatic damage in rats. Moreover Livfit has shown significant hepatoprotective activity in comparison to Kumaryasava.

References

1. S. S. Handa, A. Sharma and K.K. Chakraborti, *Fitoterapia*, 57, 307-351 (1986).
2. P.B. Reddy, C. K. Reddy, D. Rambhau, V. Venkateshvarala and V. N. Murthy, *Anti hepatoprotective activity of some Ayurvedic preparations*, *Indian J. Pharm. Sci.*, 55, 137-140 (1993).
3. S. M. Karandikar, G. V. Jnglekar, G. K. Chitale and J. H. Balwani, *Protection by indigenous drugs against hepatotoxic effects of carbon tetrachloride: A long term study*, *Acta Pharmacol. Et Toxicol.*, 20, 274-280 (1963).
4. M.N. Jindal, V.K. Patel and N. B. Patel, *Some pharmacological activities of aqueous and alcoholic extracts of *Cichorium intybus* Linn*, *Indian J. Pharmacol.*, 7, 104 (1975).

5. A. H. Gilani and K.H. Janbaz, Evaluation of liver protective potential of *Cichorium intybus* seed extract on acetaminophen and CCl₄ induced damage, *Phtomed.*, 1, 193-197 (1994).
6. S. Sultana, P. Shahid, I. Mohammad and A. Mohammad, Crude extracts of hepatoprotective plants, *Solanum nigrum* and *Cichorium intybus* inhibits free radical mediated DNA damage, *J. Ethnopharmacol.*, 45, 189-192 (1995).
7. B. Jaiprakash, R. Aland, R.V. Karadi, R. V. Savadi and V.I. hukkeri, Hepatoprotective activity of fruit pulp of *Balanites aegyptiaca*, *Indian Drugs*, 40, 296-297 (2003).
8. H.T. Mallory and E. A Evelyn, The determination of Bilirubin with photoelectric colorimeter, *J. Biol. Chem.*, 119, 481-485 (1937).
9. S.R. Kingsley and S. J. Frankel, The determination of serum total protein albumin and globulin by the biuret reaction, *J. Biol. Chem.*, 128, 131-137 (1939).
10. S. Reitman and S. A. Frankel, A colorimetric method for the determination of serum glutamic oxaloacetic and glutamic pyruvic transaminases, *Am. J. Clin. Pathol.*, 28, 56-63 (1957).
11. O.A. Bessey, D.H. Lowery and M. J. Brock, A method for the rapid determination of alkaline Phosphatase with five cubic meters of serum, *J. Biol. Chem.*, 164, 321-329 (1964).
12. H. Matsuda, K. Samukawa, M. Kubo, Anti-hepatic activity of Ginsenoside Ro., *Planta Med.*, 57, 523-526 (1991).
13. A. E. Galigher and E. N. Kayloff, In: *Essentials of practical microtechniques*, Philadelphia: lea and Febiger, p.77 (1971).
14. E.Johnson and C. Krocning, Mechanism of early CCl₄ toxicity in cultured rat hepatocytes, *Pharmacol. Toxicol.*, 83, 231-239 (1998).
15. S.Cotran, V. Kumar and S. L. Robbins, Cell injury and cellular death, In: *Robbins Pathologic Basic of Disease*, 5th Edition, Prism Book Pvt. Ltd., p. 379-430 (1994).
16. N. Kaplowitz, T.Y.Aw, F.R. Simon and A.Stolz, Drug induced hepatotoxicity, *Ann. Int. Med.*, 104, 826-839 (1986).
17. R. B. Drotman and G. T. Lawhorn, Serum enzymes as indicators of chemical induced liver damage, *Drug Chem. Toxicol.*, 1, 163-171 (1978).