

**STUDIES ON HEPATOPROTECTIVE ACTIVITY OF
ETHANOLIC EXTRACT OF *CASSIA FISTULA* BARK
AGAINST CCl₄ INDUCED HEPATIC DAMAGE IN WISTAR
RATS**

SUNETRA PATWARDHAN^{1*}, PRASHANT VADNAL¹, ABHAY
KUMAR SINGHAI², RAHUL SOMANI¹

1. Sinhgad College of Pharmacy, Pune-411 041, India.
 2. Dept. of Pharm. Sci., Dr. HS Gour University, Sagar-470 003, India.
- * Corresponding author: sunetra_p@yahoo.co.in

Summary

Hepatoprotective activity of ethanolic extract of *Cassia fistula* bark was investigated against hepatotoxicity induced by administering CCl₄ with olive oil (1:1), 0.2ml/kg for 10 days by intraperitoneal route in wistar rats. Silymarin (100mg/kg, p.o.) and the extracts of *Cassia fistula* bark (CFB 200 and 400 mg/kg, p.o.) were administered concomitantly for 14 days to the respective groups of animals. Hepatoprotective effect of ethanolic extract of *Cassia fistula* bark was evident in the doses of 200 and 400 mg/kg as there was significant decrease in AST, ALT, ALP, triglycerides, bilirubin, and protein levels in comparison to CCl₄ control group. Histology of the liver section of the animals treated with the ethanolic extract of *Cassia fistula* bark in the doses of 200 and 400 mg/kg, further confirmed the hepatoprotective activity.

Keywords: Hepatoprotective, *Cassia fistula* bark, CCl₄

Introduction

Liver is a vital organ of human body, it has been exposed to various hepatotoxicants (Xenobiotics) in our day to day life of modernization especially in the developing countries. Despite of considerable progress in the treatment of liver damage by oral hepatoprotective agents, much attention has been focused on plant derived drugs because synthetic drugs have several limitations.

Cassia fistula Linn. (Family: Caesalpinaceae) is commonly called Indian Laburnum and is native to India, Amazon, Sri Lanka and extensively available in various countries including Mauritius, South Africa, Mexico, China, West Indies, East Africa and Brazil (1). The main medicinal property of *C. fistula* is mild laxative suitable for children and pregnant women. It is also used as a purgative due to the wax aloin and a tonic (2) and has been reported to treat many intestinal disorders like ulcers (3,4). It has been reported as antipyretic and analgesic (5). In the Indian literature, this plant has been described to be useful against skin diseases, liver troubles, tuberculous glands and its use in the treatment of haematemesis, pruritus, leucoderma and diabetes has been suggested (6,7). *C. fistula* extract is used as an anti-periodic and antirheumatism (3,4) and the leaf extract is also indicated for its anti-tussive and wound healing properties (8,9). It has been reported that plant parts could be used as a therapeutic agent in the treatment of hypercholesterolaemia partially due to their fibre and mucilage content (10). There are reports indicating its antibacterial activity against a wide spectrum of bacteria namely *Escherichia coli*, *Bacillus mycoides*, *Bacillus subtilis*, *Mycobacterium smegmatis*, *Klebsiella aerogenes*, *Pseudomonas aerogenes* and *Proteus vulgaris* (11). Antitumor (12), antifertility (13), antioxidant (14,15,16) action of *C. fistula* as well as its effects on the central nervous systems (17) and inhibitory effect on leukotriene biosynthesis (18) have been documented. The hepatoprotective activity was reported for *C. fistula* leaf extract (19). Besides its pharmacological uses, the plant extract is also recommended as a pest and disease control agents in India (20, 21, 22). Thus *C. fistula* is well anchored in its traditional uses and has now found widespread acceptance across the world.

However, it was considered worthwhile to screen *Cassia fistula* bark for its hepatoprotective activity against CCl₄ induced hepatotoxicity.

Methods

Collection of plant material and preparation of extract

Fresh barks of *Cassia fistula* were collected from the local area and were authenticated from Botanical Survey of India, Pune (Voucher no. SKCFP1). Freshly collected bark were washed in tap water and shade dried. The dried barks were crushed into a coarse powder. The ethanolic (95%) extract was prepared by maceration. The ethanolic bark extract (CFB) was evaporated to dryness under reduced pressure (% yield = 1.22% w/w).

Preliminary phytochemical screening

The extract was screened for preliminary phytochemical tests for presence of alkaloids, glycosides, sterols, flavonoids, fatty and volatile oils tannins and phenolic compounds etc

Animals

Wistar rats (180-200g) of either sex were maintained at uniform laboratory conditions in standard steel cages and provided with food and water *ad libitum*. The animals were maintained under laboratory condition for an acclimatization period of seven days before performing experiments. Institution Animal Ethics Committee has approved the protocol (SCOP/IAEC/Approval/2006-07/06).

Acute toxicity study

Acute toxicity studies were carried out using acute toxic class method as per OECD guideline 425. Acute toxicity for *Cassia fistula* bark extracts was studied using groups of three Swiss albino mice of same age group and weight were taken in a single dose up to the highest dose of 2000 mg/kg orally. The animals were observed for 1 h continuously and then hourly for 4 h and finally after every 24 h up to 15 days for any mortality or gross behavioral changes.

Experimental design

Five groups of wistar rats were used for the study (n=5). The rats from Group I served as the control and received the vehicle at a dose of 1 ml/ kg/day, p.o. for 14 days. Groups II-V received 0.2 ml/kg, i.p. of CCl₄ + olive oil (1:1) for 10 days (23). The standard drug Silymarin (Sigma, Germany) was administered to Group III at the dose of 100 mg/kg, p.o. for 14 days, Groups IV and V were treated with CFB at dose of 200 and 400 mg/kg/day, p.o. for 14 days respectively. The CCl₄, Silymarin and the CFB were administered concomitantly to the respective group of rats.

Assessment of biochemical parameters

All the rats were sacrificed on day 14 under light ether anaesthesia. The blood samples were collected by retro orbital method into sterilized dry centrifuge tubes and allowed to coagulate for 30 min at 37°C. The clear serum was separated at 2500 rpm for 10 min and biochemical investigations were carried out to assess liver function viz., AST, ALT, ALP, triglycerides, bilirubin, and protein using commercial diagnostic kits (Biolab, Mumbai).

Histopathology study

After draining the blood, liver samples were excised, washed with normal saline and processed for histopathological observations. The sections were stained with hematoxylin and eosin and examined microscopically at 400X.

Statistical analysis

The data were evaluated by student's t test. P values <0.05 were considered statistically significant.

Results

Preliminary phytochemical screening

The ethanolic extract of *C. fistula* bark subjected for preliminary phytochemical study showed the presence of proteins, steroids, flavonoids, anthraquinone glycosides and tannins.

Acute toxicity study

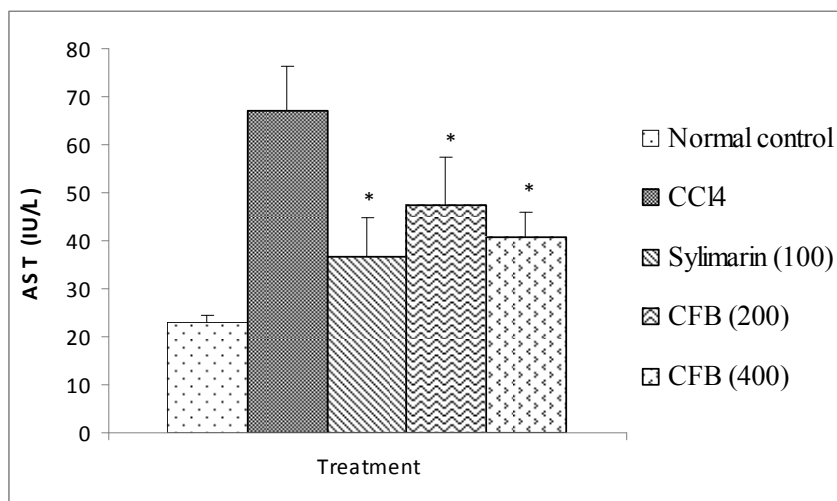
The ethanolic extract of *Cassia fistula* bark did not have any toxic effects up to 2000 mg/kg dose. The animals were alive, healthy and active during the observation period.

Assessment of biochemical parameters

The administration of CCl₄ to the animals resulted in a marked increase in serum AST, ALT, ALP, triglycerides, bilirubin and protein levels. The toxic effect of CCl₄ was controlled in the rats treated with the CFB by restoration of the levels of the liver function biochemistry similar to that of the standard drug Silymarin. Treatments with ethanolic extract of *C. fistula* bark showed significant ($P<0.05$) hepatoprotective activity.

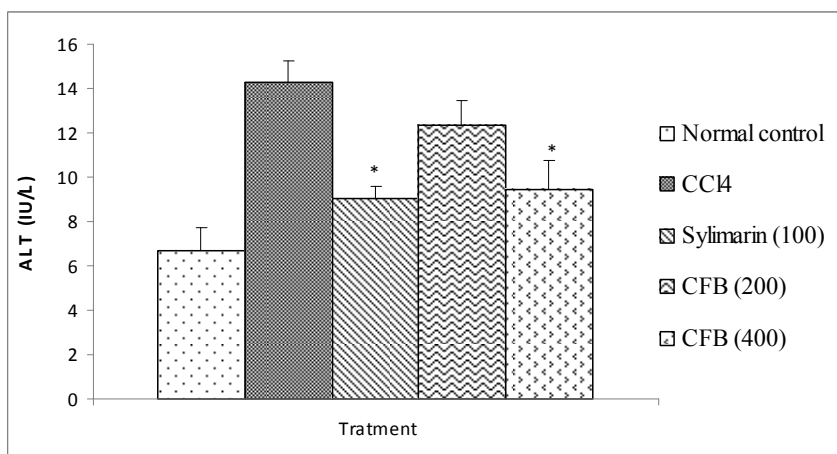
Histopathological observations

Histological profile of the control rats showed normal hepatocytes (NH) and central vein (CV) (Fig. 9A). Group II rats exhibited intense centrilobular necrosis (N), vacuolization (V) and macrovesicular fatty change (F) (Fig. 9B). The sections of liver taken from the rats treated with standard drug Silymarin showed the hepatic architecture, which was similar to that of control (Fig. 9C). The rats treated with CFB exhibited significant liver protection against the CCl₄ as evident by the presence of normal hepatic cords, absence of necrosis and lesser fatty infiltration (Fig. 9D and 9E).

Fig. 1: Effect of ethanolic extract of *C. fistula* bark on AST

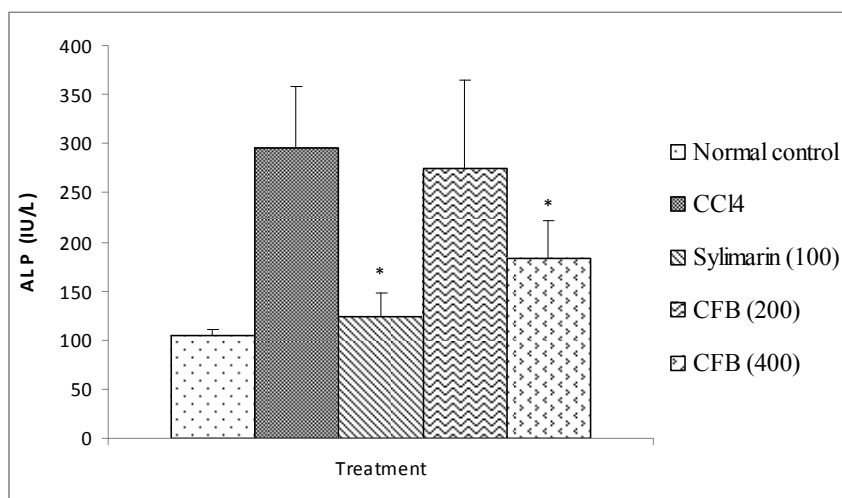
n=5, values are expressed as mean±SEM

* P< 0.05 compared to control group (student's t test)

Fig. 2: Effect of ethanolic extract of *C. fistula* bark on ALT

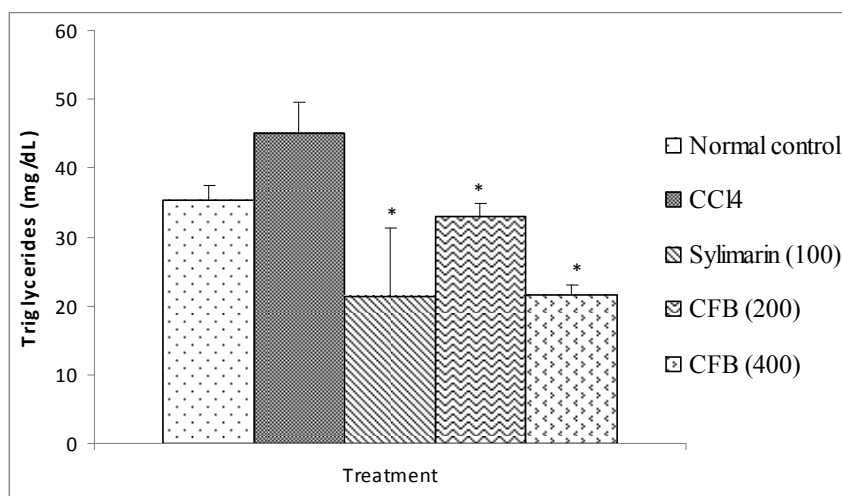
n=5, values are expressed as mean±SEM

* P< 0.05 compared to control group (student's t test)

Fig. 3: Effect of ethanolic extract of *C. fistula* bark on ALP

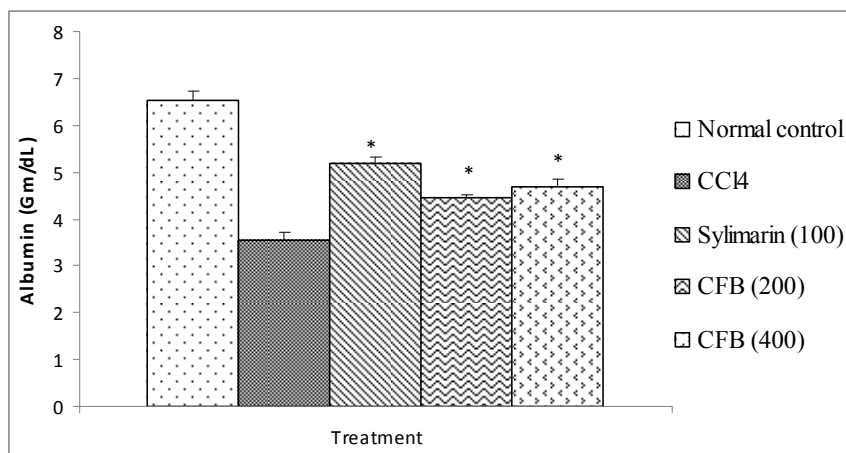
n=5, values are expressed as mean±SEM

* P< 0.05 compared to control group (student's t test)

Fig. 4: Effect of ethanolic extract of *C. fistula* bark on Triglycerides

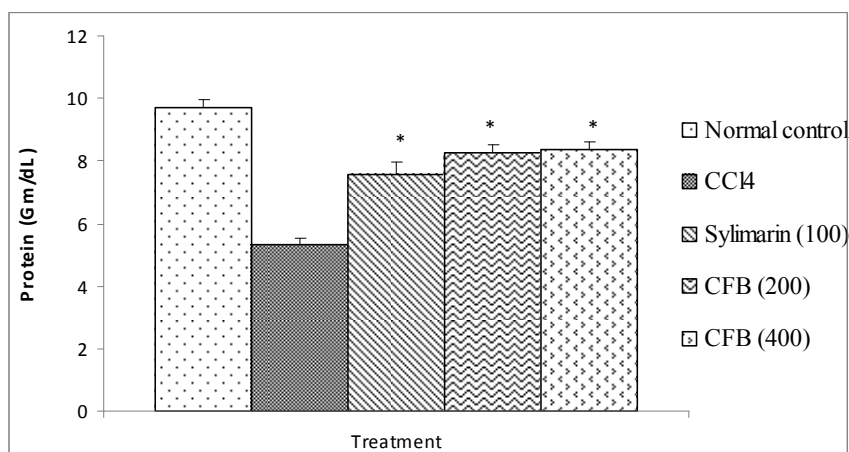
n=5, values are expressed as mean±SEM

* P< 0.05 compared to control group (student's t test)

Fig. 5: Effect of ethanolic extract of *C. fistula* bark on Albumin

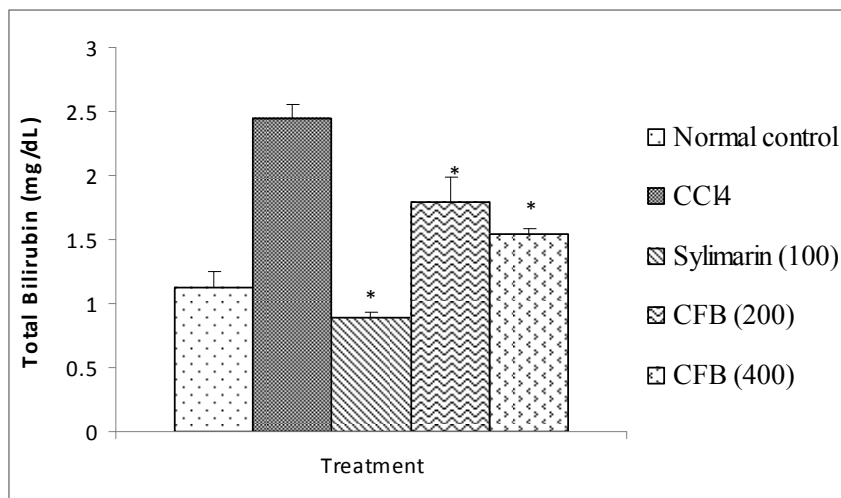
n=5, values are expressed as mean±SEM

* P< 0.05 compared to control group (student's t test)

Fig. 6: Effect of ethanolic extract of *C. fistula* bark on Protein

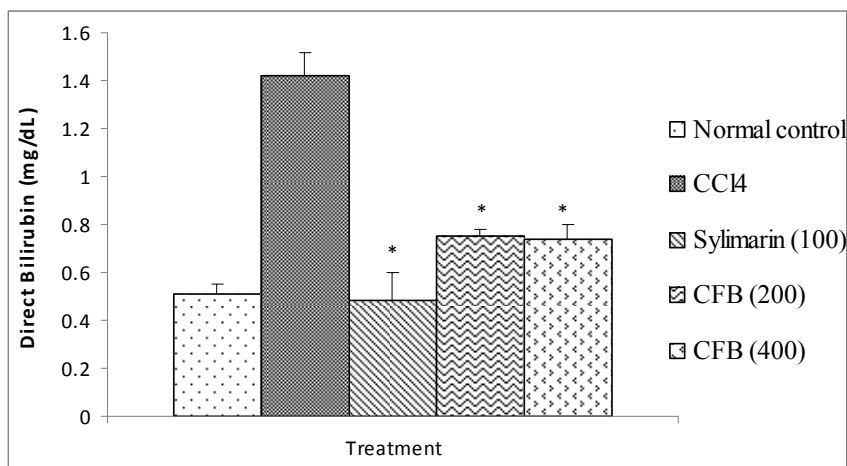
n=5, values are expressed as mean±SEM

* P< 0.05 compared to control group (student's t test)

Fig. 7: Effect of ethanolic extract of *C. fistula* bark on Total Bilirubin

n=5, values are expressed as mean±SEM

* P< 0.05 compared to control group (student's t test)

Fig. 8: Effect of ethanolic extract of *C. fistula* bark on Direct Bilirubin

n=5, values are expressed as mean±SEM

- P< 0.05 compared to control group (student's t test)

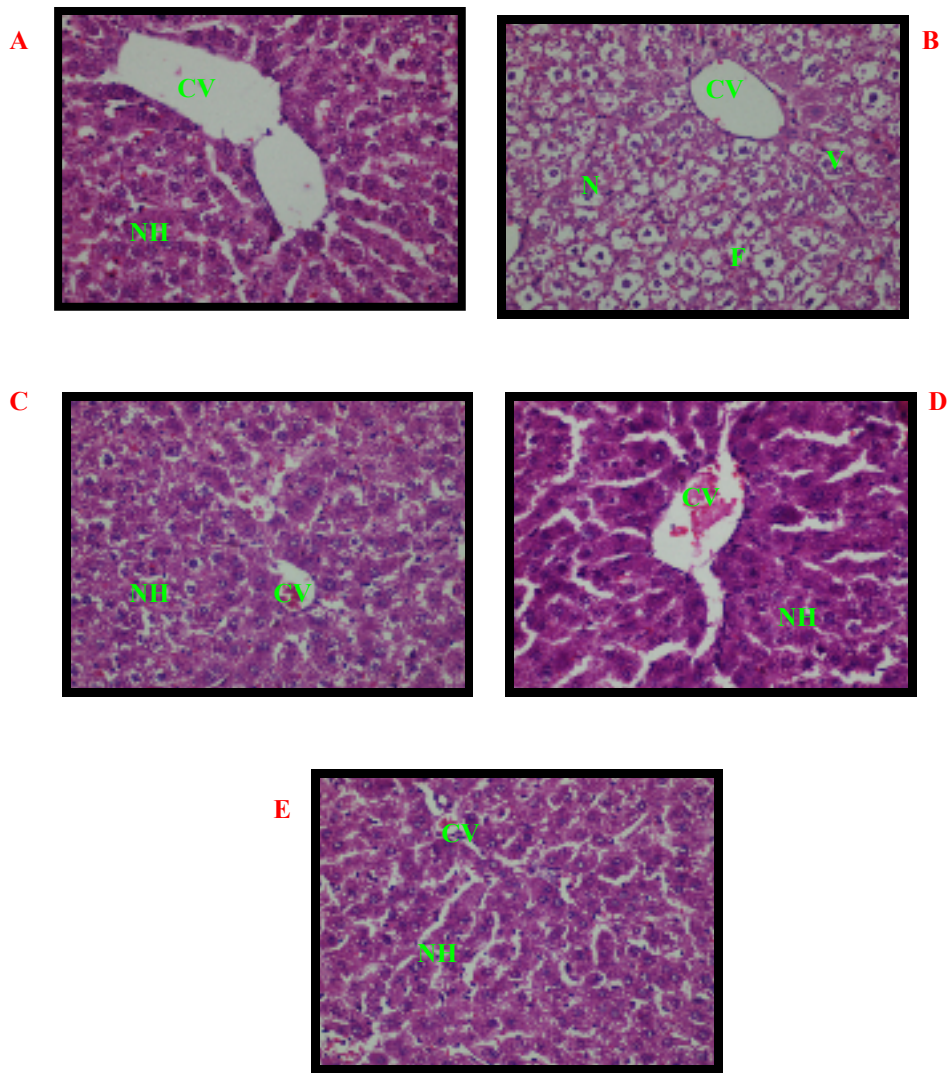


Fig 9: Liver Transverse section of hepatic cells of A] Normal (vehicle 1ml/kg) B] CCl₄+olive oil (0.2ml/kg) C] CCl₄+Silymarin (100mg/kg) D] CCl₄+CFB (200mg/kg) E] CCl₄+CFB (400mg/kg) at 400X.

Discussion

The CCl₄ has been used as a tool to induce hepatotoxicity in experimental animals (24, 25). It is well established that hepatotoxicity by CCl₄ is due to enzymatic activation to release CCl₃ radical in free state, which in turn disrupts the structure and function of lipid and protein macromolecule in the membrane of the cell organelles (26). This toxic chemical caused peroxidative degradation in the adipose tissue resulting in fatty infiltration of the hepatocytes. The increased level of AST, ALT, ALP, and bilirubin is conventional indicator of liver injury. In the present study also, it was observed that administration of CCl₄ elevates the levels of serum marker enzymes AST, ALT, ALP, bilirubin, triglycerides and decrease level of total protein. The increased in the levels of serum bilirubin reflected the depth of jaundice and the increase in transaminases and alkaline phosphatase was the clear indication of cellular leakage and loss of functional integrity of the cell membrane (27). The treatment with CFB at 200, 400mg/kg stabilizes serum AST, ALT, ALP, bilirubin, triglycerides levels and elevated total protein levels towards normal values significantly. Reduction in levels of AST and ALT by the extracts is an indication of stabilization of plasma membrane as well as repair of hepatic tissue damage caused by CCl₄. This effect is agreement with the commonly accepted view that serum levels of transaminases return to normal with the healing of hepatic parenchyma and regeneration of hepatocytes (28). The stabilization of liver cells by CFB is a clear indication of its improvement in the functional status. Further it has been reported that flavonoid constituents of plant possess antioxidant properties which may show free radical scavenging and anti lipid peroxidant activities against CCl₄ induced hepatic toxicity (29). The antioxidant activity of stem bark, leaves, flowers and pulp of *C. fistula* has been reported and correlated with the total polyphenolic/ flavonoid content of the respective extracts. The stem bark had more antioxidant activity in terms of reducing power, inhibition of peroxidation, O₂⁻ and DPPH radical scavenging ability (15). This may prove useful in treatment of liver damage.

Thus, *Cassia fistula* bark possesses potential to protect the liver against CCl₄ induced hepatotoxicity in rats.

Acknowledgement

The authors wish to thank Prof. M.N. Navale, Founder President, STES and Dr. K.S. Jain, Principal, SCOP for providing facilities to carry out this work.

References

1. Bahorun T, Neergheen VS, Aruoma OI. Phytochemical constituents of *Cassia fistula*. *Afr J Biotechnol* 2005;4:1530–1540.
2. Satyavati GV and Sharma M. Medicinal Plant in India, ICMR, New Delhi 1989.
3. Biswas K, Ghosh AB. In Bharatia Banawasadhi, Calcutta University, Advancement of learning, Calcutta 1973;2:336.
4. Kirtikar KR, Basu BD, Singh B, Pal Singh M. Indian Medicinal Plants. Dehradun 1975;2:858.
5. Patel DG, Karbhari SS, Gulati OD, Gokhale SD. Antipyretic and analgesic activities of *Aconitum spicatum* and *Cassia fistula*. *Arch Int Pharmacodyn Ther* 1965;157:22–27.
6. Alam MM, Siddiqui MB, Hussian W. Treatment of diabetes through herbal drugs in rural India. *Fitoterapia* 1990;61:240–242.
7. Asolkar LV, Kakkar KK, Chakre OJ. Second supplement to glossary of Indian medicinal plant with active principles. In: Publication and Information Directorate, New Delhi. CSIR, I, 1992:177.
8. Bhakta T, Mukherjee PK, Pal M, Saha BP. Studies on antitussive activity of *Cassia fistula* (Leguminosae) leaf extract. *Pharm Biol* 1998a;36:140–143.
9. Bhakta T, Mukherjee PK, Mukherjee K, Pal M, Saha BP. Studies on *in vivo* wound healing activity of *Cassia fistula* Linn. Leaves (Leguminosae) in rats. *Nat Prod Sci* 1998b;4:84–87.
10. El-Saadany SS, El-Massry RA, Labib SM, Sitohy MZ. The biochemical role and hypocholesterolaemic potential of the legume *Cassia fistula* in hypercholesterolaemic rats. *Die Nahrung* 1991;35:807-815.
11. Perumal R, Samy S, Iggnacimuthu S, Sen A. Screening of 34 medicinal plants antibacterial properties. *J Ethnopharmacol* 1998;62:173-182.

12. Gupta M, Mazumder UK, Rath N, Mukhopadhyay DK. Antitumour activity of methanolic extract of *Cassia fistula* L. seed against Ehrlich ascites carcinoma. *J Ethnopharmacol* 2000;72:151-156.
13. Yadav R, Jain GC. Antifertility effect of aqueous extract of seeds of *Cassia fistula* in female rats. *Adv Contraception* 1999;15:293-301.
14. Chaminda T, Munasinghe J, Seneviratne CK, Thabrew MI, Abeysekera AM. Antiradical and antilipoperoxidative effects of some plant extracts used by Sri Lankan traditional medical practitioners for cardioprotection. *Phytother Res* 2001;15:519-523.
15. Siddhuraju P, Mohan PS, Becker K. Studies on the antioxidant activity of Indian Laburnum (*Cassia fistula* L.): a preliminary assessment of crude extracts from stem bark, leaves, flowers and fruit pulp. *J Agric Food Chem* 2002;79:61-67.
16. Luximon-Ramma A, Bahorun T, Soobrattee MA, Aruoma OI. Antioxidant activities of phenolic, proanthocyanidins, and flavonoid components in extracts of *Cassia fistula*. *J Agric Food Chem* 2002;50:5042-5047.
17. Mazumdar UK, Gupta M, Rath N. CNS activities of *Cassia fistula* in mice. *Phytother Res* 1998;12: 520-522.
18. Sunil Kumar KC, Muller K. Inhibition of leukotriene biosynthesis and lipid peroxidation in biological models by the extract of *Cassia fistula*. *Phytotherapy Res* 1998;12:526-528.
19. Bhakta T, Mukherjee PK, Mukherjee K, Banerjee S, Mandal SC, Maity TK, Pal M, Saha BP. Evaluation of hepatoprotective activity of *Cassia fistula* leaf extract. *J Ethnopharmacol* 1999;66:277-282.
20. Jaipal S, Sing Z, Chauhan R. Juvenile hormone like activity in extracts of some common Indian plants. *Indian J Agric Sci* 1983;53:730-733.
21. Sharma BK, Basandrai AK. Efficacy of some plant extracts for the management of Karnal bunt [*Neovossia (Tilletia) indica*] of wheat (*Triticum aestivum*). *Indian J Agric Sci* 1999;69:837-839.
22. Raja N, Albert S, Ignacimuthu S. Effect of solvent residues of *Vitex negundo* Linn. and *Cassia fistula* Linn. on pulse beetle, *Callosobruchus maculatus* Fab. and its larval parasitoid, *Dinarmus vagabundus* (Timberlake). *Indian J Exp Bot* 2000;38:290-292.

23. Jaiprakash B, Aland R, Karadi RV, Savadi RV, Hukkeri VI. Hepatoprotective activity of fruit pulp of *Balanites aegyptiaca*. Indian Drugs 2003;40:296-297.
24. Recnagel RO. Carbon tetrachloride hepatotoxicity statusquo and future prospects. Trends Pharmacol Sci 1983;4:129-131.
25. Okuno H, Hazama H, Muraze T, Shiozaki Someshima YT. Drug metabolizing activity in rats with chronic liver injury, induced by carbon tetrachloride relationship with the hydroxyproline content in liver. Jpn J Pharmacol 1986;41:363-371.
26. Mujumdar AM, Upadhye AS, Pradhan AM. Effect of *Azadirachta indica* leaf extract on CCl₄ induced hepatic damage in albino rats. Indian Journal of Pharmaceutical Sciences 1998;60:363-367.
27. Saraswat B, Visen PK, Patnaik GK, Dhawan BN. Anticholestic effect of picroliv, active hepatoprotective principle of *Picrorhiza kurrooa*, against carbon tetra chloride induced cholestatis. Indian J Exp Biol 1993;31:316-318.
28. Thabrew MI, Joice PDTM, RajatissaWA. Comparative study of efficacy of *Paetta indica* and *Osbeckia octandra* in the treatment of liver dysfunction. Planta Medica 1987;53:239-241.
29. Hesham R, El- Seedi, Nishiyama S. Chemistry of Bioflavonoids. Indian J Parm Educ 2002;36:191-194.