

**EVALUATION OF WOUND HEALING ACTIVITY OF *BUTEA MONOSPERMA* LAM. EXTRACTS ON RATS**

C.C. Gavimath<sup>1</sup>, H. V. Sudeep<sup>1</sup>, P. S. Sujan Ganapathy<sup>1</sup>, S. Padmalatha Rai<sup>2</sup> and Y. L. Ramachandra<sup>1\*</sup>

<sup>1</sup> Department of P.G. Studies and Research in Biotechnology, Kuvempu University, Shankaraghatta - 577 451, Karnataka, India.

<sup>2</sup>Department of Biotechnology, Manipal Life Science Center, Manipal University, Manipal-576104, India.

*Corresponding author: \* ylrpub@gmail.com*

### **Summary**

*Butea monosperma* Lam. (Fabaceae) is a medium sized deciduous tree known for its antimicrobial, antiulcerogenic, anti-inflammatory properties etc. The present study was aimed for wound healing potential of ethanol and aqueous extract of *B. monosperma* (stem bark) using three types of wound models in rats as incision wound, excision wound and dead space wound. The results were obtained in terms of wound contraction, epithelialization time, tensile strength, hydroxyproline content and granuloma weight. Enhanced wound contraction and decreased epithelialization time were observed in extract-treated animals in excision wound model. The tensile strength of the incision wound was significantly increased in comparison to control group. The granulation tissue weight and hydroxyproline content in the dead space wounds were also increased significantly in treated animals compared with control.

**Keywords:** *Butea monosperma*, Fabaceae, Wound healing

### **Introduction**

Since mediaeval times plants played an important role in the life of human as the major source of food as well as for the maintenance and improvement of health. According to the World Health Organization (WHO) about 80% of the world's population still relies on plant-based medicines for their primary health care. This in fact is a clear indication for the role of medicinal plants in the maintenance of health and treatment of diseases as therapeutic alternatives throughout the world, still present century [1].

Wound care can be traced back to early civilizations, and many of these treatments were based on the use of herbal remedies. Approximately one-third of all traditional medicines in use are for the treatment of wounds and skin disorders, compared to only 1–3% of modern drugs [2]. Reports about medicinal plants affecting various phases of the wound healing process, such as coagulation, inflammation, fibroplasia, collagenation, epithelization and wound contraction are abundant in the scientific literature [3, 4, 5, 6]. However, many traditional remedies are based on systematic observations and methodologies and have been time-tested but for many of them, scientific evidence is lacking.

*Butea monosperma* Lam. is a medium sized deciduous tree, found in greater parts of India. The plant has been heavily promoted for a wide range of uses; including microbial infections, inflammation, ulcers [7] etc. The present study was designed to test the *in vivo* wound healing activity of the ethanol and aqueous extracts of stem bark of *B. monosperma*.

## **Methods**

### **Plant material and preparation of the extract**

The stem bark of *B. monosperma* was collected from local areas in Belgaum district, Karnataka during early summer. The plant material was identified by Prof. N.A. Jadhav, Department of Botany, B.K. college, Belgaum. The voucher specimen of the plant was kept in the Department of Biotechnology, Kuvempu University, Shankaraghatta.

The plant material was shade-dried and powdered using a mechanical grinder. It was then soaked in ethanol (LR grade, Merck, India) and water separately and kept on a rotary shaker for 24 h. Each extract was filtered under vacuum through a Whatman No. 1 filter paper and the process repeated until all soluble compounds had been extracted. Extraction was considered to be

complete when the filtrate had a faint colour. The extracts were evaporated to dryness under reduced pressure using a Rotavapor (Buchi Flawil, Switzerland).

### **Animals**

Healthy inbred Albino rats of Wistar strain, weighing about 150-200 g of either sex were obtained from Venkateshwara enterprises, Bangalore. All animals were housed, fed and treated in accordance with the in-house guidelines for animal protection. Animals were kept for 2 weeks to be acclimatized prior to the investigation. During this time they were given standard pellet diet and water *ad libitum*. Also, they were periodically weighed before and after experiments. Animals were closely observed for any infection; those which showed signs of infection were separated and excluded from the study. The rats were anaesthetized prior to infliction of the experimental wounds. Acute toxicity study was performed by stair case method [8]. 200 mg/kg body weight was taken as the therapeutic dose of the ethanol and aqueous extract of stem bark of *B. monosperma*. The study was performed with due permission from Institutional Animal Ethics committee (SETCP/IAEC/07/462).

### **Wound healing activity**

The animals were kept under starvation for 12 hrs prior to wounding. Wounds were made on the animals under light ether anaesthesia. Animals were divided into two groups of six animals each. Control group of animals were given 1ml of normal saline, first test group animals received the suspension of ethanolic extract and second test group animals received aqueous extract at a dose of 200 mg/kg b.w. by gavage from the day of wounding. Excision wound, incision wound and dead space wound models were used to evaluate wound healing activity.

### **Excision wound model**

Under light ether anaesthesia each animal was secured to operation table in its natural position. An impression was made on the depilated dorsal thoracic central region of the rats, 5.0 cm away from the ears by using a round seal of 2.5 cm diameter. The extract was given everyday up to 16<sup>th</sup> day [9].

### **Incision wound model**

Each animal was secured to operation table in its natural position under light ether anesthesia. Two Para-vertebral straight incisions of 6.0 cm each were made on the depilated back of the animals by cutting through the entire skin with the help of a sterilized scalpel. After complete haemostasis, the wounds were closed (sutured) using 2-zero silk threads as interrupted sutures about 1.0 cm apart with the help of a straight round bodied needle. The sutures were removed on 8<sup>th</sup> post wounding day [10].

### **Dead space wound model (Granuloma studies)**

Under light ether anesthesia, dead space wounds were created by subcutaneous implantation of sterilized cylindrical grass piths (2.5cm X 0.3cm), one on either side of the dorsal paravertebral surface of rat [11]. The granulation tissues formed on the grass piths were excised on 10<sup>th</sup> post wounding day and the breaking strength was measured. Simultaneously, granulation tissue so harvested was subjected to hydroxyproline estimation (12).

### **Wound healing evaluation parameters**

#### **Wound contraction and epithelialization time**

An excision wound margin was traced after wound creation by using transparent paper and area measured by graph paper. Wound contraction was measured in each 4 days interval,

until complete wound healing and expressed in percentage of healed wound area. The percentage of wound closure was calculated. The period of epithelialization was calculated as the number of days required for falling of the dead tissue without any residual raw wound.

#### **Collagen content from regenerated tissues of excision wound**

The regenerated tissue collected from the excision wounds were cut into two pieces. They were washed with 0.5 M sodium acetate and then suspended in ten parts (w/v) of 0.5M acetic acid and stirred intermittently for 48 hrs. The solution was centrifuged at 5600 rpm for 2 hrs intermittently in the micro centrifuge, and then sodium chloride (5% w/v) solution was added to precipitate the collagen. The collagen so precipitated was filtered using a preweighed Whatman filter paper No.1. The weight of the collagen precipitate obtained was calculated by taking difference between the initial and final weight of the filter paper. The same procedure was followed for the animals of the control and both the test groups.

#### **Measurement of tensile strength**

Tensile strength is the resistance to breaking under tension. It indicates how much the repaired tissue resists to breaking under tension and may indicate in part the quality of repaired tissue. Sutures were removed on the day 8 after wound creation and the tensile strength was measured. The skin breaking strength of the 10-day-old wound was measured by continuous constant water technique of Lee and Tong (1968) [13]. The skin breaking strength is expressed as the minimum weight (in grams) of water necessary to bring about the gapping of the wound.

#### **Hydroxyproline estimation**

Tissues were dried in a hot air oven at 60–70 °C to constant weight and were hydrolyzed in 6 N HCl at 130 °C for 4 hrs in sealed tubes. The hydrolysate was neutralized to pH 7.0 and was subjected to Chloramine-T oxidation for 20 min. The reaction was terminated by addition of

0.4 M perchloric acid and color was developed with the help of Ehrlich reagent at 60 °C [12] and measured at 557 nm using a spectrophotometer.

### **Granuloma weight**

The granulomas were excised from the surrounding tissue on 10<sup>th</sup> post wounding day and were dried at 60 °C to obtain constant dry weight [14].

### **Histological Study**

Granulation tissues obtained on day 10 from the test and control group animals were sectioned for histological study and stained for collagen with Van Gieson's stain.

### **Statistical analysis**

Results, expressed as mean  $\pm$  SEM were analyzed by one-way Analysis of Variance (ANOVA) followed by Tukey's multiple pairwise comparison tests to assess the statistical significance. The data were considered at  $p < 0.01$ .

## **Results**

### **Wound contraction and epithelialization time**

Significant wound healing activity was observed in both the group of animals treated with ethanol and aqueous extract, respectively. The percentage of closure of wound was significant in the animals treated with ethanol extract (92.38 $\pm$ 1.01) on day 16<sup>th</sup> and (99.35 $\pm$ 0.15) on day 20<sup>th</sup>, respectively. While in control animals it was (88.51 $\pm$ 0.54) and (94.55 $\pm$ 0.33), respectively. Also, the group treated with aqueous extract showed significant value (97.15 $\pm$ 0.30) on 20<sup>th</sup> day in comparison with control group. The time required for complete epithelialization of the excision wound is an important parameter to assess the wound healing process. It was found that the mean time taken for complete epithelialization of the excision wound in ethanol extract

treated group was less than the animals treated with aqueous extract and the data are shown in Table 1.

Table 1: Effect of stem bark extracts of *B. monosperma* on excision wound model

Treatment	Percentage of closure of excision wound area					Epithelialization in days
	Day 4	Day 8	Day 12	Day 16	Day 20	
Control	20.37±0.54	62.31±0.53	79.18±0.61	88.51±0.54	94.55±0.33	24.33±0.61
Ethanol extract	30.70±1.24**	68.94±0.79**	84.23±0.56**	92.38±1.01**	99.35±0.15**	20.67±0.76
Aqueous extract	26.08±1.8*	66.98±0.82	81.72±0.26**	90.48±0.36	97.15±0.30**	21.61±0.21

Values are mean±S.E.; n = 6 in each group. \*P < 0.01 is compared to control.

**Collagen content from regenerated tissues of excision wound (mg/kg)**

The collagen content was estimated from regenerated tissue for control as well as treated groups. There was a significant increase in collagen content on 4<sup>th</sup>, 8<sup>th</sup>, 12<sup>th</sup>, 16<sup>th</sup> and 20<sup>th</sup> day in ethanol extract treated group compared to the aqueous extract treated and control group. The increase in collagen content in aqueous extract treated group was also significant except for the 20<sup>th</sup> day compared to the control group.

Statistical analysis of the results by ANOVA followed by student’s t test showed that there was a significant difference between all the groups (p<0.001) and the ethanol extract was found to be highly effective than aqueous extract (Table 2).

Table 2: Effect of stem bark extracts of *B. monosperma* on collagen content from regenerated tissues of excision wound (mg/kg)

Treatment	Day 4	Day 8	Day 12	Day 16	Day 20
Control	10.11±0.8213	17.79±0.9793	23.63±1.328	32.23±0.8739	40.97±0.7055
Ethanol extract	22.52±1.682**	31.90±0.9609**	39.76±0.6658**	45.59±0.9440**	51.58±0.6470**
Aqueous extract	15.93±0.6540*	22.46±0.8141*	30.91±0.6652*	33.68±0.3569*	42.71±0.7554

Values are mean±S.E.; n = 6 in each group. \*P < 0.01 is compared to control.



### Measurement of tensile strength

In incision wound model, significant increase in the tensile strength was observed in ethanol extract treated groups of animals followed by aqueous extract treated group of animals, indicating the effect of *B. monosperma* stem bark extract in maturation of collagen fibres (Table 3). The values were highly significant when compared to control group ( $p < 0.0001$ ).

Table 3: Wound healing effect of *B. monosperma* stem bark extracts on incision wound model

Treatment	Tensile strength (g)
Control	272.67±1.76
Ethanol extract	421±2.08**
Aqueous extract	326.33±2.03**

Values are mean±S.E.;  $n = 6$  in each group. \* $P < 0.01$  is compared to control.

### Hydroxyproline estimation and Granuloma weight

Treated group showed significant increased hydroxyproline level when compared to control group ( $P < 0.01$ ) in Table 4. Granuloma weight of treated animal groups was found to be increased when compared with control group.

Table 4: Effect of stem bark extracts of *B. monosperma* on dead space wound model

Treatment	Hydroxyproline content ( $\mu\text{g}$ )	Tensile strength (g)	Granuloma dry weight (mg/100g)
Control	6.2±0.1033	287.4±4.23	35.17±2.973
Ethanol extract	8.917±0.1352**	378.4±19.12*	47.48±2.082*
Aqueous extract	6.917±0.2330*	312.6±5.372*	45.28±1.896*

Values are mean±S.E.;  $n = 6$  in each group. \* $P < 0.01$  is compared to control.

### Histological Study

Granulation tissue sections obtained from control rats revealed more inflammatory cells and less collagen fibres and fibroblasts (Fig. 1). Histological sections of granulation tissue from

extract treated rats showed increased and well-organized bands of collagen, more fibroblasts and few inflammatory cells (Fig. 2 & 3).

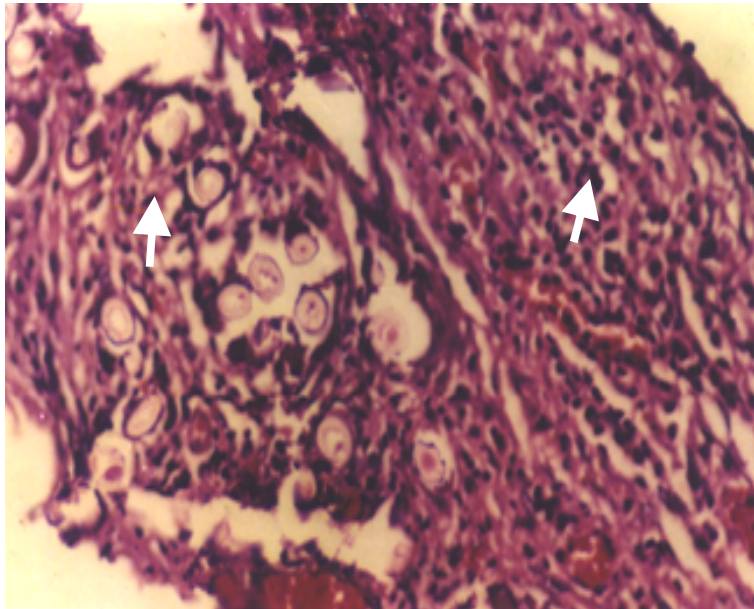


Figure 1. Histological section of the granuloma tissue of control animal showing incomplete healing with less epithelialization arrow showing macrophages and lesser collagen formation indicated incomplete healing of the wound

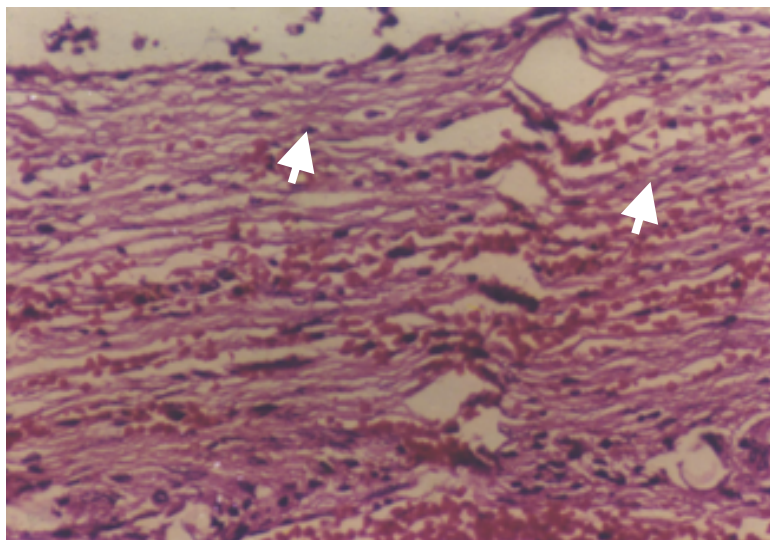


Figure 2. Histological section of the granuloma tissue of ethanol extract treated animal showing moderate epithelialization and increased collagenation deposition. Arrows showing the retention of macrophages with moderate epithelialization, fibrosis and arrow head showing collagen formation

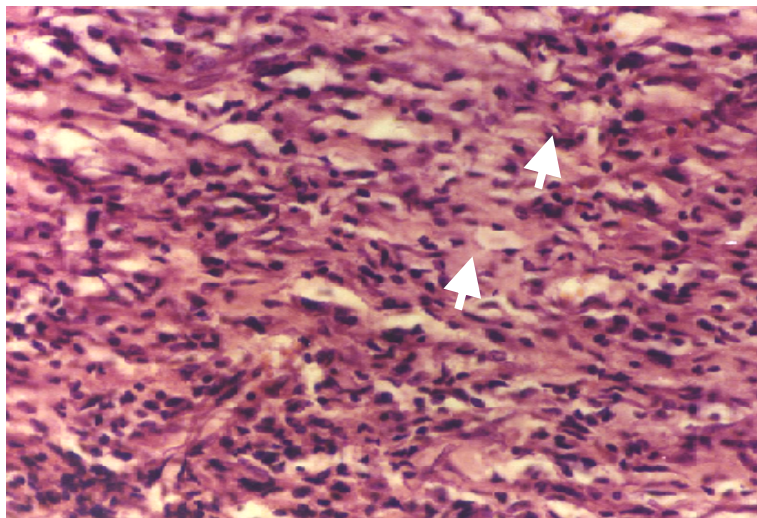


Figure 3. Histological section of the granuloma tissue of aqueous extract treated animal indicating epithelialization and collagenation. Arrowheads showing increase in collagen formation and complete healing with more of fibroblasts

### **Discussion**

Wound healing is a complex cellular event by which a damaged tissue restored as closely as possible to its normal stage. The healing process depends upon the reparative abilities of the tissue, the type and extent of damage and general state of health of the tissue. The process consists of different phases such as granulation, collagenation, collagen maturation and scar maturation which are concurrent but independent to each other. Hence in this study three different models were used to assess the effect of ethanol and aqueous extracts of *B. monosperma* on various phases. In excision wound model significant wound healing activity was observed in the animals treated with ethanol and the aqueous extracts of *B. monosperma*. Significant decrease in the period of epithelialization and increase in wound contraction rate were observed in these groups of animals. In both extract treated animals, epithelialization was completed on 20<sup>th</sup> and 21<sup>st</sup> post wounding day respectively. While in control animals, the rate of wound contraction was slow and the complete epithelialization of the excision wound was extended up to 24<sup>th</sup> post wound day.

The tensile strength depicts the strength of a healing wound and is measured experimentally by the amount of force required to disrupt it. The tensile strength increases rapidly as collagen deposition increases and cross linkages are formed between the collagen fibers, than in the beginning where a wound will be having little breaking strength because the clot will alone will be holding the edges together. In the present investigation, significant increase in the tensile strength was observed in the animals treated with the plant extracts on the 10<sup>th</sup> post wounding day. Similar observations have been reported by Shirwaikar *et al.* (2003) [15] and Singh *et al.* (2005) [16].

Granulation tissue formed in the final part of the proliferative phase is primarily composed of fibroblasts, collagen, edema and new small blood vessels. The increase in dry granulation tissue in the treated groups is an indication of higher protein content. The constituents present in the plant extracts may be responsible for promoting the collagen formation at the proliferative stage of wound healing. The ethanol as well as aqueous extracts of *B. monosperma* demonstrated a significant increase in the hydroxyproline content in the granulation tissue indicating increased collagen turnover. Collagen, which strengthens and supports the extra cellular tissue is composed of amino acid, hydroxyproline, which has been used as a biochemical marker for tissue collagen [17].

Wound healing is a complex and dynamic process of restoring the tissue integrity in damaged tissue as closely as possible to its normal state. It has four phases; inflammation, wound contraction, epithelialization and granulation tissue formation. Inflammation starts immediately after the disruption of tissue integrity. The platelets adhere to the clotting factors and form haemostatic plug to stop bleeding from the vessels. The prostaglandins (PGE1 and PGE2) are released in the inflammation area and seem to be the final mediators of acute inflammation and

may play a haemostatic role for white cells and fibroblasts. The active motile white cells migrate into the wound and start engulfing cellular debris, at the initial stages wound contraction begin slowly but became rapid after 3 or 4 days. The myofibroblasts present in the margin of the wound appear to constitute the machinery for the wound contraction. These are responsible for overlaying debris. The epithelialization of the wound mainly occurs by proliferation and migration of the marginal basal cells lying close to the wound margin. The hematoma within the wound may be replaced by granulation tissue, which consists of new capillaries and fibroblasts. The fibroblasts are responsible for production of the mucopolysaccharide ground substance. The lymphatics develop new nerve fibers and there is also formation of scar tissue in which collagen turn over increases. The increase in the formation of collagen fibers in the present study could be attributed to the effect of the ethanol and aqueous extracts of *B. monosperma*. At the later stage the tensile strength of the wound increases correspondingly to the increase of collagen content.

### **Conclusion**

The present study has demonstrated that the ethanol and aqueous extracts of *B. monosperma* stem bark has properties that render it capable of promoting accelerated wound healing activity. The potency of the plant in healing the wounds may be attributed to the phytoconstituents like flavonoids, tannins, saponins, glycosides, steroids, and triterpenoids present in it, which may be either due to their individual or additive effect, hastening the process of wound healing. The present investigation offers scientific evidence to the folkloric accounts of the use of leaf extract of *B. monosperma* in treating cuts and wounds. However, it needs further evaluation in clinical settings before consideration for the treatment of wounds. Also, studies with purified constituents are needed to understand the complete mechanism of wound healing activity of *B. monosperma*.

### **Acknowledgement**

The authors express their sincere thanks to Prof. V.A.. Kangralkar Maratha mandal Pharmacy college, Belgaum for their valuable guidance and support.

### **References**

- [1] WHO, 2002. WHO Traditional Medicine Strategy 2002–2005. WHO, Geneva.
- [2] Mantle D. Gok M.A. Lennard T.W.J. Adverse and beneficial effects of plant extracts on skin and skin disorders. *Adv Drug Reactions and Toxicol Rev* 2001; 20 (2): 89–103.
- [3] Ulubelen A. Topcu G. Tan N. et al. Biological activities of a Turkish medicinal plant, *Prangos platychnaena*. *J Ethnopharmacol* 1995; 45: 193–197.
- [4] Hemmati A.A. Mohammadian F. An investigation into the effects of mucilage of quince seeds on wound healing in rabbit. *J Herbs Spices Med Plants* 2000; 7: 41–46.
- [5] Choi S.W. Son B.W. Son Y.S. et al. The wound healing effect of a glycoprotein fraction isolated from *Aloe vera*. *British J Dermatol* 2001; 145: 535–545.
- [6] Bairy K.L. Wound healing potential of plant products. *J Nat Rem* 2002; 2: 11–20.
- [7] Shukla Y.N. Mishra M. *Ind. Drug* 2001; 38-49.
- [8] Jalalpure S.S. Patil M.B. Prakash N.S. Hemalatha K. Manvi F.V. Hepatoprotective activity of fruits of *Piper longum* L. *Ind J Pharm Sci* 2003; 65: 363-366.
- [9] Marton J.J.P. Malone M.H. Evaluation of vulnerary activity by an open wound procedure in rats, *Arch Int Pharmacodyn* 1972; 196: 117-126.
- [10] Ehrlich H.P. Hunt T.K. Effect of cortisone and anabolic steroids on the tensile strength of healing of wounds. *Ann Surg* 1969; 170: 130-206.
- [11] Patil M.B. Jalalpure S.S. Nagoor V.S. Wound healing activity of the roots of *Eclipta alba* Linn. *Ind Drugs* 2004; 41(1): 40-45.
- [12] Lee K.H. Tong T.G. Study on the mechanism of action of salicylates, retardation of wound healing by aspirin. *J Pharm Sci* 1968; 57: 1042.
- [13] Woessner J.F. The determination of hydroxyproline in tissue and protein samples containing small portion of this imino acid. *Arch Biochem Biophys* 1963; 193: 440–447.
- [14] Dispaquale G. Meli A. Effect of body weight changes on the formation of cotton pellet induced granuloma. *J pharm Pharmacol* 1965; 17: 379.
- [15] Shirwaikar A. Shenoy R. Udupa A.L. Udupa S.L. Shetty S. Wound healing activity of phenolic extract of leaves of *Hyptis suaveolens* with supportive role of antioxidant enzymes. *Ind J Exp Biol Med* 2003; 41: 238–241.
- [16] Singh S.D.J. Krishna V. Mankani K.L. et al. Wound healing activity of the leaf extracts and deoxyelephantopin isolated from *Elephantopus scaber* Linn. *Ind J Pharmacol* 2005; 4: 238–242.
- [17] Kumar R. Katoch S.S. Sharma S. b-Adrenoceptor agonist treatment reverses denervation atrophy with augmentation of collagen proliferation in denervated mice gastrocnemius muscle. *Ind J Exp Biol* 2006; 44(5): 371-376.