

Evaluation of Wound Healing Potential of Poly Herbal Formulation

Sanjay.Prahalad Umachigi*, Jayaveera K.N¹. Ashok kumar C.K²

*Bharat institute of Technology-Pharmacy, Ibrahimpatnam, Hyderabad, Andhra Pradesh, India

¹Department of Chemistry, Jawaharlal Nehru Technological University College of Engineering, Ananthpur, Andhra Pradesh, India

²Department of Pharmacognosy, Sree Vidyaneekeethan College of Pharmacy, A.Rangamepeta, Tirupathi, Chittoor Dist. Andhra Pradesh, India

Summary

Wounds are physical injuries that result in an opening or breaking of the skin. Proper healing of wounds is essential for the restoration of disrupted anatomical continuity and disturbed functional status of the skin. It is a product of the integrated response of several cell types to injury. Wound healing is a complex multifactorial process that results in the contraction and closure of the wound and restoration of a functional barrier. The medicinal Plants selected were galls of *Quercus infectoria*, whole plants of *Couroupita guianensis* and *Anthocephalus cadamba*. The selected Medicinal plants were reported to have Possess Wound healing, anti-inflammatory and antibacterial property. The emulsifying ointment and Carbopol-934 gel formulations containing extracts of the above mentioned herbs were formulated and their wound healing activity was studied in experimentally induced open wounds in albino rats. Excision and Incision wound models were studied. The Individual herbs were evaluated for their standard specification according to the Ayurvedic Pharmacopoeia of India. Extracts were obtained by established Procedures. HPTLC analysis for the Herbal extracts was carried out for identification of some known active constituents present in these herbs. Formulations containing 3%, 4% and 5% herbal extracts were prepared and applied topically three times a day to open wounds for 16 days Post-Operatively and compared with base control. The treated wounds showed a faster rate of Wound contraction compared with controls. This was further supported by Histopathological studies. The Wound contraction studies revealed that the wound contractions increase with an increase in the herbal extract concentration. The gel formulations produced better healing compared with the emulsifying ointment formulations. The data of the study indicated that gel based formulations produced better wound healing than emulsifying ointment formulations.

Key words: *Quercus infectoria*; *Couroupita guianensis*; *Anthocephalus cadamba*; Wound healing ; Poly herbal formulation

For Author Correspondence

Sanjay Prahalad Umachigi

Bharat institute of Technology-Pharmacy, Department of Pharmaceutics

R.R.Dist Ibrahimpatnam Hyderabad-510 501

E mail: umachigisanjay@gmail.com

Contact No. +91 9989493743

Introduction

Wounds are physical injuries that result in an opening or breaking of the skin. Proper healing of wounds is essential for the restoration of disrupted anatomical continuity and disturbed functional status of the skin. It is a product of the integrated response of several cell types to injury. Wound healing is a complex multifactorial process that results in the contraction and closure of the wound and restoration of a functional barrier [1]. Repair of injured tissues occurs as a sequence of events, which includes inflammation, proliferation and migration of different cell types [2]. Three different phases constitute the physiologic process of wound-healing; (i) substrate phase, (ii) proliferative phase and (iii) remodeling phase [3]. All these steps are orchestrated in controlled manner by a variety of cytokines including growth factors [4]. However "Mother Nature" has been kind to us by creating various herbs which assists in the healing process. This treatment provides fibrogenetic and concentration of collagen resulting in faster healing. The drugs selected for this work are *Quercus infectoria*, *Couroupita guianensis* and *Anthocephalus cadamba*. The growing popularity of natural and herbal medications, easy availability of raw materials, cost-effectiveness and paucity of reported adverse reaction, prompted us formulate a Polyherbal topical formulation and assess its wound healing ability. The combination is used in order to enhance the wound healing activity.

Materials and Methods

Anthocephalus cadamba and *Couroupita guianensis* were collected from Western Ghats of Karnataka, India in October 2005. The plants were identified and voucher specimens (RCP/PCOG/02/2005-06). The galls of *Q. infectoria* used in this study were obtained from the local market and were identified based on its physical characteristics. The marker compound Gallic acid was purchased from Anju Phyto Chemicals, Bangalore, India, and all other chemicals were analytical grade and used without further purification.

Monographic analysis of Herbs

The Individual herbs were evaluated with regard to their standard specifications according to the Ayurvedic Pharmacopeia of India. The tests carried out were foreign organic matter. Extractive value and Ash value.

Preparation of Herbal Extracts

Air-dried and powdered drug of *A. cadamba* were successively percolated with petroleum ether (6.8%, w/w), acetone (10.4%, w/w), chloroform (13.2%, w/w), ethanol (19.7%, w/w), water (21.4%, w/w) and whole plant was separately percolated with 50% hydro alcohol (20.2%, w/w) (ACE). The extracts were decanted, filtered with Whatman No. 1 filter paper and concentrated under reduced pressure below 40°C to obtain dry extract ACE.[1].

The shade-dried, powdered galls of *Q. infectoria* (1 kg) were extracted exhaustively using 95% ethanol on a Soxhlet apparatus. The total ethanol extract was concentrated in vacuo to a syrupy consistency (yield 270 g) [6]. The powdered material *Couroupita guianensis* (250 g) was macerated with petroleum ether to remove the fatty substances; the marc was further extracted with methanol and filtered. The extract was concentrated under reduced pressure and lyophilized (Labconco, U.S.A.) to get dry residue (23.6 g) [7].

Identification of active constituents in the herbal Extract

The selected plants were studied individually by HPTLC method HPTLC analysis for the herbal extracts was carried out to identify some known active constituents. In the HPTLC study the extracts showed the presence of selected marker compounds. Their R_f values were similar to standard R_f values. All the extracts were screened for the antimicrobial activity. We also reported the presence HPTLC Densitometry quantification method of gallic acid, which contributes to the antioxidant activity of the galls. [7]. Finger printing analysis of *Q. infectoria* and *Couroupita guianensis* were carried out. A HPTLC system equipped with a sample applicator device, a TLC plate development chamber, a TLC scanner and integration software (Camag) was used.

Preparation of topical formulations and incorporation of Extracts

Table 1: Two topical formulations Viz. emulsifying ointment and Carbopol 943 gel were prepared and their composition is given in

Emulsifying ointment base	Quantity(g)	Gel Base	Quantity (g)
Emulsifying Wax	300	Carbopol-934	3
White Soft Paraffin	500	Purified Water	100
Liquid paraffin	200	Triethanolamine	q.s to neutralize the gel base

Table 2: Preparation of Medicated formulations.

Ingredients	Emulsifying Ointment		
	F1a	F1b	F1c
<i>Anthocephalus cadamba</i> (%w/w)	3	4	5
<i>Quercus infectoria</i> (%w/w)	3	4	5
<i>Couroupita guianensis</i> (%w/w)	3	4	5
Emulsifying ointment base	q.s	q.s	q.s

Antimicrobial activity

The antimicrobial activity of each formulation was assessed by measuring the zone of inhibition in nutrient agar medium, employing *E.coli* and *Staphylococcus aureus* test organisms (8,9).

Wound healing studies

An excision wound model was used for studying wound healing activity. Albino rats (Wistar strain) of both sexes weighing between 150–200 g were randomly divided into 8 groups of six animals each. The back of the each animal was shaved and prepared after washing with spirit. An area of about 2 sq.cm was defined with a marker on the shaven back of the animals. The circular marked area was excised with its full thickness using a surgical sterile blade and scissors under phenobarbitone anesthesia. The formulations (emulsifying ointment) FIa, FIb, FIc and (gel base) FIIa, FIIb, FIIc were applied to the wounded rats of the respective groups, three times a day. The wounded rats of the first group were used as the baseline control for all the formulations. The application was repeated for 16 days post-operatively. The wound contractions were measured as the percentage of wound reduction in the wound area for every four days. The progressive reduction in the wound area was monitored periodically by tracing the wound margin on paper and the area was measured using graph paper. The reduction in the wound size was calculated by the formula: Wound contraction% = (difference in the area of the wound in mm² between the initial and on a particular post-operative day) × 100/area of the wound in mm² immediately after the wound excision.

Histopathological studies

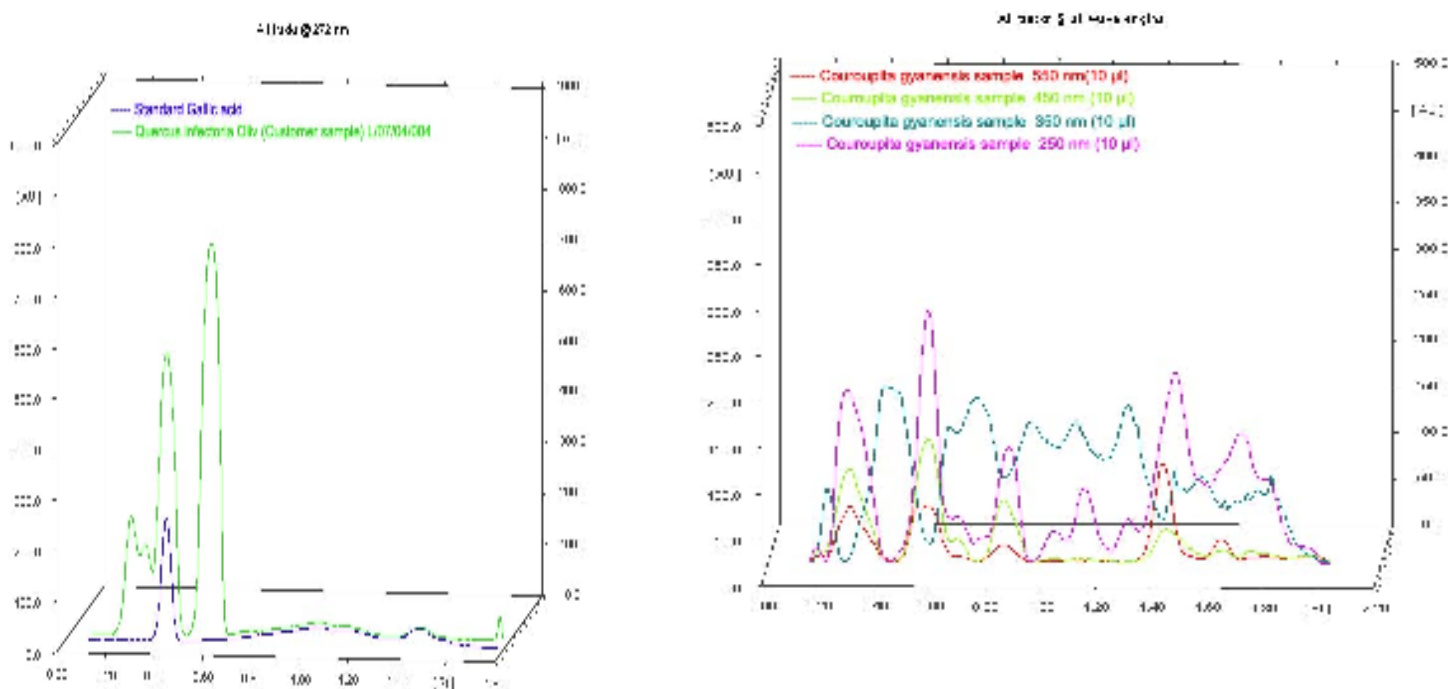
On 16th day, the regenerated tissue from the healing wounds was collected and placed in 10% buffered formalin for Histopathological studies. Sections from the regenerated tissue were examined for epithelialization, inflammation, collagen, and fibroblasts.

Results and Discussion

Identification of active constituents in the herbal extracts

HPTLC analysis of the herbal extracts was performed and the *R_f* values of the active constituents were found to be similar to the reported literature values Table 3. Fig. 1 shows a typical fingerprinting analysis of galls *Quercus infectoria* and *Couroupita guianensis*.

Fig 1: Fingerprinting analysis of galls *Quercus infectoria* and *Couroupita guianensis*



Anti- Microbial activity of the Formulations

The ointment base and gel base without the herbal extracts did not shown any zone of inhibition. The zone of inhibition was found to increase on increasing the herbal drug concentration. Hence the results of this study confirm that the herbs possess anti-bacterial activity and this will help keep the wound area sterile, thus promoting wound healing. This fact supports a faster wound healing in the treated groups compared with the control group (Table 3)

Table 3: Zone of Inhibition of the formulations

Formulation	<i>E-Coli</i> (mm*)	<i>S.aureus</i> (mm*)
FIa	8	4
FIIa	9	6
FIb	12	10
FIIb	14	13
FIc	24	18
FIIc	26	22

*Radius of ZoI. ZoI–Zone of inhibition.

Wound contraction studies

The results of wound contraction studies indicate that all the formulations enhance wound healing in open wounds. The rate of wound contraction was found to reach a maximum on the 12th day in the treated groups. The gel formulations produced better wound contraction compared with the ointment formulations. The formulations F1c and F11c produced greater wound contraction compared with the other formulations (Table 4).

Table 4: Excision wound studies showing percentage reduction in wound size, when treated with formulations and base control ($n = 6$, mean \pm SD).

Days	Emulsifying ointment formulation				Gel Formulation			
	Control	F1a	F1b	F1c	Control	F11a	F11b	F11c
4	13.12 \pm 3.50	17.11 \pm 3.68	21.56 \pm 3.05	26.28 \pm 3.82	14.00 \pm 1.24	20.91 \pm 3.62	23.56 \pm 3.69	27.25 \pm 3.69
8	41.20 \pm 4.2	47.12 \pm 4.36	65.26 \pm 3.00	81.28 \pm 3.40	43.0 \pm 1.22	48.26 \pm 4.26	67.24 \pm 3.69	83.28 \pm 3.61
12	63.24 \pm 5.98	66.72 \pm 2.56	77.56 \pm 2.98	93.27 \pm 3.82	64.21 \pm 5.26	67.28 \pm 2.12	79.23 \pm 3.63	95.25 \pm 2.69
16	79.68 \pm 3.97	88.48 \pm 2.48	93.50 \pm 2.56	97.02 \pm 1.09	81.26 \pm 3.68	91.39 \pm 2.25	97.26 \pm 3.05	99.28 \pm 2.51

Histopathological studies

Microscopic examination of the sections prepared from the wounds of normal, control and treated groups exhibited the following characteristics.

Normal: The tissue is composed of dense collagen fibers, fibroblasts with round to oval nuclei and blood vessels.

Control: The tissue showed densely inflamed connective tissue with chronic inflammatory cells between the collagen fibers; this shows incomplete wound healing. Many thin walled blood vessels are present.

Treated groups: Tissues showed fibrous connective tissue with scattered inflammatory cells and fibroblasts. There was a progressive collagenation with few thin walled blood vessels with small lumina. Epithelialization of tissues was observed. Parameters like fibroblasts, collagen, and neo-vascularization were higher in the treated group compared with the control. These results show that the wound healing was faster in the treated group compared with the control group. Formulations F1c and F11c, containing higher concentrations of the extracts showed dense Fibrous tissue with thick collagen bundles, fibroblasts and scattered inflammatory cells. The appearance was almost identical to that of normal tissues.

A comparison of Histopathological studies of regenerated tissue sections of normal, control and wounds treated with the ointment-based formulation F1c and gel based formulation F11c are shown in Fig. 2.

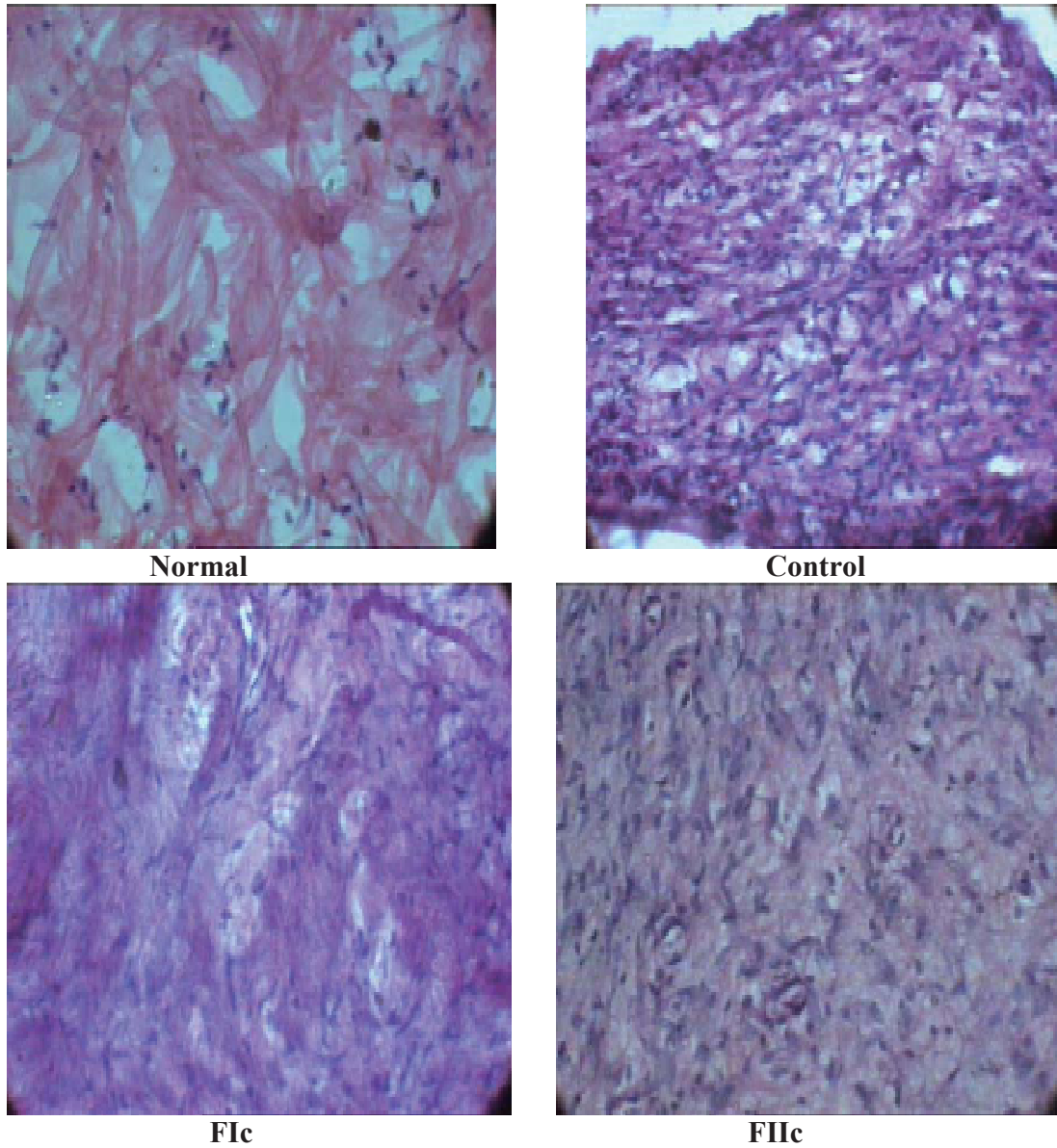


Fig. 2: Histology of regenerated tissue of open wounds in normal, control and treated group as on the 16th day at 400 ×.

Conclusion

HPTLC studies of the extracts showed the presence of selected marker compounds. Their *R_f* values were similar to standard *R_f* values. The microbiological studies indicated that these formulations possess anti-microbial activity. The wound contraction studies revealed that the wound contraction increases on increasing the herbal extract concentration. The gel formulations showed better healing properties compared with the emulsifying ointment formulations. The Histopathological studies showed that certain parameters, namely collagen, fibroblasts and neovascularization, were slightly higher in the treated groups compared with the control groups of animals, indicating faster remodeling of wounds. Therefore, from the above observations, it can be concluded that these topical formulations containing herbal extract possess good wound healing activity.

References

1. Sanjay.Prahalad Umachigi, Kumar, G S, Jayaveera KN, Kishore kumar DV, Ashok kumar CK, Dhanapal.R: Antimicrobial, Wound Healing And Antioxidant Activities of *Anthocephalus Cadamba Afr. J. Trad. CAM* 2007, 4 (4): 481 – 487.
2. Sidhu, GS, Mani H, Gaddipatti JP, Singh AK., Seth P, Banaudha KK, Patnaik GK. Maheshwari RK: Curcumin enhances wound healing in streptozotocin induced diabetic rats and genetically diabetic mice. *Wound Repair Regeneration*. 1999, 7: 362–374.
3. Sanjay.Prahalad Umachigi, Jayaveera KN, Ashok kumar CK, Kumar GS: Antimicrobial, Wound Healing and Antioxidant potential of *Couroupita guianensis* in rats. *Pharmacologyonline* 2007, 3:269-281
4. Pierce GF, Berg JV, Rudolph R: Platelet derived growth factor-BB and transforming growth factor B₁ selectively modulate glycosamineglycans, collagen and myofibroblasts in excisional wounds. *Am J Pathol*. 1991, 138:629-46.
5. Samuelsson G. Drugs of Natural Origin. 4th Ed. Sweden: Swedish Pharmaceutical Press; Stockholm, 1992. p. 86.
6. Umachigi SP, Jayaveera KN, Ashok Kumar CK, Kumar, GS, Vrushabendra swamy BM, Kishore Kumar DV: Studies on Wound Healing Properties of *Quercus infectoria*. *Tropical Journal of Pharmaceutical Research*, 2008; 7 (1): 913-919.
7. Sanjay.Prahalad Umachigi, Jayaveera KN, Ashok kumar CK, Kumar GS: Antioxidant Potential of galls of *Quercus infectoria*. *The Internet Journal of Pharmacology* 2008, Vol 5, No 2.
8. M. A. Iyengar, M. Pattabhi, R. Rao, Anti-microbial activity of the essential oils of *Curcuma longa* leaves. *Indian Drugs*, 1995, 32 (6): 249-250.
9. R. Chandic, S. K. Dash, R. K. Mishra, Anti E. coli activity of Turmeric essential oil. *Indian Drugs*, 2001, 38 (3): 106-111.