

PROPHYLACTIC ACTIVITY OF EXTRACT OF *TARAXACUM OFFICINALE* WEBER. AGAINST HEPATOCELLULAR INJURY INDUCED IN MICE

Tabassum N^{1*}, Shah M.Y¹, Qazi M.A², Shah A³

¹ Deptt. of Pharmaceutical Sciences, University of Kashmir, Srinagar J&K, India.

² Deptt. of Pharmacology, G.M.C, Srinagar, J&K, India .

³ Deptt. of Pathology, SKIMS, Soura, Srinagar, India.

Summary

In the traditional system of medicine, large numbers of herbs have been used in the treatment of liver diseases. Different models are used for inducing hepatocellular injury in experimental animals. Paracetamol, commonly used as an antipyretic and analgesic, is safe at therapeutic doses but larger doses lead to massive hepatic damage. *Taraxacum officinale*, widely available in Kashmir, has been reported to be useful in liver disorders. Root has been indicated in eczema, skin disease, scurvy, acne, jaundice, spleen, gall bladder and mental fatigue, etc. In this study ethanolic extract of *Taraxacum officinale* was administered prophylactically in mice at three dose levels 50, 100 & 200 mg/kg/day, before administration of paracetamol.

Results suggested a dose dependent fall in serum ALT levels with *Taraxacum officinale* extract. Histopathology of liver sections also revealed marked regeneration of hepatocytes in the extract treated animals. It can be concluded that *Taraxacum officinale* ethanolic extract possesses significant hepatoprotective activity and prevents chemically (paracetamol) induced hepatocellular damage when given prophylactically in mice.

Key words: Paracetamol, Hepatocellular injury, *Taraxacum officinale*, Prophylactic activity.

***Corresponding author: Dr. Nahida Tabassum,**

Deptt. of Pharmaceutical Sciences, University of Kashmir, Hazratbal, Kashmir, J&K, India-190006. Ph. No: 09419906868 E-mail: n.tabassum.uk@gmail.com

Introduction

Liver diseases constitute a major health problem in the developing countries. In the absence of reliable hepatoprotective drugs, herbal medicines are significant source of pharmaceutical drugs. Numerous herbs and herbal formulations are used in the traditional system of medicine for treatment of hepatocellular damage. However, only selected medicinal herbs have been tested for hepatoprotective activity.

Taraxacum officinale (Fam: Compositae) commonly known as Dandelion (**Hand** in Kashmir) grows almost everywhere in the world, preferring moist conditions. The plant is cultivated widely in India for its rhizome and roots, which are commonly employed in medicine with increasing demand.

It has a long history of being in traditional use in the treatment of hepatobiliary problems. Root and leaf preparations are used as choleric, diuretic & tonic components (1) (2); as a bitter tonic in atonic dyspepsia (3) and as a mild laxative in habitual constipation (4)(5). It has also been found to retain a potential antitumour activity (6) and has potential hypolipidaemic and antioxidant activity (7). Tea made by boiling flowers is used to treat heart trouble and cooked young leaves are eaten to purify blood (8).

Root has been reported to contain sesquiterpene lactones; triterpenes; carbohydrates; carotenoids (lutein); fatty acids (myristic); flavanoids (apigenin and luteolin); minerals, etc.(9,10). Taraxalisin (11); coumarins, cichoriin and aesculin reported from leaf (12)(13). Five germacrane and guaian-type sesquiterpene lactones including taraxinic acid derivatives were isolated from the roots (14).

In the present study extract of *Taraxacum officinale* was studied for its prophylactic activity against hepatocellular damage induced in experimental animals.

Materials and Methods

Plant Material

Whole plant of *Taraxacum officinale* was collected in the month of May from Kashmir University campus, Srinagar. It was properly identified and authenticated by a plant taxonomist, Department of Botany, University of Kashmir, Srinagar, India. The voucher specimen was deposited at the Department of Taxonomy, Kashmir University, J& K India.

Plant material and extracts

The whole plant of *Taraxacum officinale* was freed from extraneous matter, dried in a well-ventilated room, the outside temperature being in the range of 18-32 degrees celsius. It was then coarsely powdered and 50% ethanolic extract was prepared as described in I.P, 1985(15). The combined filtrate obtained was distilled under vacuum, the temperature of distillation being in the range of 42-48 degree celsius and distillate evaporated to dryness in air to obtain a solid mass.

Animals

Albino mice of Wistar strain, weighing between 16-23g, were obtained from Central Animal House RRL Jammu after proper approval. They were housed under uniform animal husbandry conditions in polypropylene cages, fed with proper diet and water ad-libitum. They were exposed to 12h. light-dark cycle, 18-32 degrees celsius temperature and the relative humidity was in the range of 61-76%. All procedures were performed after the experimental protocol was approved by institutional animal ethical committee (IAEC) as per the guidance of the committee for the purpose of Control and Supervision of Experiments on Animals (CPCSEA) at the Department of Pharmaceutical Sciences, University of Kashmir.

Paracetamol-induced hepatocellular damage in mice

Mice were divided into five groups of six animals each. First group served as vehicle control, Group III, IV & V received 50% ethanolic extract of *Taraxacum officinale* whole plant at the dose of 50 mg, 100 mg and 200mg /kg /day respectively, daily for five days in single oral dose. After five days i.e on day 6th, Groups II, III, IV and V were administered the hepatotoxic agent, paracetamol solution (500 mg/kg body weight) in a single oral dose (16). The mice of Group I received only 1% gum acacia suspension in distilled water daily for six days.

Mice were weighed on every alternate day during the study. On day 7th, blood was withdrawn from the retino-bulbar venous plexus of all the Groups I- V. Serum was separated and estimated for ALT levels (17).

Histopathological study

The mice were sacrificed and after dissection livers were taken out from mice. After weighing, they were preserved in 10% formalin. Sections were embedded in paraffin and slides were prepared using haematoxylin-eosin stain. The prepared slides were used for histopathological examination.

Statistical Analysis

Values are expressed as mean \pm SE from the number of replications described in the test. Total variation present in a set of data has been estimated by ANOVA. The t-value was also calculated for two-sided test. $p < 0.05^*$ considered significant and $p < 0.01^{**}$ as highly significant.

Results

The yield of *Taraxacum officinale* whole plant was 14.30 %w/w. A highly significant rise ($***p < 0.001$) in ALT levels was observed in mice of Group II, which received single dose of paracetamol as compared to mice of Group I (Table, Fig A).

Taraxacum officinale extract when administered prophylactically for 5 days at the dose of 50 mg/kg/day produced a fall ($*p > 0.05$) in ALT levels of Group III where as highly significant fall ($**p < 0.01$ and $***p < 0.001$) in IV and V Group, respectively, was observed at the doses of 100 and 200 mg/kg/day when compared with ALT levels of mice of Group II that had received only hepatotoxin (Fig A).

Table

Effect of ethanolic extract of *Taraxacum officinale* when given prophylactically, on ALT levels, against paracetamol induced acute hepatocellular damage in mice.

Group	Treatment	Serum ALT levels (IU/L)	Statistically Compared Groups
I	Control (1% gum acacia)	44.78±2.50 (n=6)	II Vs I
II	Only Paracetamol (500mg/kg, orally, in single dose)	117.40±12.16*** (n=5)	II Vs I
III	<i>Taraxacum officinale</i> (50mg/100g/day) + Paracetamol	96.21±8.43* (n=5)	III Vs II
IV	<i>Taraxacum officinale</i> (100mg/100g/day) + Paracetamol	75.05±2.56** (n=5)	IV Vs II
V	<i>Taraxacum officinale</i> (200mg/100g/day) + Paracetamol	62.86±5.17*** (n=6)	V Vs II

* $p > 0.05$, ** $p < 0.05$, *** $p < 0.001$.

Data shown are mean \pm S.E.M; Number of animals in each group is given in parenthesis. Statistical significance calculated by ANOVA, using student 't' test. All comparisons made with Group I & II.

Fig A: Effect of 50% Ethanolic Extract of *Taraxacum officinale* on ALT levels, when given prophylactically against paracetamol induced liver damage.

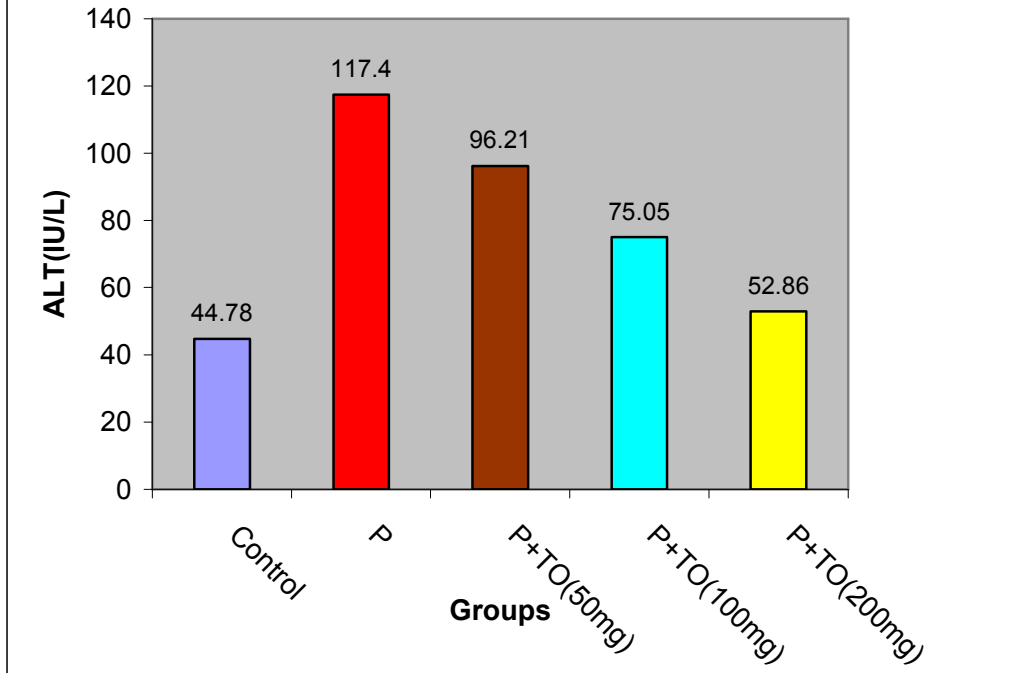
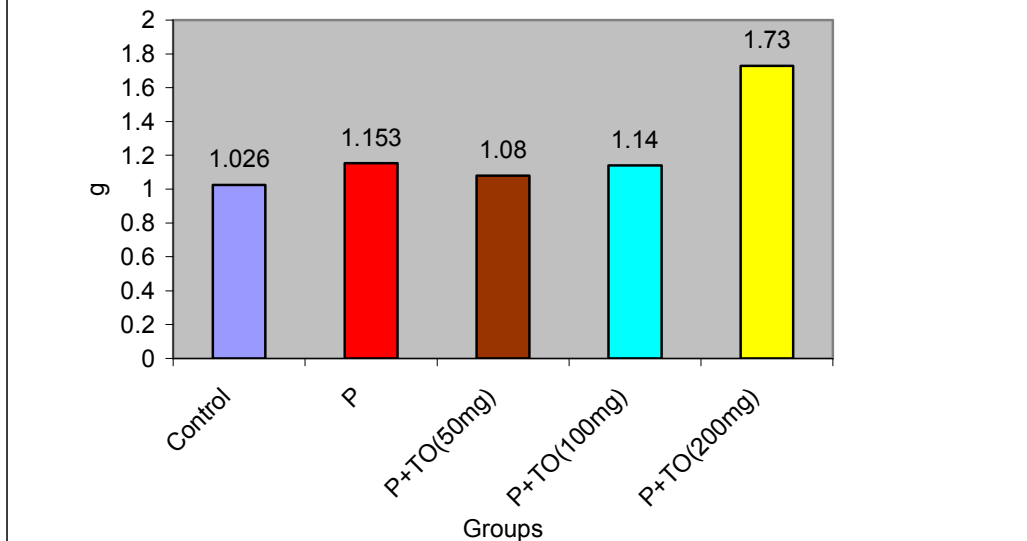


Fig B: Effect of 50% Ethanolic Extract of *Taraxacum officinale* on average liver weight of mice, when given prophylactically for five days, against paracetamol induced liver damage.



No significant difference in average liver weight of mice in different Groups that had received Paracetamol and different doses of *Taraxacum officinale* was observed. However, *Taraxacum officinale* when administered at the dose of 200 mg/kg/day produced a significant increase in average liver weight (* $p < 0.05$) of mice when compared with other groups (Fig B).

On histopathological examination, livers of mice of control group were found to be normal (Fig 1). Centrilobular necrosis was observed in most of the livers of Group II that had received toxic agent only (Fig 2). Extract of *Taraxacum officinale* at the dose of 50 mg/kg/day revealed fatty changes, inflammation and ballooning degeneration in the animals while 33% livers were found to be normal (Fig 3). Regenerative activity and anisonucleosis was observed in 47% at the dose of 100 mg/kg/day (Fig 4). When *Taraxacum officinale* extract was administered at the dose of 200 mg/kg/day revealed 75% livers as normal (Fig 5).

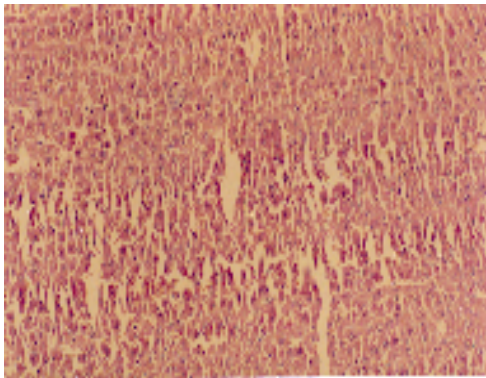


Fig 1: Control (1% gum acacia)
Normal liver architecture
(H&E X 100).

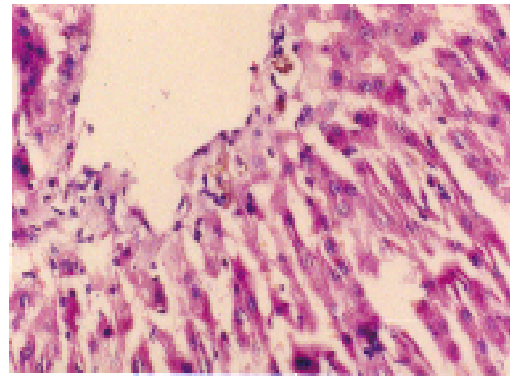


Fig 2: Paracetamol, single oral dose (500 mg/kg body weight). Centrilobular necrosis with bile pigments within the hepatocytes and sinusoids. (H&E X 400).

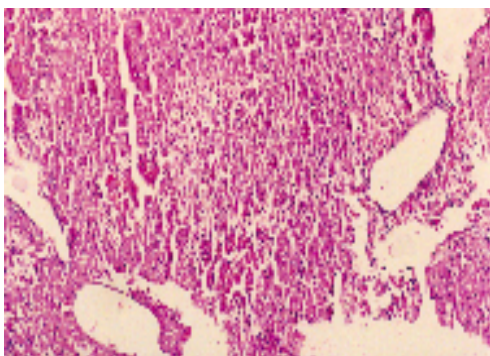


Fig 3: Group III *Taraxacum officinale* (50mg/kg/day) for 5 days prophylactically + Paracetamol single dose (500mg/kg b.w). Ballooning degeneration. (H&E X 100).

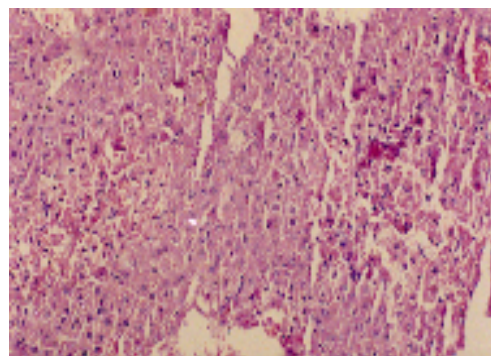


Fig 4: Group IV *Taraxacum officinale* (100mg/kg/day) for 5 days prophylactically + Paracetamol single dose (500mg/kg b.w). Focal necrosis, ballooning, anisonucleosis. (H&E X 200).

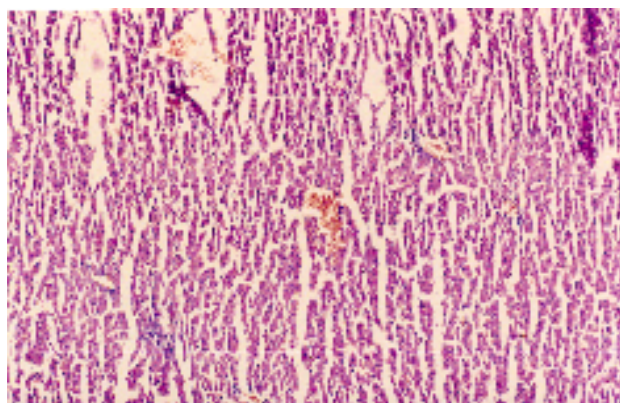


Fig 5: *Taraxacum officinale* (200mg/kg/day) for 5 days prophylactically +Paracetamol single dose (500mg/kg b.w). Congestion with normal hepatocytes (H&E X 100).

Discussion

Liver diseases appear to be on increase in our society. Herbal drugs have gained importance in recent years because of their efficacy and cost effectiveness (18). Numerous plant and polyherbal formulations are claimed to have hepatoprotective activities. However, only a small portion of such plants stand pharmacologically evaluated for their efficacy.

Paracetamol is a widely used antipyretic and analgesic that seems safe when taken in therapeutic doses but larger amounts may cause fatal hepatic necrosis (19). Present study was conducted to find the prophylactic activity of 50% ethanolic extract of *Taraxacum officinale* against paracetamol induced hepatotoxicity. Results suggested a dose dependent fall in the ALT levels of the mice that had received *Taraxacum officinale*, the fall being highly significant (** $p < 0.01$) at the dose of 100 and 200mg/kg/day. Histopathological studies supported the biochemical results (Fig 3, 4, 5) which revealed reduced hepatic necrosis at doses of 50,100 and 200 mg/kg body weight and almost normal hepatic architecture at the dose of 200 mg of the extract in comparison to the livers of mice that had received only hepatotoxin. Both the biochemical and histopathological studies point towards a protective role of 50% ethanolic extract of *Taraxacum officinale* in this prophylactic study against paracetamol induced hepatotoxicity with maximum protection being afforded at the dose of 200 mg/kg/day. These results are in corroboration with our previous study (20) in which *Taraxacum officinale* had shown curative activity when given after the administration of the hepatotoxic agent.

Conclusion

In conclusion it can be said that 50% ethanolic extract of *Taraxacum officinale* possesses both curative and prophylactic activity against paracetamol induced hepatocellular injury. Since the extract contains flavanoids, they may be the constituents responsible for the antihepatotoxic activity. The use of *Taraxacum officinale* in the traditional system of medicine and by Unani practitioners is also justified by this study.

References:

1. Leung, A.Y and Foster S. Encyclopaedia of Common Natural Ingredients Used in Food, Drugs and Cosmetics 2nd ed. New york NY: John Wiley and sons, Inc; 1996; 205-206.
2. Newall, C., Anderson LA, Phillipson CJD.: Herbal Medicines: A Guide for Health- Care Professionals. London: The Pharmaceutical Press. 1996; 96.
3. Kaul M.K.: Medicinal plants of Kashmir and Ladakh, Temperate and Cold Arid Himalaya. Indus Publishing Co., New Delhi. 1997;173.
4. Bradley, P.R(ed). British Herbal Compendium, Volume 1, Bournemouth: British Herbal Medicine Association, 1992;73-75.
5. Murray, M.T:The Healing Power of Herbs: The Enlightened Person's Guide to the Wonders of Medicinal plants. 2nd ed. Rocklin, calif,prima publishing,1995.
6. Oh. I.K; Yoo, EA Development of anticancer agents from Korean Medicinal Plants (Part 8). Cytotoxic activity of Taraxaci herba extract against human skin melanoma cells. Korean J. Pharmacognosy, 1998; 29(3): 198-203.
7. Ung-K Cho, Ok H Lee, Hypolipidaemic and antioxidant effects of Dandelion (*Taraxacum officinale*) Root and leaf on Cholesterol fed rabbits. Int. J. Mol. Sci , 2010; 11(1),67-78.
8. Bhattacharya, S.K.: In: Handbook of Medicinal Plants. Third revised edition. 2001; Pp 340.
9. Budaveri S (ed). The Merck Index; An Encyclopedia of Chemicals, Drugs and Biologicals, 12th ed. White house Station N.J: Merck 7 Co, Inc. 1996.
10. Wichtl and Bisset: Herbal Drugs and Phytopharmaceuticals. Stuttgart: Medpharm Scientific Publishers (eds) 1994.

11. Rudenskaya G.N, Bogacheva AM, Preusser, kuznetsova Av, Dunaevsky Ya E, Golovki BN,: Taraxalin-a serine proteinase frm dandelion *Taraxacum officinale* webb.si.FEBS Lett. 1998; 437(3):237-240.
12. Williams C.A, Goldstone F, Greenham J: flavanoids, Cinnamic acid and Coumarins frm the different tissues and medicinal preparations of *Taraxacum officinale* 1996; 42(1): 121-7.
13. Budzianwski, J: Coumarins,caffeyltartaric acid and artifactual methyl esters from *Taraxacum officinale* leaves. *Planta Medica*, 1997; 63(3):288-289.
14. Kisiel W, Barszcz B Further sesquiterpenoids and phenolics from *Taraxacum officinale*. *Fitoterapia* , 2000; 71 (3): 269-273.
15. Pharmacopoeia of India. CSIR Publication. 3rd edition. Delhi. Part II. 1985; A-74, 75.
16. Pandey, G and Shrivastava, D.N.: Effects of Livol and some of its ingredients on Paracetamol induced hepatotoxicity in mice. *Ind. J. Pharmacol*, 1990; 22,1:12.
17. Reitman S and Frankel, S.: A colorimetric method for the determination of serum glutamic oxaloacetic and glutamic Pyruvic transaminases. *Am. J. Clin.Path*, 1957; 28:56.
18. Subramonium A, Pushphagandan P: Development of phytomedicines for liver diseases. *Ind. J.Pharmacol*. 1999; 31:166-175.
19. Prescott L.F., Wright N., Roscoe P and Brown S.S. Plasma paracetamol half and hepatic necrosis in patients with paracetamol overdose. *Lancet* 1971;1: 519-22.
20. Tabassum Nahid, Shah M.Y, Qazi M.A, Shah A, M.Mudasir. Protective Role of Dandelion Against Acute Liver Damage Induced In Albino Rats. *Journal of Natural Products*, 2008; 4 (2).