

PROTECTIVE EFFECT OF *OCIMUM GRATISSIMUM* AGAINST CARBON TETRACHLORIDE INDUCED HEPATIC DAMAGE IN RATS.

VILAS SURANA^{1*}, DILPESH JAIN²

1. Maliba Pharmacy College, Bardoli-394 350, India.

2. Sinhgad College of Pharmacy, Pune-411 041, India.

*Corresponding author: suranavilas@yahoo.com

SUMMARY

The aim of this investigation was to evaluate the efficacy of *Ocimum gratissimum* ethanolic extracts (OGEE) of leaves on the experimental hepatotoxicity induced by carbon tetrachloride (CCl₄). Carbon tetrachloride (2 ml/kg, *i.p.*) was administered for 10 days and simultaneously suspension of OGEE prepared in 2 % gum acacia were daily administered at a dose level of (100 and 200 mg/kg/, *p.o.*) for 14 days. Silymarin was used as a standard drug and administered at a dose level of (100 mg/kg/, *p.o.*). Administration of carbon tetrachloride showed significant increase in the levels of serum aminotransferase, alkaline phosphatase and bilirubin, and decrease in total proteins levels, however necrosis, collagen deposition and altered hepatic architecture were also observed. Markers of liver injury, increased aminotransferase, alkaline phosphatase, bilirubin and morphological changes such as necrosis and collagen deposition, were significantly decreased whereas significant increase in serum total proteins was observed in the rats treated with OGEE. These results suggest that the OGEE showed hepatoprotective effect on carbon tetrachloride induced hepatic damage and may be a potential clinical application for treatment of liver diseases.

Keywords: *Ocimum gratissimum*, hepatoprotective, AST, ALT, carbon tetrachloride

Introduction

Liver has an important place in toxicology by virtue of its function, both qualitatively and quantitatively. It plays a major role in detoxification and excretion of many endogenous and exogenous compounds, any injury to it or impairment of its functions may lead to many implications on one's health. Management of liver diseases is still a challenge to the modern medicine (1). The modern medicines have little to offer for alleviation of hepatic ailments, whereas most important representatives are of phytoconstituents (2).

Ocimum gratissimum Linn (Lamiaceae) is a shrub, distributed in tropical and subtropical Himalaya from Kashmir eastwards to all over in India. Commonly it's found in gardens, waste places, and road sides. In different language the plant is known as Vriddhitulsi (Sanskrit), Ramtulsi (Hindi) and Nimmatulsi (Kannada) (3). As per the traditional claim *Ocimum gratissimum* leaves are potential source of drugs used in skin disease, inflammation, insomnia, carminative, aphrodisiac, digestive, tonic, antiemetic, antispasmodic, antineuralgic and liver diseases (4, 5). Phytochemically the extract of leaves contain essential oil such as eugenol and cineole, ocimol, tetratriacontane, gratimissin, gratimissic acid and β -caryophyllene (6). It has been reported that plant contains essential oil which is scientifically evaluated for wound healing (7), antibacterial (8), anthelmintic (9) and anti-malarial (10).

Methods

Collection of plant material and preparation of extracts

The leaves of *Ocimum gratissimum* were collected from the local area of Belgaum in the month of April and were authenticated by Botanical Survey of India, Pune (BSI/WC/Tech/2007/917). Shade dried leaves were coarsely powered and extracted with 90 % ethanol by continuous hot extraction method. The extract was concentrated in vacuum under reduced pressure using rotary evaporator. Suspension of extract was prepared by using 2 % gum acacia.

Preliminary phytochemical screening (11)

The extract was screened for preliminary phytochemical tests for the presence of glycosides, sterols, flavonoids, volatile oils, tannins and phenolic compounds.

Animals

Wistar albino rats (150-200 g) of either sex were used. The animals were maintained under standard laboratory conditions at temperature $23 \pm 2^{\circ}\text{C}$ with relative humidity $55 \pm 10\%$ and 12 h light and dark cycle throughout all the experiments. Animals had free access to food and water *ad libitum*. All the experimental procedures and protocols used in this study were reviewed and approved (BGM/IAEC/221) by the Institutional Animal Ethics Committee.

Experimental Design (12)

The rats were divided into five groups (n=6). Group I served as control and were received 2% gum acacia (1ml/kg, *p.o.*) for 14 days. Groups II-V was received mixture of CCl₄ + olive oil (1:1) intraperitoneally at a dose level of (2 ml/kg) for 10 successive days. Group III received standard drug silymarin (100 mg/kg, *p.o.*) for 14 days, whereas Group IV and V were treated with *Ocimum gratissimum* ethanolic extract at a dose level of (100 and 200 mg/kg/day, *p.o.*) for 14 days.

Assessment of liver function

All the rats were sacrificed on 14th day, 30 min after the administration of last dose under light ether anesthesia. The blood sample was collected by retro orbital method and allowed to coagulate for 30 min. Serum was separated at 4000 rpm for 10 min and biochemical investigations were carried out to assess liver function *viz.*, serum aminotransferase (13) , alkaline phosphatase (14), bilirubin (15), and total proteins (16) using commercial diagnostic kits (Biolab, India). Portion of the liver tissue was fixed in 10% buffered formalin, processed and stained with haematoxylin-eosin, and examined microscopically at 400X for histological assessment (17).

Statistical analysis

Results were expressed as mean ± SEM. The data obtained were analyzed by one- way ANOVA followed by Tukey test. The level of significance was set at p<0.05.

Results

Preliminary phytochemical screening

The ethanolic extract of *Ocimum gratissimum* subjected for preliminary phytochemical study showed the presence of flavonoids, glycosides, tannins and essential oils.

Assessment of liver function

Administration of CCl₄ for 10 days resulted in a significant increase in serum AST, ALT, ALP and bilirubin, whereas, significant decrease in total proteins levels. The treatment with OGEE at a dose level of (100 and 200 mg/kg/, *p.o.*) exhibited an ability to counter act the CCl₄ induced hepatotoxicity by decreasing the AST, ALT, ALP and bilirubin levels and increase in total proteins levels as compared to CCl₄ treated rats similar to that of the standard drug silymarin (Table 1). Histopathology of liver of the control rats showed prominent central vein and normal arrangement of hepatic cell (Fig. 6A). CCl₄ treated rats showed various degrees of pathological changes starting from centrilobular necrosis of hepatic cells to central lobular fatty degeneration (Fig. 6B). The sections of liver taken from the rats treated with standard drug Silymarin showed the hepatic architecture, which was similar to that of control (Fig. 6C). Liver section of rats treated with OGEE (100 and 200 mg/kg/, *p.o.*) showed significant protection against CCl₄ induce liver damage (Fig. 6D and 6E, respectively).

Table 1: Effect of *Ocimum gratissimum* ethanolic extract on CCl₄ induced hepatic damage in rats

GROUP	AST (U/l)	ALT (U/l)	ALP (U/l)	Bilirubin (mg/dl)	Total protein (g/dl)
Normal control	157.75± 1.38	75.75 ± 1.85	194.5 ± 1.56	0.52 ± 0.03	8.75± 0.21
CCl ₄ control	259.69 ± 1.78 ^{###}	174.8 ± 3.924 ^{###}	424.5 ± 3.6 ^{###}	1.85 ± 0.12 ^{###}	5.42 ± 0.17 ^{###}
Silymarin (100)	165.5 ± 2.10 ^{**}	82.75 ± 1.89 ^{**}	205.7 ± 2.06 ^{**}	0.62 ± 0.04 ^{**}	7.88 ± 0.23 ^{**}
OGEE (100)	199.8 ± 2.89 ^{**}	116.8 ± 3.32 ^{**}	278.3 ± 3.09 [*]	0.93 ± 0.06 ^{**}	6.49 ± 0.45 [*]
OGEE (200)	178.8 ± 2.22 ^{**}	91.9 ± 2.31 ^{**}	213.5 ± 2.10 ^{**}	0.67 ± 0.02 ^{**}	7.56 ± 0.26 ^{**}

Values are expressed mean ± SEM, (N= 6)

^{###}P < 0.0001, ^{##}P < 0.001 compared to control group (ANOVA followed by Tukey test)

^{**}P < 0.001, ^{*}P < 0.01 compared to CCl₄ control group (ANOVA followed by Tukey test)

Fig. 1: Effect of *Ocimum gratissimum* ethanolic extract on AST

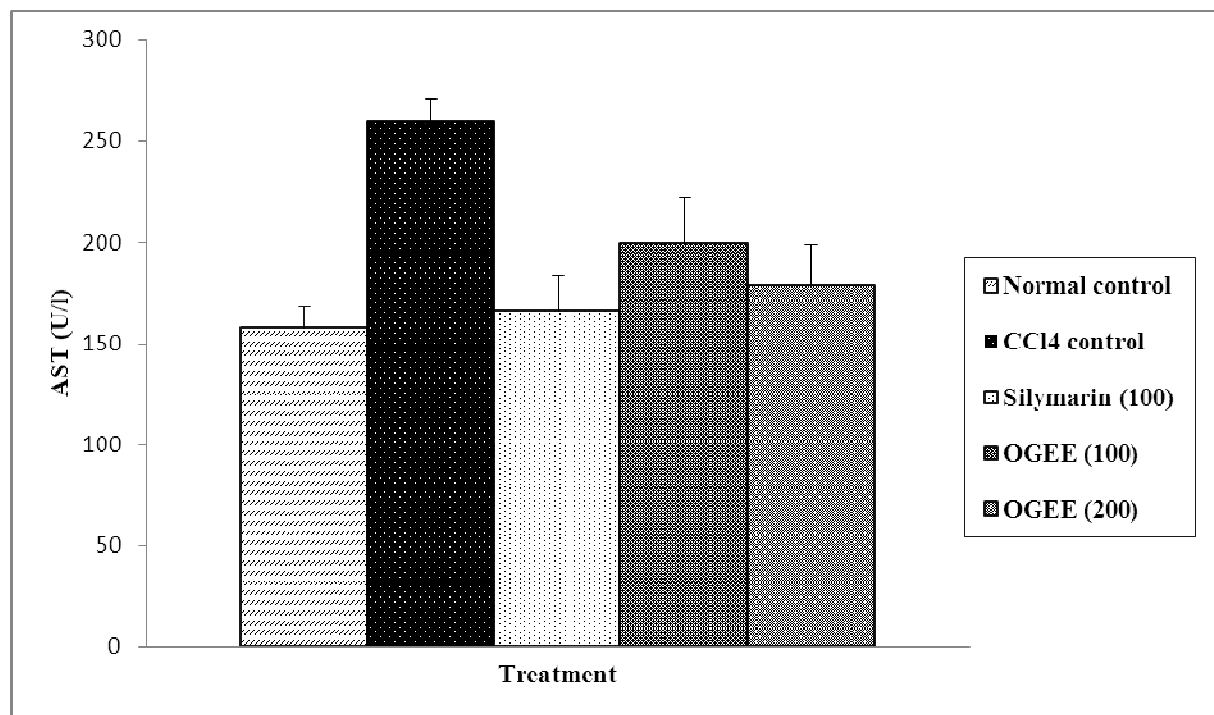


Fig. 2: Effect of *Ocimum gratissimum* ethanolic extract on ALT

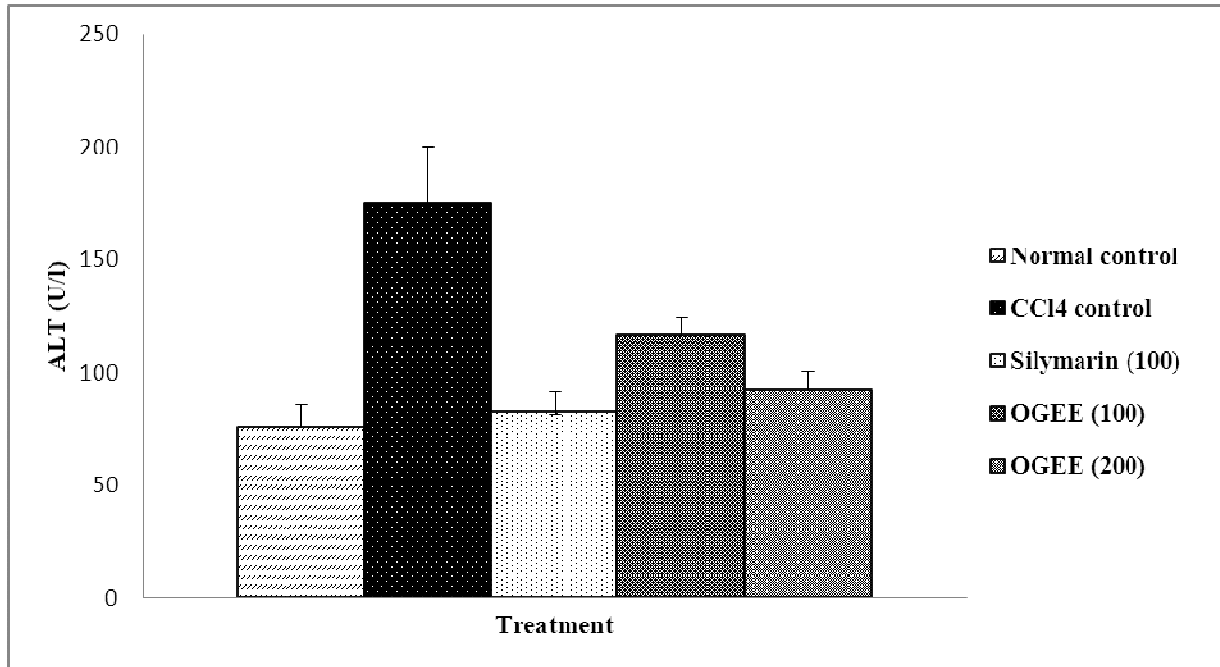


Fig. 3: Effect of *Ocimum gratissimum* ethanolic extract on ALP

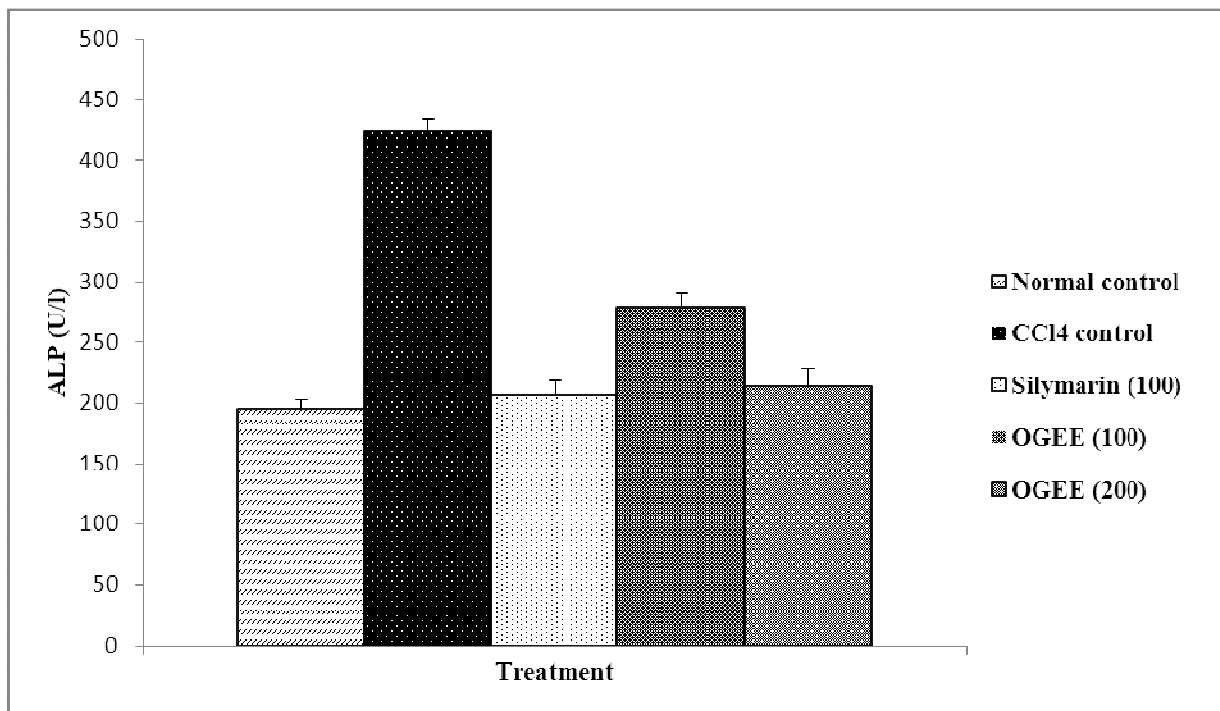


Fig. 4: Effect of *Ocimum gratissimum* ethanolic extract on Bilirubin

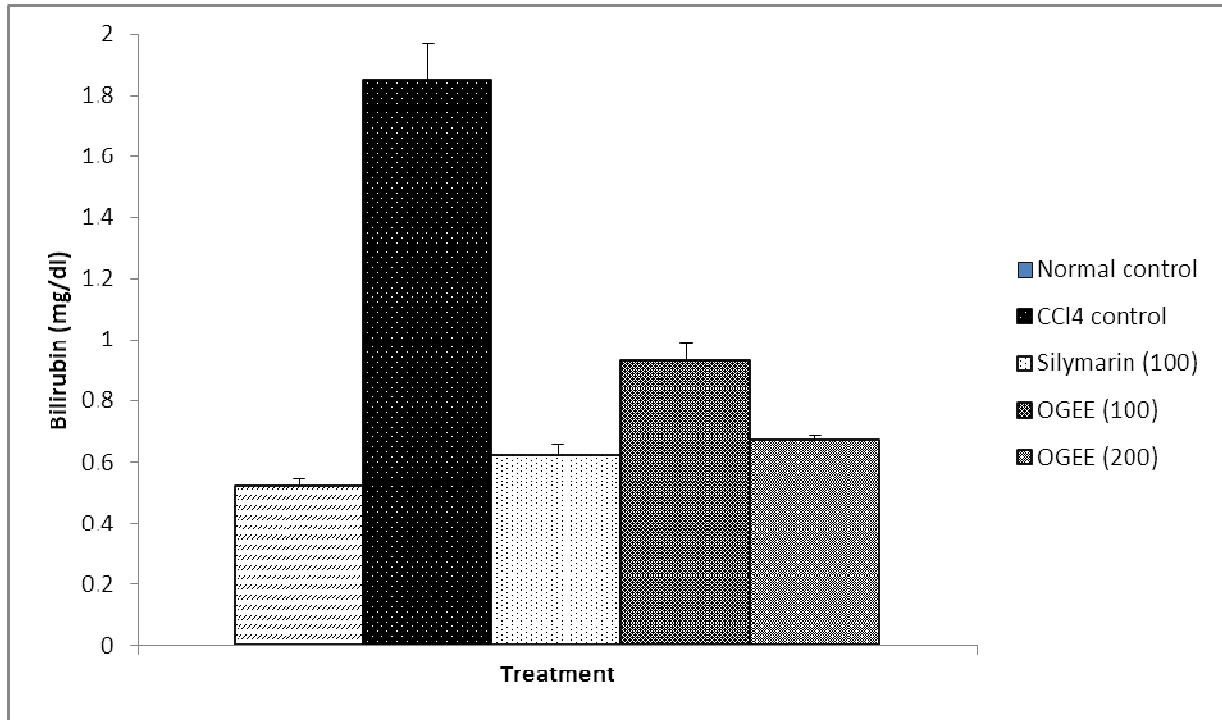
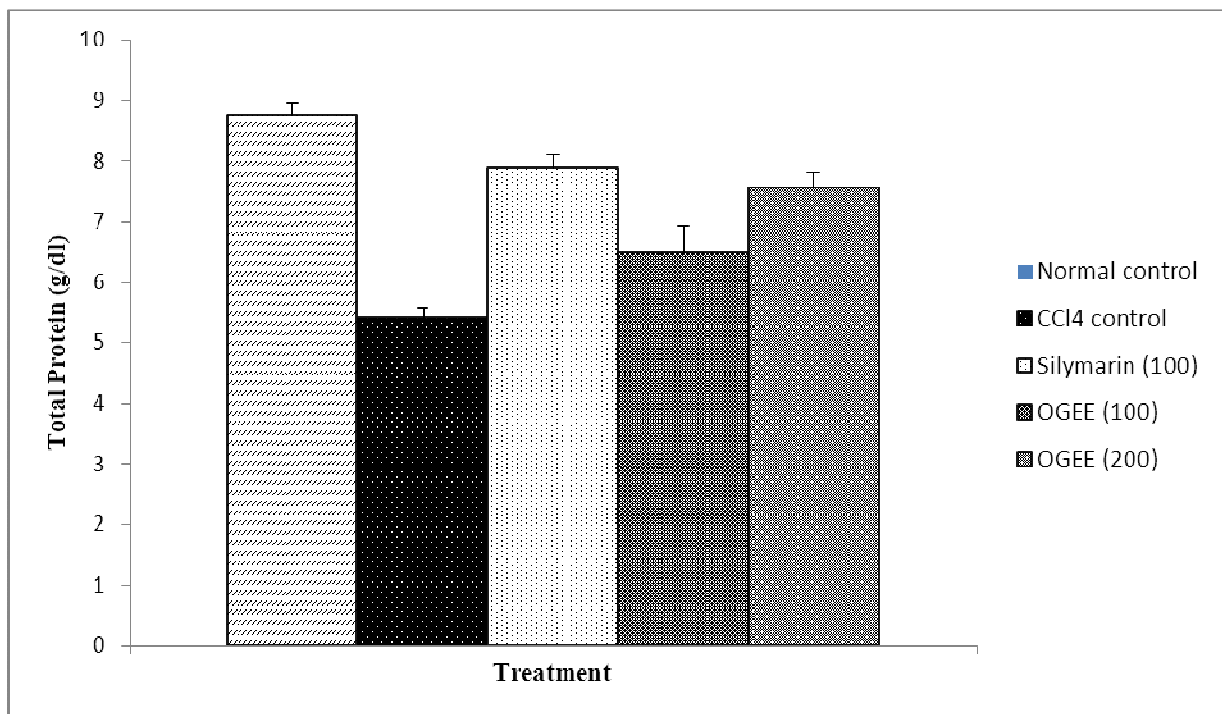


Fig. 5: Effect of *Ocimum gratissimum* ethanolic extract on Total proteins



Discussion

Liver has an important place in toxicology by virtue of its function, both qualitatively and quantitatively. The CCl₄ has been used as a tool to induce hepatotoxicity in experimental animals (18, 19). CCl₄ induce hepatic damage is due to its cytochrome P-450 enzyme system catalyzed hepatic conversion into highly reactive trichloromethyl radical (CCl₃), which upon reaction with oxygen radical gives trichloromethyl peroxide radical (OCCl₃). The radical form a covalent bond with sulfhydryl group of several membrane molecules like glutathione, considered as the initial step in the chain of events leading to lipid peroxidation and hepatic tissue destruction (20).

Normal liver functions are characterized by the balanced activities of serum marker enzymes AST, ALT and ALP, bilirubin as well as total protein. Hepatocellular necrosis leads to very high level of AST and ALT released from liver in the blood. Among the two, ALT is a better index of liver injury, as liver ALT activity represents 90% of total enzyme present in the body (21). ALP activities on the other hand are related to the functioning of the hepatocytes, increase in its activity is due to increased synthesis in presence of increased biliary pressure (22).

The ethanolic extract of *Ocimum gratissimum* leaves decreases the elevated enzyme levels of AST and ALT, which suggest the protection of structural integrity of hepatocyte cell membrane or regeneration of damaged liver cells by the extract caused by carbon tetrachloride. This effect is an agreement with the view that serum levels of aminotransferases return to normal with healing of hepatic parenchyma and regeneration of hepatocytes. Suppression of increased ALP activity, concurrent depletion of raised bilirubin level suggests the stability of the biliary dysfunction in rat liver during hepatic injury with CCl₄ (23).

However significant increase in total proteins supports the normal function of the liver. Many phytochemical reports revealed that the ethanolic extract of the plant was found to contain higher concentrations of flavonoids and glycosides. The qualitative phytochemical investigations of the ethanolic extracts of *Ocimum gratissimum* also showed positive for flavonoids by ferric chloride and alkaline reagent tests. Further, it has been reported that the flavonoid constituents of the plant possess antioxidant properties and was found to be useful in the treatment of liver damage (24). The results indicate that the ethanolic extract of *Ocimum gratissimum* has significant hepatoprotective activity. This may be probably due to the higher content of flavonoids. In conclusion, the ethanolic extract of *Ocimum gratissimum* leaves exert a clear protective action against carbon tetrachloride induced hepatic damage in rats.

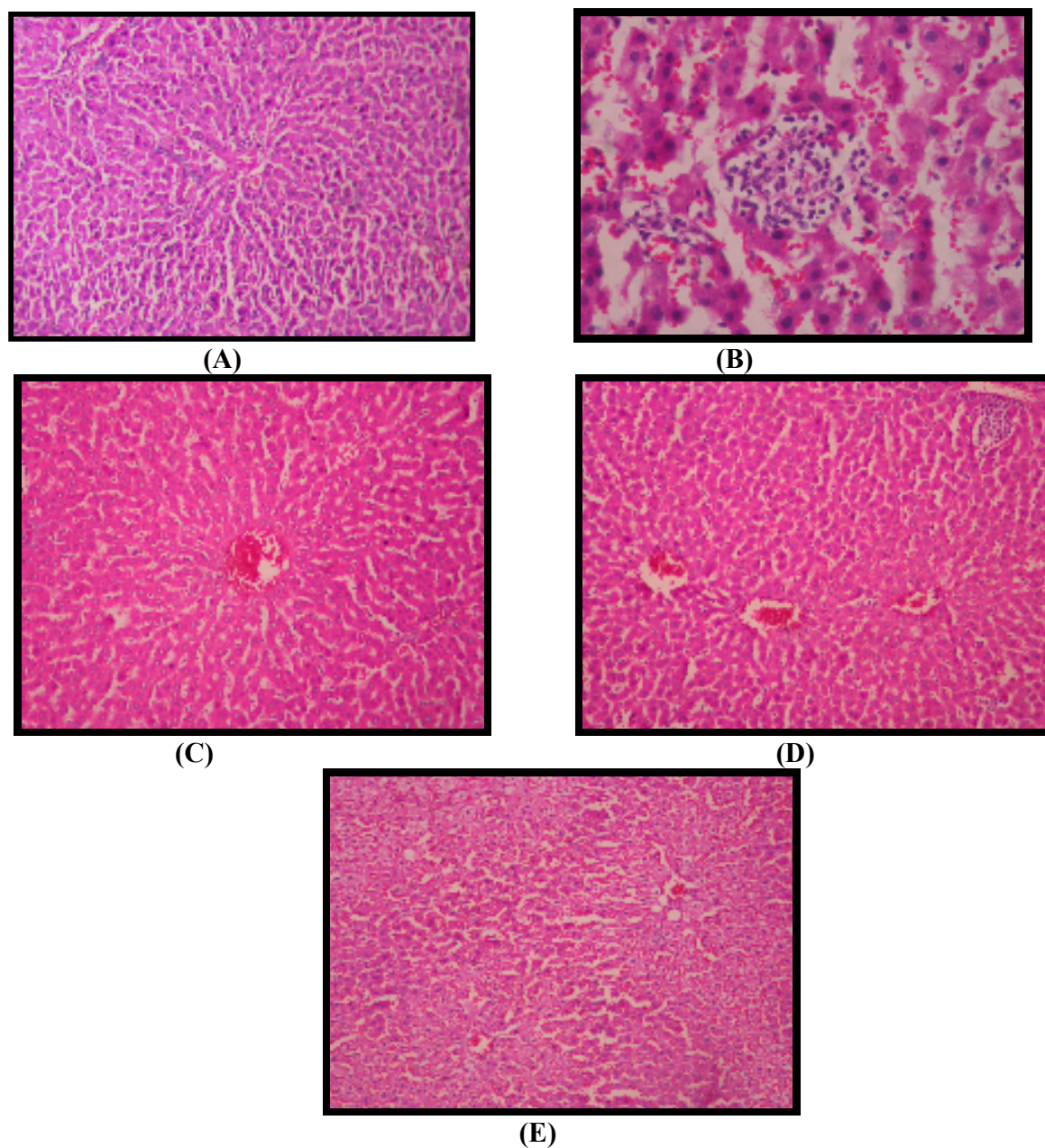


Fig 6: Liver Transverse section of hepatic cells of A]Normal (vehicle 1ml/kg) B] CCl₄+olive oil (0.2ml/kg) C] CCl₄+Silymarin (100mg/kg) D] CCl₄+OGEE (100mg/kg) E] CCl₄+OGEE (200mg/kg) at 400X.

References

1. Reddy PB, Reddy CK, Rambhau D, Venkateshvaralu V, Murthy VN. Antihepatotoxic activity of some ayurvedic preparations. *Ind J Pharm Sci* 1993; 55: 137-140.

2. Handa SS. Manegment of hepatic ailments. Pharma Times 1991; 23(4), 13.
3. Handa SS, Kapoor VK. In: Text book of Pharmacognosy II ed. New Delhi. Vallabh Prakashan 1989.
4. Ramchandran K, Kashyapa K. The useful Plants of India, 3rd ed. New Delhi. Publication and Information Directorate CSIR, 1994; 405.
5. Kirtikar KR, Basu BD, Singh B, Pal Singh M. Indian Medicinal Plants. Dehradun 1999; 1964-1965.
6. Gupta AN, Tandon N, Sharma M. Quality Standards of Indian Medicinal Plants, 2nd ed. ICMR 2005; 2:176-183.
7. Orafidiya LO, Fakoya FA, Agbani EO, Iwalewa EO. Vascular permeability increasing effect of the leaf essential oil of *Ocimum gratissimum* Linn as a mechanism for its wound healing property. Af J Traditional Complementary and Alternative Medicines 2005; 2:253-258.
8. Mbata TI and Saikai A. Antibacterial activity of essential oil from *Ocimum gratisimum* on *Listeria monocytogenes*. Int J Food Safety 2007; 15-19.
9. Pessoa LM, Morais SM, Bevilaqua CM, Luciano JH. Anthelmintic activity of essential oil of *Ocimum gratissimum* Linn and Eugenol against *Haemonchus contortus*. Vet Parasitol 2002; 109:59-63.
10. Tchoumboungang F, Zollo PH, Dagne E, Mekonnen Y. In-vivo antimalarial activity of essential oils from *Cymopogon cytratus* and *Ocimum gratissimum* on mice infected with *Plasmodium berghei*. Planta Medicine 2005; 71:20-23.
11. Khandelwal KR. Practical Pharmacognosy Techniques and Experiments, 10th ed. Nirali prakashan, Pune 2003; 149.
12. Achliya GS, Wadodkar SG, Dorle AK. Evaluation of hepatoprotective effect of *Amalkadi Ghrita* against carbon tetra chloride induced hepatic damage in rats. J Ethnopharmacol 2004; 90:229-232.
13. Reitman S, Frankel S. A Colorimetric method for the determination of serum glutamic oxoloacetic and glutamic pyruvic transaminase. Amrican J Clin Pathol 1957; 28:56-63.
14. Bessey OA, Lowery DH, Brock MJ. A method for the rapid determination of alkaline phosphatase with five cubic meters of serum. J Biol Chem 1964; 164:321-9.
15. Mallory HT, Evelyn EA. The determination of bilirubin with photoelectric colorimeter. J Biol Chem 1937; 119:481-485.
16. Kingsley SR, Frankel SJ. The determination of serum total protein albumin and globulin by the biuret reaction. J Biol Chem 1939; 128:131-137.
17. Galigher AE, Koyloff EN, In: Essential of practical microtechnique, lea and febigger, philadelohia 1971; 2:77.
18. Recnagel RO. Carbon tetrachloride hepatotoxicity statuesque and future prospects. Trends Pharmacol Sci 1983; 4:129-131.
19. Okuno H, Hazama H, Muraze T, Shiozaki Someshima YT. Drug metabolizing activity in rats with chronic liver injury, induced by carbon tetrachloride relationship with the hydroxyproline content in liver. Japnis J Pharmacol 1986; 41: 363-71.
20. Saraswat B, Visen PK, Patnaik GK, Dhawan BN. Anticholestic effect of picroliv, active hepatoprotective principle of *Picrorhiza kurrooa*, against carbon tetra chloride induced cholestatis. Indian J Exp Bio 1993; 31:316-318.
21. Moss DW, Butterworth PJ. In: Enzymology and Medicine, Pitman Medical, London 1974; 139.
22. Prabhu K, Ramchandra S, et al. Hepatoprotective and antioxidant activities of flowers of *calotropis procera* in CCl₄ induce hepatic damage. Ind J Expri Bio 2007; 45:304-310.
23. Gole MK, Dasgupta S, Ghosal RK. J. Hepatoprotective effect of *Amoora Rohituka*. Int J Pharmacog 1997; 5:138-322
24. Chopra K, et al. Hesperidine, a citrus bioflavonoid, decrease the oxidative stress produce by CCl₄ in rat liver and kidney. BMC Pharmacology 2005; 5:2.