

EVALUATION OF *TEPHROSIA CALOPHYLLA* FOR ANTIULCER ACTIVITY IN EXPERIMENTAL RATS

S. Divya*, V. Haritha, K. V. S. R. G. Prasad

Department of Pharmacology, Institute of Pharmaceutical Sciences, Sri Padmavati Mahila University, Tirupathi 517502, Andhra Pradesh, India.

Address for Correspondence:

Dr. K. V. S. R. G. Prasad, Professor

Institute of Pharmaceutical Technology,

Tirupathi-517502,

Andhra Pradesh,

India.

Email: kvsrgprasad@yahoo.co.in, divya.pharmacy.50@gmail.com

Tel: 9440432507, 8143687535.

Summary

The antiulcer activity of ethanolic extract of *Tephrosia calophylla* leaves (ETC) was investigated in Pylorus ligation, Ethanol induced, Indomethacin induced ulcer models in wistar rats. Gastric ulcers were induced by oral administration of ethanol, indomethacin and by pyloric ligation. The ETC was administered at a dose of 50 and 100 mg/kg orally. Ranitidine (50 mg/kg) was used as Reference standard. The extract (50 and 100 mg/kg) showed significant ($p < 0.01$) reduction in gastric volume, free acidity, total acidity and ulcer index as compared to control. This present study indicates that ETC has potential antiulcer activity in all 3 models. These results may further suggest that ETC was found to possess cytoprotective as well as ulcer healing properties, which might be due to its antisecretory activity.

Keywords: *Tephrosia calophylla*, Pylorus ligation, Ethanol induced ulcers, indomethacin induced ulcers, ulcer index.

Introduction

The treatment of peptic ulcers with plant products used in folk medicine and the protection of induced gastric ulcer in laboratory animals using medicinal plants was reported [1]. In traditional medicine, several plants and herbs have been used to treat gastrointestinal disorders, including gastric ulcers [2]. Generally plant flavonoids have been found to be effective against ulcer in experimental animals [3]. The present study has, therefore been conducted to evaluate the antiulcer activity of ethanolic extract of *Tephrosia calophylla* leaves [ETC] using ulcer models in rats.

There are two main approaches for treating peptic ulcer. The first deals with reducing the production of gastric acid and the second with reinforcing gastric mucosal protection [4, 5]. Although a number of antiulcer drugs such as H₂ receptor antagonists, proton pump inhibitors and cytoprotectants are available, all these drugs have side effects and limitations [6]. There is thus a need to search for natural substances having antiulcer properties. This has been the basis for the development of new antiulcer agents, which include herbal substances.

Materials and Methods

Plant collection and extract preparation

The leaves of *Tephrosia calophylla* was collected from forests of Talakona, Tirupathi, A.P, South India during November 2009 and authenticated by Dr. Madhavachetty, Botanist SVU, Tirupathi. *Tephrosia calophylla* Bedd belongs to the family Fabaceae, perennial undershrub [7]. The whole plant of *T. calophylla* is reported to contain flavanoids like Tephcalostan B, C, D, tephrowatsin C, tephrosin, tephrosone C- prenyl flavanoids, Kaempferol-3-O- β -D glucopyranoside were isolated from roots of *T. calophylla* [8]. Cytotoxic benzyl and coumestan derivatives are also isolated from *T. calophylla* [9]. Root tubers of *T. calophylla* are used for antiseptic, ulcers, anti-inflammatory, antibacterial, antifungal [10]. However there are no reports on the antiulcer activity of the plant hence the present study was designed to verify the claims of the native practioners.

The leaves of *T. calophylla* were air dried and powdered. Plant material was extracted by maceration with ethanol for 72 hrs. The extract was concentrated to get the solid mass. The yield obtained was 15.8%. The extract, ranitidine and indomethacin were suspended in 0.5% sodium carboxy methyl cellulose (SCMC) and used for anti ulcer studies.

Animals

Healthy adult Male albino rats of wistar strain weighing between 150-200 g are used. They were housed in polypropylene cages and maintained under standard conditions (12 hr light: 12 hr dark cycle; 25 \pm 3o c and 35-60 % humidity). All animals had free access to standard lab chow and tap water.

Drugs and chemicals

The following drugs were used: Ranitidine (Korpan Pharma Ltd., Mumbai), Indomethacin (Madras Pharmaceutical Ltd., Chennai). The chemicals used and other solutions were of analytical grade. All drugs and reagents were prepared immediately before use.

Acute oral toxicity studies

A safe oral dose of the extract was determined by acute oral toxic class method of Organization of Economic Co-operation and Development (OECD) as per 423 guidelines [11]. Albino rats of Wistar strain weighing between 150-200 g were used in the study. The animals were fasted overnight; provided only water after that extract was administered to the groups orally at the dose level of 5 mg/kg body weight by gastric intubation and the groups were observed for 14 days. If mortality was observed in 2 or 3 animals among 6 animals then the dose administered was assigned as toxic dose. If mortality was observed in one animal, then the same dose was repeated again to confirm the toxic dose. If mortality was not observed, the procedure was repeated for further higher doses such as 50, 300 and 2000 mg/kg body weight. The animals were observed for toxic symptoms such as behavioral changes, locomotion, convulsions and mortality for 72 hrs.

Phytochemical screening

The ethanolic extract of leaves of *T.calophylla* Bedd was subjected to preliminary phytochemical screening [12].

Antiulcerogenic activity

Pylorus ligation in rats (Shay rat)

The rats were fasted for 48 hours before the experiment but with free access to water and just two hours before starting the experiment the water also withdrawn. One hour after drug or saline administration, under light ether anaesthesia the stomach is replaced carefully and the abdominal wall closed by interrupted sutures [13]. Nineteen hours later, the pylorus ligated rats were sacrificed and their stomachs were dissected out after ligating the oesophagus at cardiac end. The modification of the method described by Kulkarni was followed which involves fasting the animals for 36 hrs and pyloric ligation only for 6 hrs [14]. Each stomach was cut opened along the greater curvature and the contents were collected into a centrifuge tube, the number and size of ulceration was scored [15].

The following parameters like ulcer index [16], free acidity, total acidity [17], acid volume [18] and pH [19] is measured.

Ethanol induced mucosal damage in rats (Cytoprotective activity)

Intragastric application of absolute ethanol is a reproducible method to produce gastric lesions in experimental animals [20]. The rats were fasted for 24 hours before the experiment but excess water allowed and just two hours before starting the experiment the water also was removed. Thirty minutes after their pre-treatment with standard and test drugs, all animals received 1 ml of absolute ethanol. After one hour the stomachs were excised, cut along the greater curvature and gently rinsed with tap water. The stomachs were stretched and ulcers were using examined under a 3-fold magnifier and the following parameters were measured [21]. The following parameters like pH, ulcer index and severity score is measured.

Indomethacin induced ulcers in rats

Nonsteroidal anti-inflammatory agents, like indomethacin and acetyl- salicylic acid, induce gastric lesions and in experimental animals by inhibition of gastric cyclo-oxygenase resulting in less formation of prostacyclin, the predominant prostanoid produced in the gastric mucosa [22].The rats were fasted for 48 hours before the experiment but excess water was supplied *ad libitum* and just two hours before starting the experiment the water was also withdrawn. Indomethacin, at the dose of 20 mg/kg (4mg/ml dissolved in 0.1% Tween 80 solution) p.o was administered twice at 15 hours intervals to produce gastric ulcers [19]. The animals were sacrificed 6 hours after the second dose of indomethacin, the leaf extract of *T.calophylla* and standard drug were administered 60 minutes before each dose of indomethacin to their respective groups. The animals were sacrificed with excess dose of ether. The stomachs are excised, cut along the greater curvature and gently rinsed with tap water. The stomachs were stretched and ulcers were examined under a 3-fold magnifier and the following parameters were measured [21]. The following parameters like pH, ulcer index and severity score is measured.

Statistical analysis

The values are expressed as mean \pm S. E. M. and statistical significance between treated and control was performed by One-way analysis of variance (ANOVA) followed by Bonferroni's multiple comparison test.

Results**Phytochemical screening**

Phytochemical analysis of the ETC leaves revealed the presence of flavanoids, alkaloids, saponins and tannins.

Acute toxicity studies

Acute oral toxicity test was performed as per OECD-423 guidelines [11]. Single dose of (5, 50, 300, 800 and 2000 mg/kg) of ETC administered to male albino rats showed no death up to 800 mg/kg, when observed for 4 hrs and 24 hrs period. There were no physical signs of toxicity in the treated animals. But animal death was observed at a dose of 1000 mg/kg in rats. Gross behavioural changes- animal did not show gross behavioural changes up to the dose of 800 mg/kg body weight evidenced by normal breathing and absence of tremors, convulsions, diarrhoea and salivation. At a dose of 1000 mg/kg after 1 hr, shows toxicity symptoms like CNS depression, irritation, sedation, jerking movements, loss of writing reflex and finally respiratory paralysis. These observations revealed that the oral LD50 of ETC is greater than 800 mg/kg in Rats.

Antiulcer activity study**Effect of ETC on Pylorus ligation induced gastric ulcers**

In Pylorus ligated rats, oral administration of ETC showed significant reduction in ulcer index as compared to control. Activity of ETC preventing in the formation of lesions is comparable to that of standard drug ranitidine. Volume of gastric contents, total acidity and free acidity were reduced, pH was increased significantly by administration of ETC ($p < 0.001$) when compared to control group (Table 1 and Figure 1).

Effect of ETC on Ethanol induced gastric ulcers

In control animals, oral administration of absolute ethanol produced characteristic lesions in the glandular portion of rat stomach. Upon opening the stomach, elongated bands of thick, black and dark red lesions were found in the mucosa. In animals pre-treated with ETC significant ($P < 0.001$) inhibition of gastric ulceration was observed when compared to control group. ETC caused significant ($P < 0.001$) reduction in ulcer index and severity score when compared to control. Also animals pre-treated with ranitidine significantly ($P < 0.001$) reduced the ulcer index and severity score (Table 2 and Figure 2).

Effect of ETC on Indomethacin induced gastric lesions

Indomethacin treatment resulted in the production of gastric lesions, mainly in the glandular segments of the stomach. ETC caused significant ($P < 0.001$) reduction in ulcer index and severity score when compared to control. pH was increased significantly by ETC ($P < 0.001$) when compared to control group (Table 3 and Figure 3).

Table 1: Effect of *T.calophylla* on various parameters in pylorus ligation model

No	Drug and dose	pH	Acid volume	Total acidity mEq/lt	Free acidity mEq/lt	Severity score	Ulcer index
I.	Vehicle treated (2 ml)	2.08±0.16	7.83±0.27	80.83±1.87	52.16±2.13	2.16±0.28	10.56±0.14
II.	Ranitidine (150 mg/kg)	5.83±0.30***	4.68±0.50**	37.33±2.37***	28±1.47***	0.75±0.28**	5.17±0.08***
III.	Ethanollic extract of <i>T.calophylla</i> (50mg/kg)	4.5±0.44***	4.47±0.48***	61.83±2.06***	30.33±1.76***	0.83±0.15*	6.90±0.05***
IV.	Ethanollic extract of <i>T.calophylla</i> (100mg/kg)	6.15±0.12***	4.08±0.25***	36.66±2.01***	27.66±1.45***	0.66±0.25**	3.44±0.04***

Values are expressed as mean ± SEM (n=6)

* $p < 0.05$, ** $p < 0.01$, *** $p < 0.001$ when compared to control group

Table 2. Effect of *T.calophylla* on various parameters in ethanol induced ulcers

Group	Drug	Dose	pH	Severity score	Ulcer index
I.	Vehicle treated	2 ml	2.08±0.21	2.66±0.22	10.81±0.09
II.	Ranitidine	150 mg/kg	5.16±0.30***	0.91±0.47**	5.27±0.15***
III.	Ethanollic extract of <i>T. calophylla</i>	50 mg/kg	4.58±0.44***	1.16±0.15*	5.23±0.12***
IV.	Ethanollic extract of <i>T. calophylla</i>	100 mg/kg	6.33±0.12***	0.33±0.25***	1.71±0.04***

Values are expressed as mean ± SEM (n=6)

* $p < 0.05$, ** $p < 0.01$, *** $p < 0.001$ when compared to control group

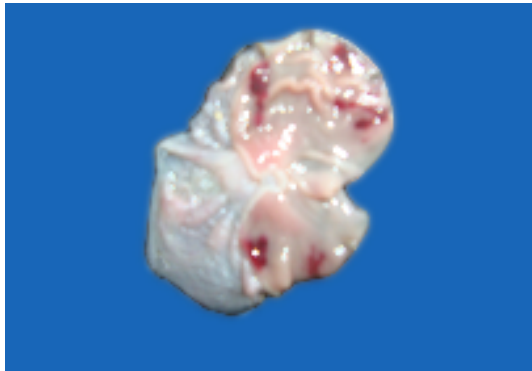Table 3. Effect of *T.calophylla* on various parameters in indomethacin induced ulcers

Group	Drug	Dose	pH	Severity score	Ulcer index
I.	Vehicle treated	2 ml	2.13±0.21	2.44±0.22	10.67±0.11
II.	Ranitidine	150 mg/kg	4.35±0.27***	1.08±0.52**	5.27±0.16***
III.	Ethanollic extract of <i>T.calophylla</i>	50 mg/kg	5.58±0.42***	0.75±0.40*	5.19±0.06***
IV.	Ethanollic extract of <i>T.calophylla</i>	100 mg/kg	6.41±0.24***	0.25±0.25***	1.70±0.04***

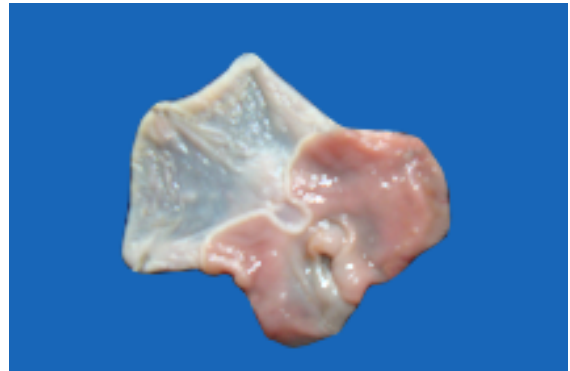Values are expressed as mean ± SEM (n=6)

* $p < 0.05$, ** $p < 0.01$, *** $p < 0.001$ when compared to control group

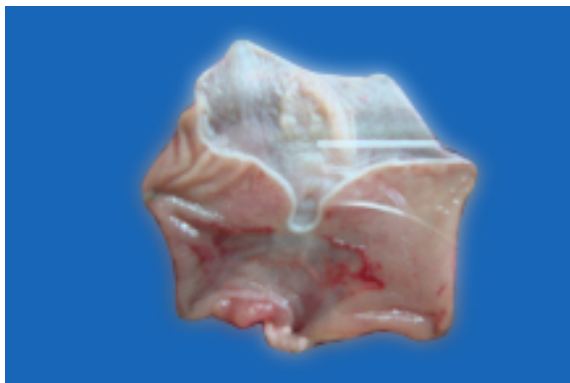Macroscopical view of Pylorus Ligation induced Ulcers



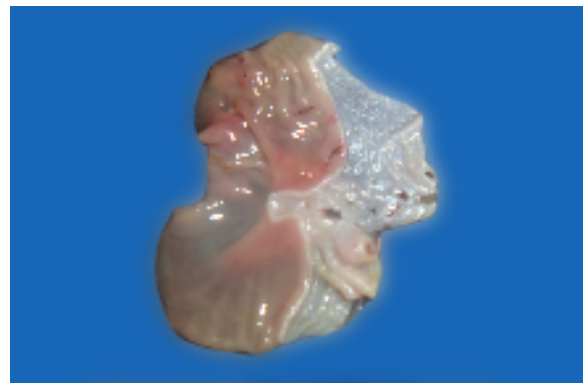
1 a) Control (PL) shows severe damage in mucosal layer



1 b) Standard Ranitidine shows protection in mucosal layer

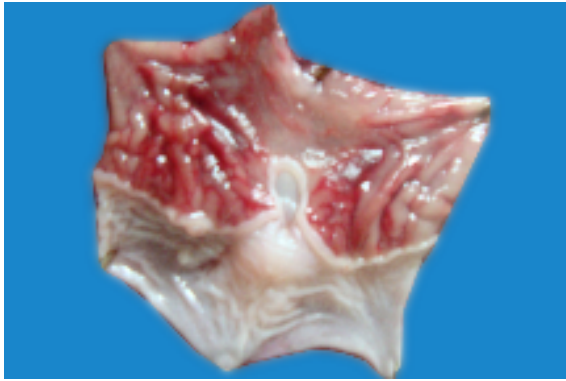

1 c) ETC 50 mg/kg shows protected mucosal layer

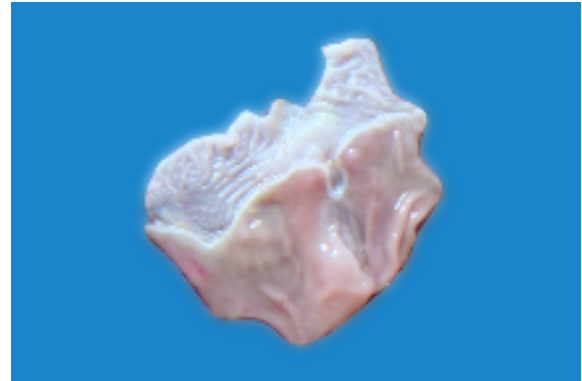

1 d) ETC 100 mg/kg shows protected mucosal layer

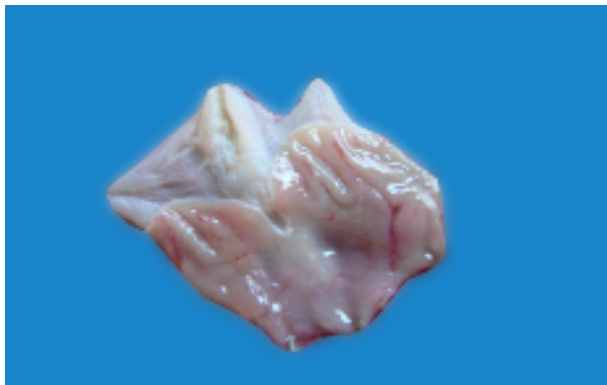Macroscopical view of Ethanol induced Ulcers



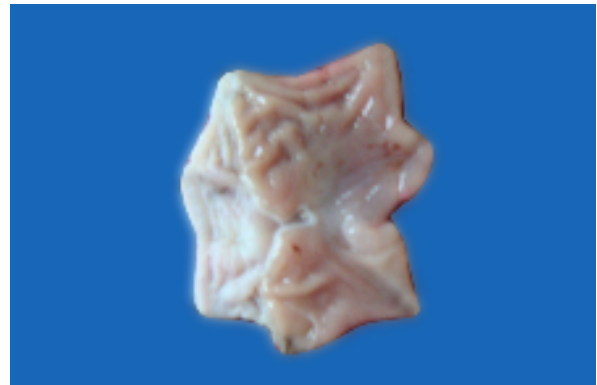2 a) Control shows severe damage in mucosal layer



2 b) Standard Ranitidine shows protection in mucosal layer

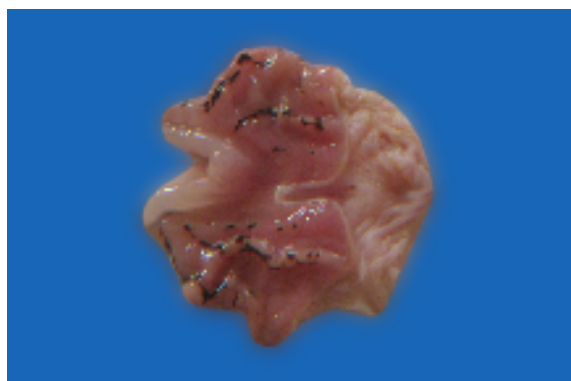


2 c) ETC 50 mg/kg shows protected mucosal layer

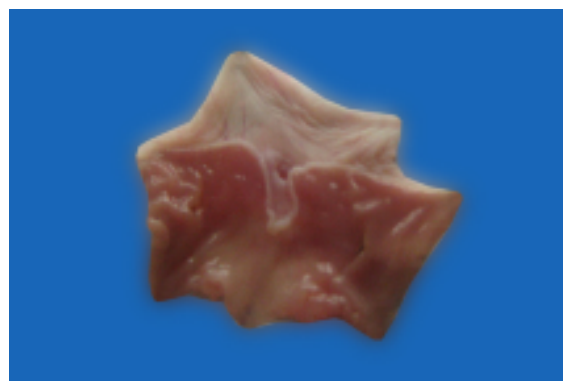

2 d) ETC 100 mg/kg shows protected mucosal layer

Macroscopical view of Indomethacin induced Ulcers



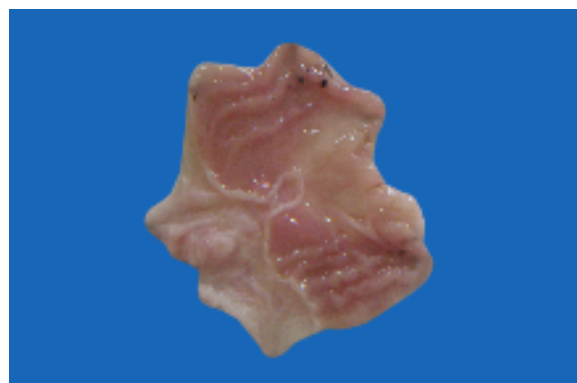3 a) Control shows severe damage in mucosal layer



3 b) Standard Ranitidine shows protection in mucosal layer



3 c) ETC 50 mg/kg shows protected mucosal layer



3 d) ETC 100 mg/kg shows protected mucosal layer

Discussion

The present study investigated the effect of ETC on the gastric ulcers. The causes of gastric ulcer in pyloric ligation believed to be due to stress induced increase in gastric hydrochloric acid secretion or stasis of acid and the volume of secretion is also an important factor in the formation of ulcer due to exposure of the unprotected lumen of the stomach to the accumulating acid [12].

Pylorus ligation induced ulcer is one of the most widely used methods for studying the effect of drugs on gastric secretion. Agents that decrease gastric acid secretion or increase mucus secretion are effective in preventing the ulcers induced by this method. The ligation of the pyloric end of the stomach causes accumulation of gastric acid in the stomach. The original shay rat model involves fasting of rats for 72 hrs, followed by ligation of the pyloric end of the stomach for 19 hrs [13]. In the present study the modification of shay rat model described by Kulkarni [14] was followed, which involves fasting of animals for 36 hrs and pyloric ligation only for 6 hrs. ulcer index was determined 6 hrs after pylorus ligation. Ranitidine and ETC significantly decreased the secretion of gastric aggressive factors, free acidity and total acidity. This suggests that ETC is having an antisecretory effect.

Ethanol induced gastric ulcer and indomethacin induced gastric ulcers were employed to study the cytoprotective effect of ETC. ethanol induced gastric lesion, due to its corrosive effect. It rapidly prevents the gastric mucosa causing cell and plasma membrane damage, leading to increased membrane permeability to sodium and water [23]. It also produces massive intracellular accumulation of calcium, which represents a major step in the pathogenesis of gastric mucosal injury. This leads to cell death and exfoliation in the surface epithelium [24]. ETC shows protection against characteristic lesions produced by ethanol administration this antiulcer effect of ETC may be due to gastric cytoprotection.

Indomethacin produces erosions and ulcers in the stomach due to the inhibition of prostaglandin synthesis [25]. In the stomach prostaglandin plays a vital protective role. They stimulate the secretion of bicarbonate and mucus, maintain mucosal blood flow and regulate mucosal cell turnover and repair [26]. The suppression of prostaglandins synthesis by NSAIDS such as indomethacin results in increased susceptibility to mucosal injury and gastro duodenal ulceration [27]. It is also well known that prostaglandins synthesized in large quantities by gastro intestinal mucosa can prevent experimentally induced ulcers by ulcerogens. Thus, when the gastric lesions are induced by indomethacin the cytoprotective effect of the antiulcer agent can be mediated through endogenous prostaglandins [28]. The results obtained in our study showed that the ulcer index was significantly reduced. Therefore, it can be concluded that ETC might have stimulated the secretion of PG or possess cytoprotective activity.

Conclusion

In conclusion, our results suggest that the efficacy of ETC in preventing and healing ulcers is based on its ability to stimulation of an antisecretory and cytoprotective activities. Even if the mechanism responsible for this antiulcerogenic effect remain unknown, our phytochemical analyses showed that the presence of flavonoids and tannins obtained from leaves of *T. calophylla* may be responsible for the strong antiulcer effect on the surface of the gastric mucosa.

References

1. I. B. Suffredini, E. M. Bacchia, and J. A. A. A. Sertie, *J. Ethanopharmacol.* 65, 217 (1999)---add title.
2. Satyavathi GV, Gupta AK and Tandon N, (1987) *Ocimum sanctum* Linn. (Tulsi), in medicinal plants of India, Indian Council of Medical Reaserch, New Delhi, India, 27: 574.

3. David A. Lewis, William N. Fields and Graham P. Shane, (1999) J Ethanopharmacol., 65, 283.
4. Hoogerwerf W A and Pasricha PJ, (2001) Agents used for control of gastric acidity and treatment of peptic ulcers and gastrooesophageal reflux disease, in The Pharmacological Basis of Therapeutics, edited by Hardman JG, Limbird LE and Goodman Gilman A (Mc Graw- Hill, New York), 1005.
5. Valle DL, (2005) Peptic ulcer diseases and related disorders, in Harrison's Principles of internal medicine, edited by E Braunwald, AS Fauci, DL Kasper, SL Hauser, DL Longo and Jameson JL (Mc Graw-Hill, New York) 1746.
6. Ariyoshi I, Toshiharu A, Sugimura F, Abe M, Matsuo Y and Honda T, (1986) Recurrence during maintenance therapy with histamine H₂ receptor antagonist in cases of gastric ulcer, Nihon Univ J Med, 28: 69.
7. Thammanna, Narayana Rao K, Madhava chetty. (1994) Angiospermic wealth of Tirumala, Department of Gardens, Tirumala Tirupathi Devasthanams, Tirupathi, India.
8. Pennaka Hari Kishore, (2003) A New Coumestan from Tephrosia calophylla, Chem. Pharm. Bull. 51 (2) 194-196.
9. Seru Ganapathy, G. Veera Knatha Srilakshmi, S. T Pannakal. (2009) Cytotoxic benzyl and coumestan derivatives from *Tephrosia calophylla*. Phytochemistry, 70, 95-99.
10. Madhava chetty K, Sivaji. K, Tulasi Rao. K, (2008) Flowering plants of chittoor District, Dept. of Botany, S. V. University, Tirupathi, Andhrapradesh.
11. Ecobiocon DJ. (1997) The basis of toxicity testing. New York: CRC press; 43-49.
12. Dhuley JN. (1999) Protective effect of Rhinax, a herbal formulation against physical and chemical factors induced gastric and duodenal ulcers in rats. Indian J. Pharmacol. 31, 128-132.
13. Shay H, Komarov SA, Fele SS, Meranze D, Gruenstein H, Siple H. (1945) A simple method for uniform production of gastric ulceration in rat. Gastroenterology, 5: 43-61.
14. Kulkarni SK. (1999) Handbook of experimental pharmacology. 3rd ed. New Delhi: Vallabh Prakash; 148-150.
15. Mohammed Ahamthulla, Mohammed Asad and V. Satya Prasad (2009). Antiulcer activity of *Allium sativum* bulb juice in rats. Saudi Pharmaceutical journal. 17(1): 70-77.
16. Rao Ch.V, Ojha S.K, Radhakrishnan K, Govindarajan R, Rastogi, Merhrotra S, Pushpangadan P (2004). Antiulcer activity of *Urtica salicifolia* rhizome extract. Journal of Ethnopharmacology, 91: 243-249.
17. Mukherjee, K.L. (1989) Medical Laboratory Technology. New Delhi. Tata Mc Graw-Hill. 3: 1086-1088.
18. Susan G., Sathimoorthy A., Sathimoorthy SS. (1990) Effect of alpha tocopherol on gastric ulcers induced by pylori ligation in rats. Indian J.of Pharmacology. 31: 431-33.
19. Parmar, S.N. and Desai, J.K. (1993) A review of the current methodology for the evaluation of gastric and duodenal anti-ulcer agents. Indian J. of Pharmacology, 25: 120-135.
20. Mohmood, A.A., Sidik, K. and Salmah, I. (2005) Anti-ulcer and Gastro protective effects of honey in combination with *Trigonella foenum graecum* seeds extract on experimental gastric ulcer in rats. International J.of Molecular and Advance Sciences. 1: 225-229.

21. Deshpande S.S, Shah G.B, Parmar N.S, (2003) Anti-ulcer activity of *Teophrosia purpurea* in rats. Indian journal of pharmacol, 35; 168-172.
22. Aguwa C.N and Mittal G.C. (1981) Study of antiulcer activity of aqueous extract of leaves of *Pyrenacanth standtii* using various models of experimental gastric ulcer in rats. Eur. J.of Pharmacol, 74: 215-219.
23. Soll AH. (1990) Pathogenesis of peptic ulcers and Implication for therapy. N Engl J Med; 322:909-16.
24. Surendra S. (1999) Evaluation of gastric anti-ulcer activity of fixed oil of tulsi and possible mechanism. Indian J Exp Biol, 36: 365-9.
25. Vedavyasa S. (1999) Gastric mucosal cellular changes induced by indomethacin in male albino rats. Indian J Exp Biol: 37: 365-9.
26. Hayllar, J., Bjarnason, I., (1995) NSAID'S, COX-2 Inhibitors and the gut. Lancet, 346, 522-524.
27. Atay, S., Tarnawski, A.S., Dubois, A., Eicosanoids and the stomach. (2000) Prostaglandins other lipid mediators, Lancet, , 61, 105-124.
28. Yamamoto K, Kakegawa H, Ueda H, Matsumoto H, Sudo Y, Miki T and Satoh T, (1998) Gastric cytoprotective anti-ulcerogenic actions of hydroxychalcones in rats, Planta Med, 58:389.