

## TOXICOLOGICAL STUDIES ON ALBINO WISTAR RATS CO-TREATED WITH CHLOROQUINE PHOSPHATE AND CEFUROXIME AXETIL

Etim, O.E., <sup>1\*</sup>; Ekong, M.B.<sup>2</sup>; Bassey, U.E.<sup>2</sup>; Akpan, E.J.<sup>2</sup>

<sup>1</sup>Department of Biochemistry, Faculty of Basic Medical Sciences, University of Uyo, Nigeria

<sup>2</sup>Department of Anatomy, Faculty of Basic Medical Sciences, University of Uyo, Nigeria

[\\*betobong123@yahoo.com](mailto:betobong123@yahoo.com)

### Abstract

Toxicological studies on albino Wistar rats co-administered with chloroquine phosphate (CQ) and cefuroxime axetil (CE) was undertaken. Assays carried out included liver enzymes, bilirubin, urea and creatinine. Histology of liver was also investigated. Data obtained were analyzed using appropriate statistical methods at ( $P < 0.05$ ). Alanine amino transferase (ALT) decreased significantly in all the treated groups compared to control. Aspartate amino transferase (AST) activity decreased significantly only in the group co-treated with chloroquine and cefuroxime compared with control. Alkaline phosphatase (ALP) activity decreased significantly in the group co-treated with CQ and CE, and in group treated with cefuroxime alone. There was no significant difference in uric acid concentration when compared with control. Total bilirubin concentration increased significantly ( $P < 0.05$ ) in all treated groups while no significant difference occurred in direct bilirubin and urea concentrations respectively. Creatinine concentration increased significantly ( $P < 0.05$ ) in the groups treated with chloroquine and cefuroxime respectively. Comparing the photomicrographs of liver tissues co-treated with chloroquine and cefuroxime to those treated with chloroquine alone, cefuroxime appear to ameliorate the effects of chloroquine on the tissues. This study has shown that it is more beneficial to administer chloroquine together with cefuroxime as the toxic effect of chloroquine appears to be reduced by cefuroxime.

**Keywords:** liver enzymes, chloroquine, cefuroxime, liver, urea, creatinine.

## Introduction

High prevalence of malaria and typhoid in the tropics has made co-infections common. However, the actual and precise underlying mechanism to explain the association between malaria and salmonella species infection is still uncertain [1].

The treatment of malaria and typhoid co-infection is a common phenomenon in many parts of Africa [2]. This is because malaria and typhoid fever have been reported as being among the most endemic diseases in the tropics. Both diseases have been associated with poverty and underdevelopment with significant morbidity and mortality. An association between malaria and typhoid fever was first described in the medical literature in the middle of the 19<sup>th</sup> century and was named typhomalarial fever by the United States Army [3]. Typhoidal salmonellosis, as a cause of salmonella bacteraemia was demonstrated in a study of dual malarial –salmonella infection in Karachi, Pakistan in which 21 of 22 positive blood cultures for salmonella grew *S. typhi* or *S. paratyphi* A or B [4].

In contrast was the non typhoidal salmonellosis which predominate the reports from Cameroon and Gambia. In the study of 200 febrile patients in Cameroon, [5] reported a 32.5% incidence of microbiologically proven concurrent infection with malaria a *S. typhymurium* (diagnosed via blood and /or stool positive for salmonella) compared with *S. typhi* 17% and paratyphi 42% of patients with non-typhoidal salmonellae [6].

The need for new antimicrobials has increased due to current problems of resistances associated with frequent use of antibiotics. Much attention is drawn to the search for new and effective antimicrobials from plants and other natural or synthetic products which contain active compounds of different structures and templates which may be potentially useful as active drugs and agrochemicals readily biodegradable and environmentally safer [7].

The World Health Organisation (WHO) recommends that countries experiencing resistance to conventional monotherapies such as chloroquine, amodiaquine or sulfadoxine-pyrimethamine should use combination therapies preferably those containing artemisinin derivatives (artemisinin-base combination therapies) for *Plasmodium falciparum* malaria.

It has been suggested that along with anti-malarial drugs, other medications that may improve the serum status of the affected biochemical parameters should be incorporated in the treatments strategy during and after malarial infection. This is imperative in view of the immense

importance of the serum components affected [8]. Recently, administration of certain cephalosporins (antibiotics) alongside 4-aminoquinoline (chloroquine) an anti-malarial drug has proved to be very effective against pathogenic micro organism. However, less emphasis has been placed on the biochemical consequences i.e. effectiveness or damage done by drug combination to tissue, and systems and this forms the basis of the present study.

## Materials and Methods

### **Antimalarial: Chloroquine phosphate (250 mg)**

Chloroquine phosphate (250 mg) is manufactured by Evans Medical PLC (RC 1161), Km 32, Lagos – Badagry Expressway, Agbara Industrial Estate, Agbara, Ogun State, Nigeria.

### **Antibiotic: Cefuroxime axetil tablets (500 mg)**

Cefuroxime axetil tablet (500 mg) is manufactured by Okasa Pharma PVT Ltd, L-2 Additional MIDC Area, Satara 415004- India. It is manufactured for CIPLA Ltd India under loan licence. It is marketed by Evans Medical Plc, Agbara Industrial Estate, Agbara, Ogun State, Nigeria.

### **Experimental design and treatment of animals**

A total of twenty four (24) albino Wistar rats (male and female) were weighed with average weight of 151g and divided into four (4) different groups of six (6) per group and put into rat cages. Group 1 rats were given normal rat pellets and water. Group 2 rats were treated with 4.17 mg/kg body weight (bw) of chloroquine (CQ). Group 3 rats were administered concomitantly with 4.17 mg/kg body weight (bw) of chloroquine and 8.33 mg/kg bw of cefuroxime (CE). Group 4 rats were treated with 8.33 mg/kg bw of cefuroxime (CE) only.

### **Assay of biochemical parameters**

Assay of alanine amino transferase activity was conducted using the method of Wroblewbki and Ladue, (1956)[9]. Assay of aspartate amino transferase was conducted according to the method of Karmen *et al*, (1955)[10]. Assay of alkaline phosphate activity was conducted according to method of Tietz (1983)[11]. Estimation of total bilirubin (TB) concentration was carried out according to the method of Jendrassik and Grof, 1938 [12]. Determination of serum urea concentration was carried out according to the method of Tobacco *et al.*, (1979)[13]. Determination of serum creatinine concentration was carried out according to the method of Narayanan and Appleton,

(1980)[14].

### Histopathological studies

Tissue processing for histological studies: Sections from the liver was passed through the processes of fixation, dehydration, clearing, infiltration, embedding, sectioning and staining. Photomicrographs: The photomicrographs were taken with a digital camera, Canon Powershot A520, 13 shooting modes attached to a Leitz Laborlux S Photomicroscope manufactured by Leitz Wetzlar, Germany. This was performed at the Histology Laboratory, Faculty of Basic Medical Sciences, College of Health Sciences, University of Uyo. The photomicrographs were taken by an expert histopathologist.

### Results

The result of the effect of co-administration of chloroquine and cefuroxime on liver enzyme activities is shown in Table 1. The activities of ALT and ALP were observed to be significantly decreased ( $p < 0.05$ ) in all the treated groups when compared to the control. Cefuroxime treated group showed significant elevation of AST activity while the AST activities of chloroquine treated group and the group co-administered with both drugs were significantly reduced. Furthermore, total bilirubin concentration was only elevated when the animals were treated with the individual drugs while there were no significant changes in the concentration of direct bilirubin among the treated groups when compared to the control. There were slight elevation in the urea concentration of the treated groups when compared to the control though the increase was not significant. Significant reduction in the concentration of creatinine was observed for chloroquine treated group whereas that of the other groups were significantly increased when compared to the control. The effect of co-administration of chloroquine and cefuroxime on bilirubin, urea and creatinine concentration is reported in Table 2.

### Discussion

High prevalence of malaria and typhoid fever in the tropics has made co-infections common. However, the actual and precise underlying mechanism to explain the association between malaria and salmonellosis is still uncertain [1]. The treatment of malaria and typhoid co-infection is a common phenomenon in many parts of Africa [2]. This is because malaria and typhoid fever have been associated with poverty and underdevelopment

with significant morbidity and mortality. An association between malaria and typhoid fever was first described in the medical literature in the middle of the 19<sup>th</sup> century, and was named typhomalarial fever by the United States Army [3]. It has been advocated that despite appropriate anti-malarial therapy, these patients should receive broad spectrum antibiotics. Moreover, in malaria endemic areas, children often carry falciparum malaria asymptotically, so malaria is over diagnosed at the expense of other infectious conditions. In the present study, the effects of co-administration of chloroquine (antimalaria) and cefuroxime (antibiotics) on liver enzymes, some indices of protein metabolism was investigated.

The activities of ALT, AST and ALP in the treated Wistar rats are shown on Table 1. As indicated in the literature, serum enzymes, in this case, viz; alanine amino transferase (ALT), aspartate aminotransferase (AST) and alkaline phosphatase (ALP), are present in hepatic and biliary cells [15]. These enzymes are usually released from the hepatocytes and leak into circulation causing increase in their serum concentrations under hepatocellular injury or inflammation of the biliary tract cells resulting predominantly in an elevation of the alkaline phosphate levels [15]. Serum concentrations of these enzymes are particularly high in acute hepatocellular damage caused by drug toxicity and xenobiotics. The extent of changes in the enzyme activity is related to the nature of toxin, closeness to toxic agent and duration of toxicity. Moreover increased ALT concentration is associated with reduced insulin sensitivity, adiponectin and glucose tolerance as well as increased free fatty acids and triglycerides [16]. Elevated mitochondrial AST is seen in extensive tissue necrosis during myocardial infarction and also in chronic liver disease [17]. About 80% of AST activity is contributed by mitochondrial isoenzyme, whereas most of the circulating AST activity in normal people is derived from the cytosolic isoenzyme. However, the ratio of the mAST to the total AST activity has diagnostic importance in identifying the liver cell necrotic type condition and alcoholic hepatitis. AST elevation often predominates in patients with cirrhotic and even in liver disease that typically has an increased ALT [18]. ALP levels rise with large bile duct obstruction, intra-hepatic cholestasis or infiltrative disease of the liver. The serum ALP activity is mainly from the liver with 50% contributed to bone [19].

The marked decrease in the activities of the liver enzymes observed in the present study could be attributed, in part, to the fact that clinical doses of

drugs did not cause hepatic or biliary injury. These enzymes are indisputably markers of hepatic injury, liver necrosis, and biliary tract obstruction. They are localised in the cytoplasm under normal conditions and are released into the circulation under abnormal (e.g cellular damage) conditions [20].

Bilirubin, urea and creatinine levels in treated Wistar rats are presented on Table 2. Significant increase in total bilirubin levels observed in all the groups treated with drugs may be due to intravascular haemolysis of red blood cells due to drug treatment. Chloroquine (quinine-based) when used for chemoprophylaxis, had been shown to stimulate the production of a drug-dependent complement fixing antibody capable of causing intravascular red cell lysis [21]. The concomitant significant increase in creatinine level strongly suggests impaired glomerular filtration of urea and creatinine. A rise in blood creatinine concentration is observed only with marked damage to functioning nephrons. Therefore, this test is not suitable for detecting early-stage kidney disease. A better estimation of kidney function is given by the creatinine clearance (CrCl) test. This parameter can be accurately calculated using serum creatinine concentration and some or all of the following variables: sex, age, weight, and race as suggested by the American Diabetes Association without a 24-hour urine collection [22].

In the liver section concomitantly administered with chloroquine and cefuroxime (Plate III), the section caused larger sized sinusoids with few pyknotic nuclei within the hepatocytes compared with the section treated with chloroquine only (Plate II). The liver is the most important organ in drug metabolism and therefore very sensitive to any chemical or its metabolite(s) introduced into the body. Results from biochemical analyses and histological studies have thus revealed that the administration of chloroquine together with cefuroxime in albino Wistar rats appeared to have a modulatory effect compared to administering the drugs separately. This modulatory effect might be as a result of drug interaction which may have nullified the toxic effects of the individual drugs.

## References

1. Uneke, C.J. Concurrent Malaria and Typhoid Fever in the Tropics: The Diagnostic Challenges and Public Health Implications. *J Vector Borne Dis.* 2008;45:133–142.
2. Oguche, S., Omokhodion, S.I., Adeyemo, A.A. and Olumeses, P.E. (2002). Low Plasma Bicarbonate Predicts Poor Outcome of Cerebral Malaria in Nigeria Children. *W Afr J Med*, 2001;21(4):45–46.
3. Smith, D. C. The Rise and Fall of Typhomalarial fever in: *Origins. J Histo Medi Alli Sci.* 1982;37:182–220
4. Khan, M.A., Mekan, S.F., Abbas, Z. et al., Concurrent Malaria and Enteric Fever in Pakistan. *Singap Medi J* 2005;46:635–638.
5. Ammah, A., Nkujo-Akenji, T., Ndip, R., et al., An Update on Concurrent Malaria and Typhoid Fever in Cameroon. *Trans Royal Soc Trop Med Hyg* 1999;2:127–129.
6. Mabey, D.C., Brown, A. and Greenwood, B.M. Plasmodium falciparum Malaria and Salmonella Infections in Gambian Children. *J Infect Dis* 1987;155:1319–1321.
7. Wink, M. Functions of Plant Secondary Metabolites and their Exploitation in Biotechnology. *Annual Plant Reviews.* Vol 3. Sheffield: Sheffield Academic Press Limited. 1999; p. 370.
8. Adekunle, A.S., Adekunle, O.C. and Ehbewale, B.E. Serum Status of Selected Biochemical Parameters in Malaria: An animal model. *Biomed Res.* 2007;18(2):109–111.
9. Wroblewski, F. and LaDue, J. S. (1956). Transaminase Activity in Liver Disease. *Proc Soc Experim Bio Med.* 1956;91:569.
10. Karmen, A., Wroblewski, E. and Ladue, J. Transaminase Activity in Human Blood. *J Clinl Investigat* 1955;34(1): 126 – 131.
11. Tietz, N.W. Study Group on Alkaline Phosphatase. A Reference Method for Measurement of Alkaline Phosphatase Activity in Human Serum. *Clin Chem* 1983;29:751.
12. Jendrassik, L. and Grof, P. Colorimetric Method of Determination of Bilirubin. *Biochem* 1938;297:81–82.
13. Tobacco, A., Meiatini, F., Moda, E. et al., Simplified Enzymatic/Colorimetric Serum Urea Nitrogen Determination. *Clin Chem.* 1979;25:336.
14. Narayanan, S., Appleton and H. D. Creatinine: A Review. *Clin Chem* 1980;26:1119–1126.
15. Jensen, J.E., Stainberg, S.E., Freese, P. and Marino, E., Liver Function Test. *J Digest Disord.* 2004;6:1–3
16. James, D., Tania, S.B., Sara, E.T. Alanine Aminotransferase Levels and Fatty Liver in Childhood Obesity: Associations with Insulin Resistance, Adiponectin, and Visceral Fat. *J Clin Endocrino Metab* 2006;91:4287–4294.
17. Thapa, B.R. and Anuj, W. Liver Function Tests and their Interpretation. *Ind J Pediat* 2007;74:663–671.
18. AGA. Technical Review on the Evaluation of Liver Chemistry Tests. *Gastroenterology* 2002;123:1367–1384.
19. Mauro, P., Renze, B., Wouter, W. In: *Tietz Text Book of Clinical Chemistry and Molecular Diagnostics.* 4<sup>th</sup> ed, Carl, A.B., Edward, R., David, E.B. Editors. Elsevier. 2006;604–616.
20. Mourelle, M., Ameziua, J.L., Hong, E. Effects of Riprostil and Colchicines on Carbon Tetrachloride Acute Liver Damage in Rat. Relationship with Plasma Membrane Lipids. *Prostaglandins*, 1987;33:869–877.
21. Gross, J.L., de Azevedo, M.J., Silveiro, S.P., et al., Diabetic Nephropathy: Diagnosis, Prevention, and Treatment. *Diabe Care.* 2005;28(1):164–76.
22. Weatherall, D.J., Miller, L.H., Baruch, D.I., et al., Malaria and the Red Cell. In: *Hematology.* American Society of Hematology Education Program Book. 2002;1–45.



**Table 1.** Activity of Serum ALT, AST, ALP of albino Wistar rats co-administered

Treatment	ALT (U/L)	AST(U/L)	ALP(U/L)
CTR	28.82±1.65	68.22±4.52	115.00±9.54
CQ	17.33±1.64*	61.22±8.39**	95.79±7.85**
CQ+CE	17.24±1.78*	54.51±4.92*	52.49±4.39*
CE	17.53±1.01*	69.98±3.72**	59.05±3.01*

CQ = chloroquine, CE = cefuroxime

\* significantly different from control (CTR) (P <0.05), \*\* Significantly different within group, number of rats (n) = 6.

**Table 2.** Effects the of co-administration of 4.17 mg/kg bw of CQ and 8.33 mg/kg bw of CE on bilirubin, urea and creatinine concentrations in albino Wistar rats

Treatment	TB (μmol/L)	DB(μmol/L)	UREA (mg/dL)	CREATININE (mg/dL)
CTR	0.02±0.02	0.02±0.00	1.95±0.11	10.37±1.49
CQ	0.03±0.01*	0.02±0.01	2.15±0.18	6.81±1.52*
CQ+CE	0.02±0.00*	0.02±0.04	2.26±0.12	15.87±0.52*
CE	0.03±0.00*	0.029±0.00	2.35±0.27	20.17±0.97**

CQ = chloroquine, CE = cefuroxime

\* significantly different from control (CTR) (P <0.05), \*\* Significantly different within group, number of rats (n) = 6.

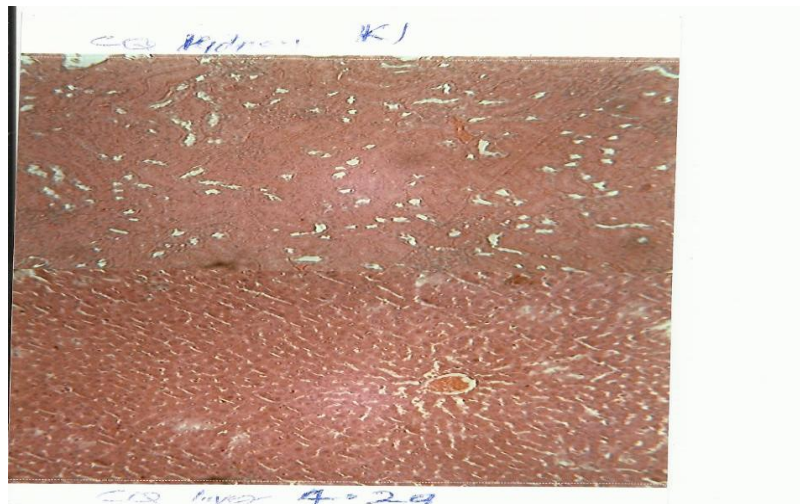


Figure 1. Photomicrograph of a section of a typical normal rat liver (mag x 16) of control animal showing normal liver cells. The hepatocytes are arranged in clumps and separated from each other by sinusoids. The nuclei are prominent and rounded. The entire liver parenchyma showed no obvious pathology.

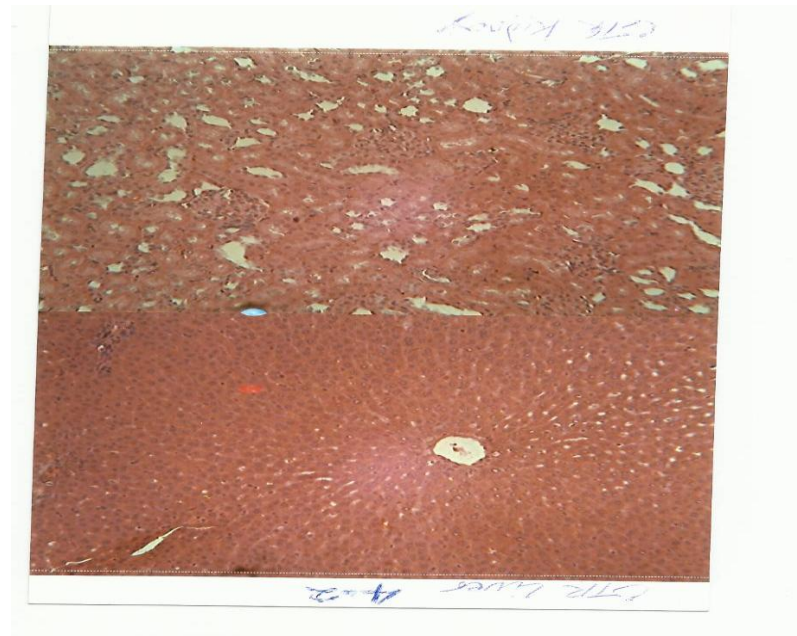


Figure 2. Photomicrograph of a liver section (mag x16) of chloroquine (4.17mg/kg bw) treated Wistar albino rats showing enlarged sinusoids, less prominent nuclei. Nuclei also appear pyknotic. The parenchyma appears normal.



Figure 3. Photomicrograph of a liver section (mag x16) of albino Wistar rats treated with 4.17 mg/kg bw chloroquine and 8.33 mg/kg bw of cefuroxime showing larger size sinusoids, few pyknotic nuclei which appear small in size.

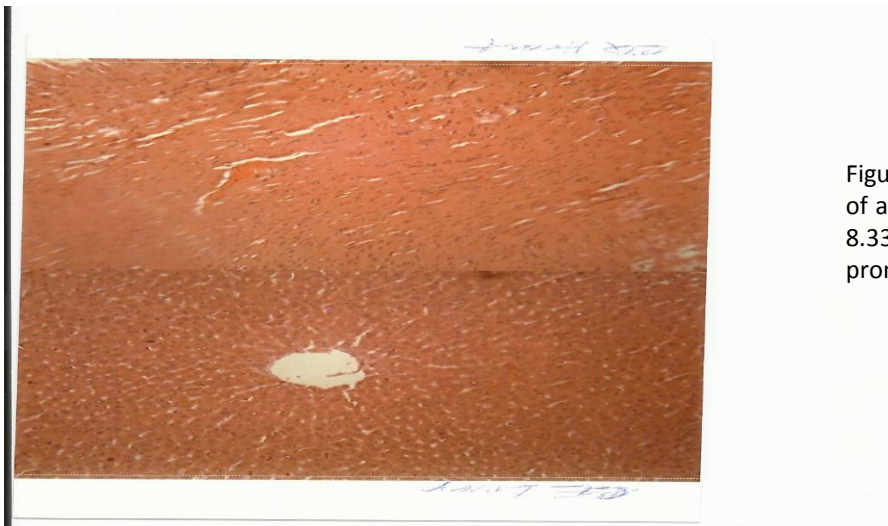


Figure 4. Photomicrograph of a liver section of albino Wistar rat (mag x16) treated with 8.33 mg/kg bw cefuroxime. Sinusoids are prominent. Some pyknotic nuclei are seen.