

**WOUND HEALING ACTIVITY OF THE LEAVES OF
DIPTERACANTHUS PATULUS (JACQ.) NEES.**

K.Saroja^a, J.Dulcy Elizabeth^b and S.Gopalakrishnan*

*Department of Pharmaceutical Chemistry, Manonmaniam Sundaranar University,
Tirunelveli-627 012, Tamil Nadu, India.

^aDepartment of Botany, Sri Parasakthi College for Women (Autonomous),
Courtallam-627 802, Tamil Nadu, India.

^bDepartment of Botany, St. Mary's College, Tuticorin-628 001, Tamil Nadu, India.

Corresponding author: E-mail: sgkmsu@yahoo.co.in

Summary

The methanolic extract of the leaves of *Dipteracanthus patulus* (Jacq.) Nees was investigated for its wound healing activity in excision and dead space wound models. The extract significantly increased the rate of wound contraction, weight of granulation tissue, tensile strength and collagen formation when compared with the control.

Keywords: *Dipteracanthus patulus*, wound healing, excision wound model, dead space wound model

Introduction

Wounds are physical injuries that result in an opening or break of the skin. Proper healing of wounds is essential for the restoration of disrupted anatomical continuity and disturbed functional status of the skin. Current estimates indicate that nearly 6 million people suffer from chronic wounds worldwide. Community based epidemiological study of wounds in India revealed the prevalence of acute and chronic wounds as 10.55 and 4.48 per 1000 population respectively (1). Healing of chronic lower extremity wounds is a global problem (2). Research on wound healing agents is one of the developing areas in modern biomedical sciences. Many traditional practitioners across the world particularly in countries like India and China with age old traditional practices have valuable information of many lesser-known hither to unknown wild plants used for treating wounds and burns. Some of these plants have been screened scientifically for the evaluation of their wound healing activity in different pharmacological models but the potential of most of the plants remain unexplored (3).

Dipteracanthus patulus (Jacq.) Nees. (Syn. *Ruellia patula* Jacq). (Acanthaceae) commonly known as Kiranthinayagam or Kayappacchilai in Tamil is a medicinal herb traditionally used in the treatment of. wounds in the rural areas. The leaves are ground into a paste and applied on fresh wounds. The plant is commonly distributed on wastelands in Tamil Nadu. The leaves are used for treating itches, insect bites, paronychia, venereal diseases, sores, tumours, rheumatic complaints and eye diseases (4-6). Pharmacological and phytochemical studies indicated that it is a cardiogenic (7) and it contained two lignan glycosides namely 5, 5'-dimethoxy-lariciresinol-9-O- β -D-glucopyranoside and lyoniresinol-9-O- β -D-glucopyranoside (8). The wound healing properties of the leaves of *Dipteracanthus patulus* has not been scientifically evaluated so far. Hence the present study was undertaken to evaluate the wound healing activity of the leaves of *Dipteracanthus patulus*.

Materials and methods

Preparation of plant extract: Leaves of *Dipteracanthus patulus* were collected from Courtallam region, Tamil Nadu, India. The plants were identified and the voucher specimen (SMCH-3009) of the plant is deposited in the Department of Botany, St. Mary's College, Tuticorin, Tamil Nadu. The leaves were dried in shade and powdered.

The leaf powder (1Kg) was subjected to hot extraction with solvents of increasing polarity starting from Petroleum ether (40-60 °C), Benzene, Chloroform and Methanol. The methanolic extract was concentrated under reduced pressure in a rotary evaporator (Buchi, USA). Preliminary qualitative phytochemical analysis of the methanolic extract was carried out (9). The methanolic extract showed the presence of flavonoids, phenols, saponins, steroids and tannins. The methanolic extract was used for evaluating wound healing activity. Extract was incorporated into a simple ointment base BP. Two formulations of extract ointment 5% (w/w) and 10% (w/w) were prepared by incorporating 5g and 10g of extract in 100g of simple ointment base BP, respectively.

Animals: Wistar albino rats weighing (150-200g) were used. Animals were fed with standard diet and water *ad libitum* and maintained under standard laboratory conditions. Ethical clearance for the animal study was obtained (IAEC-265/CPCSEA).

Wound healing activity: Excision and dead space wound models were used to evaluate the wound healing activity of the methanolic extract of leaves of *Dipteracanthus patulus*.

Excision wound model: Excision wound was inflicted by cutting away approximately 500 mm², full thickness of skin from the depilated area on the back under light ether anaesthesia and were placed in their individual cages. The animals were divided into four groups (n=6). Group 1 was the control group that received simple ointment base, group 2 was treated with reference standard (0.2 % w/w nitrofurazone ointment), group 3 received 5% (w/w) extract ointment and group 4 received 10% (w/w) extract ointment. The ointments (0.5g each) were applied topically with a fine brush once daily till the wound was completely healed. Wound contraction rate was monitored by planimetric measurement of the wound by tracing the wound margin on a graph paper every alternate day (10). Wound contraction was calculated as percentage of original wound size.

Dead space wound model: Three groups of rats (n=6) were used. Dead space wounds were made by implanting subcutaneously a polypropylene tube (2.5 x 0.5 cm) beneath the dorsal paravertebral lumbar skin. Group 1 was the control group that received 2 ml of 1% carboxymethyl cellulose, group 2 received extract (100 mg /kg) and group 3 received extract (200 mg/kg) orally, once daily for 10 days. On the 11th day, the granulation tissue formed on the implanted tubes was dissected out carefully. The wet weight of the granulation tissue was noted. Tensile strength of the granulation tissue was measured by the method of Lee (11).

The granulation tissue was dried in an oven at 60°C for 12 hours and the dry weight was recorded. Histopathological studies of granulation tissue were done by staining with haemotoxylin and eosin so as to enable the assessment of fibroblast population and collagen content under a light microscope.

Statistical analysis: Data are expressed as mean \pm SE and subjected to Student's t test by comparing with the control.

Results

In the excision wound model, wound contraction progressed faster in extract ointment treatment, when compared to control and standard drug. Significant increase in the rate of wound contraction has been observed on day 16 (98.49 %, $P < 0.001$) on the 10% extract treated animals. On 18th day of post wounding, 100% wound closure was observed in 10% (w/w) extract ointment treated animals whereas in 5 % (w/w) extract ointment treated animals and in nitrofurazone ointment treated animals 100% wound closure was observed on 20th day of post wounding (Table 1 and Figure 1).

In dead space wound model, significant increase in the weight of the granulation tissue and its tensile strength were observed in the animals treated with leaf extract (Table 2). The histological profiles of the granulation tissue of extract treated animals showed increased collagen formation when compared to control (Figure 2)

Table 1: Effect of leaf extract of *Dipteracanthus patulus* on wound contraction in Excision model

Post wounding days	Wound Area (mm ²) and percentage of wound contraction			
	Simple ointment (control)	Nitrofurazone ointment (0.2%)	Extract ointment (5% w/w)	Extract ointment (10% w/w)
0	522± 36.8 (0.0%)	518±25.9 (0.0%)	528±31.6 (0.0%)	533±35.2 (0.00%)
2	507±28.2 (2.87%)	473±37.1 (8.68%)	461±21.3 (12.68%)	412±29.6 (22.70%)
4	480±23.6 (8.04%)	341±32.5* (34.16%)	341±19.6 (35.41%)	339±23.9* (36.91%)
6	421±19.2 (19.34%)	72±20.8* (47.49%)	269±17.2* (49.05%)	212±16.2** (60.22%)
8	379±17.4 (27.3%)	181±16.2** (65.05%)	200±13.8** (62.12%)	107±12.5** (79.92%)
10	315±13.7 (39.65%)	118±9.4** (77.22%)	112± 9.2** (78.78%)	56±9.8** (89.49%)
12	281±11.3 (46.16%)	69±5.1** (86.67%)	75± 5.9** (85.79%)	36±8.9** (93.24%)
14	242±10.5 (53.63%)	48±3.7** (90.73%)	57± 4.7** (89.20%)	19±4.7** (96.43%)
16	201±9.7 (61.49%)	37± 2.6** (92.85%)	41±3.5** (92.23%)	8±1.4** (98.49%)
18	156±7.4 (70.11%)	11±1.2** (97.87%)	15±1.1** (97.15%)	0.0±00** (100%)
20	128±9.4 (75.47%)	0.0±00** (100%)	0.0±00** (100%)	0.0± 00** (100%)

Data are expressed as mean ±SE; n = 6.

P values versus respective control by student's t-test.

* P< 0.01, ** P< 0.001

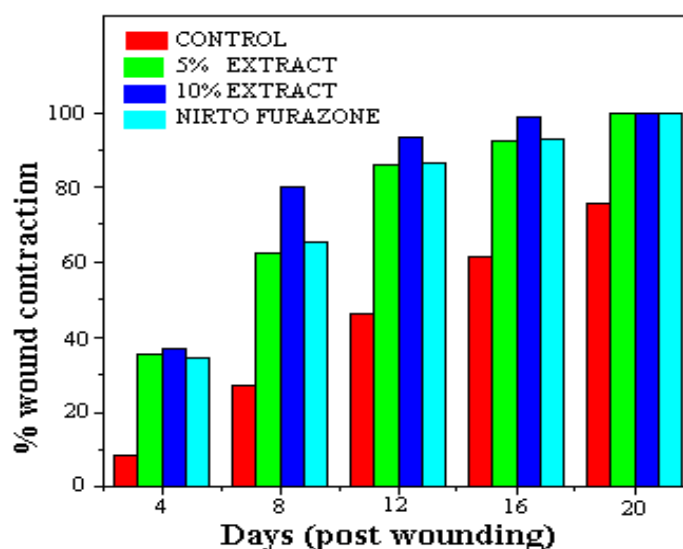


Figure 1. Effect of leaf extract on wound contraction

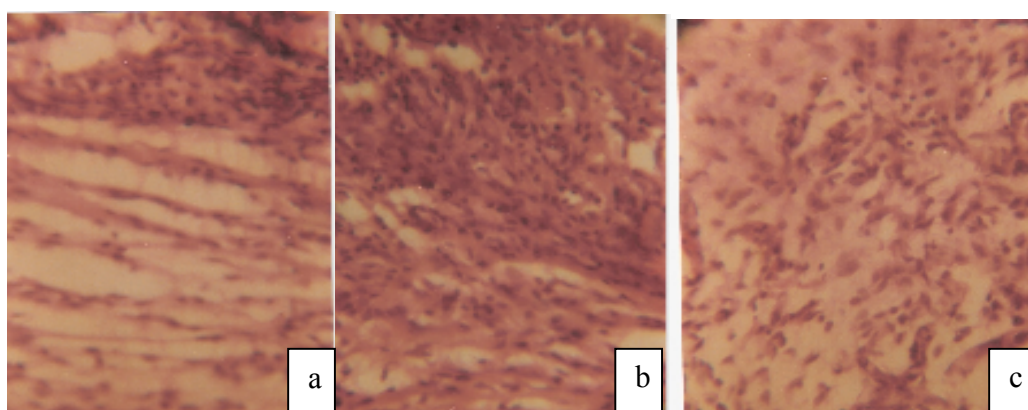


Figure 2. Comparative histopathological study of control and treated group (a) 100 mg/Kg, (b) 200 mg/Kg extract treated groups show increase in collagen deposition in comparison of (c) control group.

Table 2: Effect of leaf extract of *Dipteracanthus patulus* in dead space wound model

Treatment	Wet weight of granulation tissue (mg)	Dry weight of granulation tissue (mg)	Tensile strength (g)
Control (1% CMC, 2ml, P.O)	223.73±13.6	32.8±2.4	328±21.6
Extract (100 mg/kg, P.O)	442.6±27.3*	83.2±7.3*	537.3±41.5*
Extract (20 mg/kg, P.O)	505.8±39.2*	112.6±9.5*	626±47.4*

Data are expressed as mean ±SE, n = 6; * P < 0.001 Vs control by student's t test

Discussion

Wound healing is a process by which a damaged tissue is restored as closely as possible to its normal state. Wound healing involves different phases such as contraction, epithelization, granulation and collagenation. Dead space wound provides an opportunity to study the effect on granulation and collagenation of the healing process (12). In the present study, the methanolic extract has promoted wound healing activity by increasing cellular proliferation and formation of granulation tissue. The granulation tissue of the wound is primarily composed of fibroblast, collagen and new blood vessels. Increase in granulation tissue weight in the extract treated animals suggests increase in collagen synthesis (13). The collagen is the major component of extracellular tissue which gives support and strength. The undifferentiated mesenchymal cells of the wound margin modulate themselves into fibroblast, which start migrating into the wound gap along with the fibrin strands. In the present study increase in the rate of wound contraction in extract treated groups may be due to the enhanced activity of fibroblasts. Lignan glycosides namely, 5, 5'-dimethoxy-lariciresinol-9-O- β -D-glucopyranoside and Iyoniresinol-9-O- β -D-glucopyranoside were isolated from the methanol extract of the entire plant of *Dipteracanthus patulus* (8). The lignans, lignan glycosides and triterpenoids isolated from *Alocasia odora* showed a stimulation of cell proliferation thus contributing to wound healing activity of that plant (14). The wound healing potential of the methanolic extract of the leaves of *Dipteracanthus patulus* may be attributed to the phytochemical constituents such as flavonoids, saponins, steroids, phenols, tannins and lignan glycosides present in it. Pharmacological activity of many herbal medicines may often be the result of many secondary metabolites acting synergistically (15). This study provides the scientific basis to the traditional uses of *Dipteracanthus patulus* for wound healing. This herb is a promising wound healing promoter worthy of further studies and clinical evaluation.

Acknowledgements

One of the authors (K.S.) wishes to thank the Management, Sri Parasakthi College for Women (Autonomous), Courtallam-627 802, Tamil Nadu and University Grants Commission, New Delhi for financial assistance under Faculty Improvement Programme during the Tenth Plan period and Dr.A.Jaswanth, Department of Pharmacology, Periyar College of Pharmacy, Trichy for providing facilities to carryout this work

References

1. Gupta N, Gupta SK, Shukla VK, Singh SP. An Indian community based epidemiological study of wounds. *Journal of Wound Care* 2004; 13:323-325.
2. Ryan TJ. Use of herbal medicines in wound healing: A perspective paper. *The Int. J Low Extrem Wounds* 2003; 2:22-24.
3. Kumar B, Vijayakumar M, Govindarajan R, Pushpangadan. Ethnopharmacological approaches to wound healing-Exploring medicinal plants of India. *J Ethnopharmacol* 2007; 114:103-113.
4. Murugesu Mudaliar KC. *Materia Medica (Vegetable Section), Part 1, 6th Edition (Commentary), (in Tamil) Directorate of Siddha System of Medicine, Madras, 1988; 361.*
5. Singh VK, Khan A.M. Medicinal plants and folklores. In: *Glimpses in plant research vol.1x. Today and Tomorrows printers and publishers, New Delhi, 1990; 250.*
6. Tirugnanam S. *Herbal medicines, Selvi Publishers, Trichy, 2003; 278.*
7. Akhtar MF, Rashid S, Ahmad M. Cardiovascular evaluation of *Ruellia patula* and *Ruellia brittoniana*. *Journal of Islamic Academy of Sciences*. 1992; 5: 67-71.
8. Ahmad M, Akhtar MF, Miyase T, Rashid S, Usmanghani K. Studies on the medicinal herb *Ruellia patula*. *Int J Pharmacog* 1993; 31:121-127.
9. Brindha P, Sasikala B, Purushothaman KK. Pharmacognostical studies in Merugan Kizhangu. *B.M.E.B.R.* 1981; 3: 84-86.
10. Udupa SL, Udupa AL, Kulkarni DR. Anti-inflammatory and wound healing properties of *Aloe vera*. *Fitoterapia*. 1994; 65:144-145.
11. Lee KH. Studies on mechanism of action of salicylates II Retardation of wound healing by aspirin. *J Pharm Sci* 1968; 57: 1042-1043.
12. Mathew A, Taranalli AD, Torgal SS. Evaluation of anti-inflammatory and wound healing activity of *Gentiana lutea* rhizome extracts in animals *Pharmaceut Biol* 2004; 42:8-12.
13. Nayak, BS, Sandiford S, Maxwell A, Evaluation of the wound-healing activity of ethanolic extract of *Morinda citrifolia* L. Leaf. *Evid. Based Complement Altern Med* 2007; doi:10.1093/ecam/nem 127.
14. Viet D, Houghton PJ, Forbes B, Corcoran O, Hylands PJ. Wound healing activity of *Alocasia odora* (Roxb.) koch. *Planta Med* 2006; 72:991.
15. Scott G, Springfield EP, Coldrey N. A Pharmacognostical Study of 26 South African Plant Species used as Traditional Medicines. *Pharmaceut Biol* 2004; 42: 186-213.