

**EFFECT OF DAPSONE ON WOUND HEALING.**

**K. CHANDRASHEKAR , A.P.HOGADE, S.V.HIREMATH, MALUR P R**

1 Department of Pharmacology, J.N. Medical College, Belgaum, India

2Department of Pathology, J.N.Medical College, Belgaum, India

**Summary**

Drugs like dapsone which have been used in treatment of leprosy reported to promote the wound healing may have the same effect on cutaneous wounds. Due to paucity of information in this regard, the present study was planned to investigate the effect of these drug on resutured incision, excision and dead space wounds in Wistar rats. Resutured incision, excision and dead space wounds were inflicted under light ether anaesthesia aseptically. Control animals received vehicle and other groups received dapsone orally for a period of 10 days in the incision and dead space wounds, whereas in excision wounds till complete closure. On the 11th day after estimating breaking strength of the resutured incision wounds, animals were sacrificed and granulation tissue removed from dead space wounds to estimate the breaking strength and hydroxyproline content. Quantification of granulation tissue and histological studies were also carried out. Wound closure rate, epithelization time and scar features were studied in the excision wound models from the day of dapsone till complete closure of the wound. Dapsone significantly promoted the healing process in all the three wound models studied. Histopathological studies revealed increased collagen content and granulation tissue in Dapsone treated group compared to control.

**Key words:** Dead space wound, excision wounds, healing, incision ,dapsone .

**Corresponding author:**

Dr .K.Chandrashekar

Assistant Professor

Department of Pharmacology, J.N.Medical College, Nehru Nagar, Belgaum

590010. E-Mail :chandrashekhar.shetty@yahoo.co.in

### **Introduction**

Wound being one of the common clinical entities, often challenges the clinicians when associated with infection like infection like leprosy . leprosy is chronic disease caused by mycobacterium leprae .the planter ulceration is probably the most frequent complication of leprosy these patients receives WHO recommended multi drug therapy which includes rifampicin ,clofazamine and dapsone.<sup>1</sup> the drug dapsone do posses anti inflammatory and immune suppressant activity<sup>2</sup> based on above reported additional pharmacological action they can expected to have influence on wound healing .the available experiment data provide a conflicting report regarding the influence dapsone on wound healing therefore the present study was planned to investigate the influence of dapsone on three different wound models viz. Excision ,resutured incision and dead space wound in wistar rats .

### **Materials and Methods**

**Animals and drug treatment:** Healthy male Wistar rats weighing 175±250 g, were housed individually acclimatized to laboratory for a week under 12;12 light dark cycle. The animals were fed on standard pellet diet (Amrut brand) and water *ad lib*, where as they were starved over night before the day of experimentation with free access to water. The study was approved by the Institutional Animal Ethics Committee constituted as per CPCSEA guidelines. Depilation at wounding site was done a day before wounding.

**Wound models:** Resutured incision wounds were inflicted with two 6cm long para vertebral parallel incisions under light ether anaesthesia as described by Erlich and Hunt.<sup>3</sup> Sutures were removed on the 7th day; breaking strength was measured on the 10th post wound day, by the continuous water flow technique as described by Lee.<sup>4</sup> Excision wounds were inflicted as described by the method of Morton and Malone,<sup>5</sup> by excising the full thickness circular skin (approximately 500 mm<sup>2</sup>) from the nape of neck under ether anesthesia.

Wound closure rate and epithelization time were assessed by tracing the wound on polythene paper from wounding day, followed by 4, 8, 12, 16, 18, 20th day and subsequently on alternate days till complete epithelization (fall of scab without only raw area). Similarly scars were traced on complete epithelization to assess wound contraction by noting scar size and shape. Dead space wounds were inflicted by implanting sterile cotton pellets (10 mg) and cylindrical grass piths (2.5 cm X 0.3 cm) *s.c.* in the groin and axilla alternatively by the technique of D'Arcy *et*

al as described by Turner.<sup>6</sup> on the 10th post-wounding day, all the granulation tissues were removed under light ether anesthesia.

Cotton pellet granulomas were dried at 60 °C overnight to record the dry weight which was expressed as mg/ 100g body weight as suggested by Dipasuale and Moli.<sup>7</sup> One of the granulation tissues over the grass piths was opened and trimmed to a rectangular piece for estimation of breaking strength, whereas the other piece was preserved in 10% formalin for histological studies. .

All the wounding procedures carried out aseptically and none of the animals received local or systemic antimicrobials.

After wounding, the animals were divided into control and treatment groups (n=6, ineach) for each wound model to receive treatments. The drugs were administered orally in their therapeutic equivalent doses as calculated with the help of conversion table devised by Pagets and Barnes.<sup>8</sup> the dose of dapsone (100mg), were suspended in 2% gum acacia and were administered once daily in the volume of 5ml/kg, while control groups received equal volume of the vehicle. The duration of the treatment was 10 days for animals inflicted with incision and dead space wounds, whereas it was continued in animals bearing excision wounds till their complete course.

**Statistical analysis:** The results were analysed by ANOVA followed by post hoc Dunnet's test and expressed as mean±SEM. p<0.05 was considered as significant.

## **Results**

### ***Resutured incision wounds:***

The mean breaking strength of wounds in control animals were 288.6 ± 8.449g while metformin (p<0.001) and acarbose (p<0.01) showed significant increase in breaking strength

### ***Resutured incision wounds:***

The mean breaking strength of wounds in control animals was 187,1± 8.670g while Dapsone (p<0.001) showed significant increase in breaking strength 410.0 ± 14.71g, 282.0 ± 8.307 respectively.

### ***Dead space wounds:***

Mean dry weight of granuloma in control animals was 32.28 ± 1.27mg, and 47.72 ± 4.55mg in dapsone treated groups respectively. There was significant (p<0.001) increase in the granuloma dry weight of dapsone treated group. Breaking strength

of the granuloma in the control group was  $210.0 \pm 11.55g$ , while dapsons, treated groups it was  $246.7 \pm 10.309g$ , . respectively, indicating significant ( $p < 0.001$ ) increase in granuloma breaking of dapsons group. Hydroxyproline content of 300 mg of granulation tissue was estimated and expressed as  $\mu g/300$  gm of granulation tissue. It was significantly increased in the dapsons ( $p < 0.001$ ) and treated group with a mean value of  $10.17 \pm 0.307$  mcg and respectively as compared to the control group with a value of  $5.500 \pm 0.428$  mcg.

**Excision wounds:**

The rate of wound closure in dapsons treated animals was significantly ( $p < 0.01$ ) respectively more on 4th, 12th, 16th, day as compared to that of control. However, there was no significant change in rate of wound closure in control animals. The time for complete epithelization (days) in control group was  $19.8300 \pm 0.447$ . In comparison to this, dapsons  $16.67 \pm 0.210$  treated group took significantly ( $p < 0.001$ ,  $p < 0.05$ ) less time for complete epithelisation. The mean scar area ( $mm^2$ ) in the control group was  $41.83 \pm 4.97$ . Dapsons  $34.10 \pm 1.893$  significantly ( $p < 0.01$ ) reduced the scar area (Table 2). Scar were stellate shape in dapsons group while in control treated groups were oval or oblong. Significant reduced scar area in dapsons group indicates maximum contraction of wound as compared to control groups.

Hydroxyproline content of 300 mg of granulation tissue was estimated and expressed as  $\mu g/300$  gm of granulation tissue. It was significantly increased in the dapsons ( $p < 0.001$ ) and treated group with a mean value of  $10.38 \pm 0.307$  mcg as compared to the control group with a value of  $5.917 \pm 0.428$  mcg.

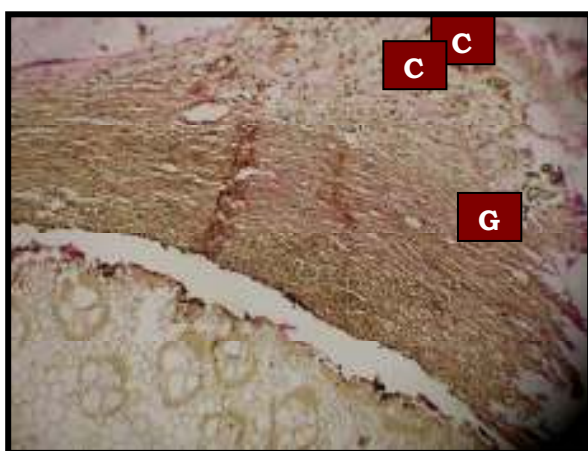
**Table 1. Effect of various healing agents on resutured incision and dead space wounds**

groups	Resutured wound breaking strength	Breaking strength	Dry weight	Hydroxyproline(micro gram per 300mg of wet granulation tissue
Control	187.1	203.3	32.28	5.917
dapsons	282.3	246.7	47.74	10.38


Groups	4	8	12	16	18	Complete closure	Sacar area
control	19.07	53.57	81.28	88.88	94.97	19.83	41.83
Dapsone	34.22	56.42	94.58	99.43	100	16.67	34.17

**Table 2. Effect of various healing agents on excision wounds**

**CONTROL**



**DAPSONE**



**NOTE : MARKED INCREASE IN  
GRANULATION TISSUE AND  
COLLAGEN IN DAPSONE  
TREATED GROUP**

### **Discussion**

The main objective of this study is to evaluate the influence of dapsone on healing of excision, resutured incision and dead space wounds in male Wistar rats. The findings of the present study excision wound model clearly indicated that the dapsone drug treated groups significantly enhanced wound healing as assessed by wound closure rate, time taken for complete epithelization and reduction in scar size. In resutured incision wound model dapsone treated groups significantly increased the strength required to break 10 day old resutured incision wound, compared to control group.

In dead space wound studies dapsone treated groups significantly increased the granuloma dry weight, granuloma breaking strength and collagen content as indicated by hydroxyproline estimation. The histopathological findings of dapsone treated group showed marked increase in granulation tissue and onset of collagen when compared to control group. Neutrophils that are recruited at sites of inflammation generate superoxide anion which rapidly dismutates to hydrogen peroxide<sup>9</sup>.  $H_2O_2$  is then transformed into hypochlorous acid by neutrophil myeloperoxidase. As a consequence of its extremely high reactivity, HOCl represents the most toxic and most potent oxidant generated by neutrophils, with potentials to cause considerable tissue damage<sup>10</sup>. Dapsone reversibly inhibits myeloperoxidase activity by promoting the formation of an inactive intermediate of the enzyme, thus preventing the conversion of hydrogen peroxide to hypochlorous acid<sup>11</sup>, an extremely potent neutrophil oxidant. generated by neutrophils, with potential cause considerable tissue damage in many inflammatory diseases. Dapsone stabilizes neutrophil lysosomes<sup>12</sup>. Significantly decreased area and stellate shape of the scar in the dapsone treated group probably suggest that enhanced healing is due to wound contraction rather than enhanced epithelization. The prohealing effect of dapsone was confirmed by increased granuloma formation (dry weight) and its rich collagen content (hydroxyproline content) which was further corroborated by histopathological study of the granulation tissue. The prohealing effect of dapsone in resutured incision wounds and dead space wounds could be explained on the basis of its other reported actions as mentioned earlier. The findings of the present study appear to have clinical relevance, if they could be extrapolated to humans.

### **Conclusion**

The findings of the present experimental study appear to be clinically relevant since such drugs are likely to be used chronically in leprosy patients who are prone for injury. Though rifampicin is commonly used as an anti-leprotic drug, dapsone could be the drug of choice for multi bacillary leprosy, to exploit its prohealing activity.

### **Acknowledgement**

The authors are grateful to the Principal, J. N. Medical College, Belgaum for providing facilities.

Thanks to Mr. A. V. Karvekar and Mr. M. D. Kankanwadi for their skilful assistance.

### **References**

1. Robert H.G,Harrison . principles of internal medicine .17<sup>th</sup> ed New York .Mc Graw Hill :2008
2. Agnithori N, Ganguly NK, Kaur S. Role of reactive oxygen species in renal damage in experimental leprosy . *Lepr Rew* 1995 :66(3):201-2.
3. Ehrlich HP, Hunt TK. Effect of Vit A and glucocorticoids on inflammation and collagen synthesis. *Ann Surg.* 1973; 222:119-126.
4. Lee KH. Studies on mechanism of action of salicylates. *J Phar Sci.* 1968; 57:1042-1043.
5. Mortan JJP, Malone MH. Evaluation of vulnary activity by an open wound procedure inrats. *Arch Int Pharmacodyn.* 1972; 196:117-126.
6. D'Arcy PF, Howard EM, Muggleton PW, Townsend SB. The anti-inflammatory action of griseofulvin in experimental animals. *J Pharm Pharmacol* 1960; 12 : 659-65.
7. Di pasquale G, Meli A. Effect of body weight changes on the formation of cotton pelletinduced granuloma. *J Pharm Pharmacol* 1965; 17 : 379-82.
8. Pagets GE, Barnes JM. Toxicity tests. In : Laurence DR Bacharach AL, editors. *Evaluation of drug activities: pharmacometrics.* London and New York: Academic Press;1964 p. 134-66.
9. Barranco V .Inhibition of lysosomal enzymes by dapsone .*arch dermatol* 1974: 110:563-566.
10. Bozeman P , Learn D , Thomas E. Inhibition of the human leukocyte enzymes myeloperoxidase and eosinophil peroxidase .*J Immunol Methods* 1990 :126 125-133.
11. Stendahl O, Molin , Lindroth M, Granulocyte – mediated release of histamine from mast cells .effect of myeloperoxidase and its inhibition by anti inflammatory sulfone comounds .*Int Arch Allergy Appl Immunol* 1983: 70:2777-284.
12. Kettle A, Gedye C, Winterbourn C . superoxidase is an antagonist of anti inflammatory drugs that inhibit hypochlorous acid production by myeloproxidase . *Biochem pharmacol* 1993: 45:2003-2010.
13. Kettle A, Winterbourn C .Mechanism of inhibition of myeloperoxidase by anti inflammatory drugs . *Biochem pharmacol* 1991:41:1485-1492.