

**STUDY OF GALACTOMANNAN ON ANDROGENIC AND ANABOLIC
ACTIVITY IN MALE RATS**

Urmila Aswar¹, V. Mohan², S. Bhaskaran², S. L. Bodhankar^{1,*}

¹Department of Pharmacology, Bharati Vidyapeeth University, Erandawane, Paud road, Pune-38, Maharashtra, India

² Indus Biotech. Pvt Limited, Gurunanak Nagar, Shankarsheth road. Pune-26, Maharashtra, India.

Summary

Galactomannan was isolated from *Trigonella foenum graceum* Linn Family: Leguminosae (TF) seeds. The objective was to study the anabolic and androgenic activity of galactomannan in immature castrated male rats and also on testicular histology in non-castrated immature rats. The rats (55± 5 g) were castrated. The rats were treated with either vehicle, testosterone (10 mg/kg s.c. bi weekly) or galactomannan (10 and 35 mg/kg p.o.) once daily for 4 weeks. Body weight, weights of male reproductive organs (viz. ventral prostate, seminal vesicle and musculus levator ani) was recorded. Serum testosterone level and blood urea nitrogen- BUN were measured after 4 weeks of treatment. Galactomannan (35 mg/kg p.o) and testosterone (10 mg/kg s.c biweekly) treatment showed increase in weight of levator ani muscle and body weight. Galactomannan (10 or 35 mg/kg p.o) did not change testosterone level in castrated rats. Histopathological examination of testis was carried in immature noncastrated male Wister rats pretreated in a similar manner as above. In noncastrated rats (55±5) both galactomannan (10, 35 mg/kg p.o) and testosterone (10 mg/kg s.c. biweekly) did not alter normal architecture of testis. Galactomannan (35 mg/kg p.o.) is an anabolic compound without androgenic activity compared to anabolic and androgenic testosterone.

Keywords: Galactomannan, Castration, Testosterone, Androgenic, Anabolic

Trigonella foenum graceum Linn., Family: Leguminosae (TF) also known as Fenugreek, is an aromatic annual plant, 30-60 cm tall, found wild in Kashmir,

Punjab and the upper Gangetic plains and widely cultivated in many parts of India. Fenugreek has been used as cooking spice and flavoring agent for centuries (1). It is used as an abortifacient (2) antispasmodic, externally for abscesses, boils, galactagogue (3) appetite stimulant, blood cleansing, laxative, tonic (4) demulcent, emollient, expectorant, aphrodisiac (5) properties. The defatted seeds are rich source of steroids (6). However studies on fenugreek seeds (7) and its extract (8) have been reported to have antifertility activity in male and female rabbits. In India, traditionally fenugreek seed ground with the jaggary is given to female after childbirth to develop their muscles and strengthen them up.

Galactomannan are polysaccharides consisting of mannose backbone with galactose side groups. The galactomannan in TF seed contain galactose and mannose in the ratio 48:52. Fenugreek seed and its extract showed hypoglycemic effect on normal and diabetic model rats. The soluble dietary fiber fraction, galactomannan is shown to be responsible for hypoglycemic effect of fenugreek seeds. (9). During similar study in our laboratory we observed increase in body weight of alloxan induced diabetic rats treated with galactomannan (60 mg/kg p.o.). There is paucity of reports on the androgenic and anabolic activity of galactomannan. The objective of the study was to evaluate androgenic and anabolic activity of galactomannan.

Material and Methods

Chemicals

Testosterone (Himedia Laboratories, Mumbai, India), and anesthetic ether (TKM Pharma, Hyderabad, India) were purchased. Galactomannan was given as gift sample by Indus Biotech, India.

Animals

Immature male Wistar rats of weight range 55±5 g and adult male Swiss albino mice (18-23 g) were purchased from National Toxicology Centre, Pune, India and used for the study. They were maintained at a temperature of 25 ± 1 °C and relative humidity of 45 to 55% under 12:12-h light dark cycle. The animals had free access to food pellets (Chakan Oil Mills, Pune, India) and water was given ad libitum. The experimental protocol was approved by the Institutional Animal Ethics Committee (IAEC) of Poona College of Pharmacy, Pune, India, constituted under Committee for the Purpose of Control and Supervision of Experiment on Animals (CPCSEA).

Acute Oral Toxicity of Drug (10)

Healthy male adult Swiss mice weighing between 18 -23 g were used for acute oral toxicity study. The study was carried out according to OECD (Organization

for Economic Co-operation and Development) guideline no. AOT-425 (14). The mice were observed for 2 hrs for behavioral, neurological and autonomic profiles and for any lethality or death for the next 48 h.

Castration of rats

Immature male Wistar rats (55 gm \pm 5gm) were castrated by method described by Ottani *et.al.*, (2002) (10). Small transversal incision was given in the skin on the ventral site symphysis. The testis in the scrotum was gently pushed into abdominal cavity. The epididymal fat pad is grasped with the forceps and the testis with the epididymis was pulled out from abdominal opening. The testis together with the epididymal fat pad was cut. Skin wound was sutured with one or two sutures. After recovery period of 2 days they were divided into 4 groups of five rats each.

Anabolic and androgenic activity in castrated rats

The above rats of were divided into following groups and treated daily I) Vehicle II) galactomannan (10 mg/kg p.o.), III) galactomannan (35 mg/kg p.o.) and IV) group received testosterone (10 mg/kg in sesame oil suspension, s.c. bi-weekly). Twenty hours after last day of treatment, blood was withdrawn and then animals were sacrificed. The seminal vesicles, the ventral prostate, and the musculus levator ani were carefully dissected and weighed. Body weight of the animals was registered at the beginning and at the end of the experiment. Increase in weight of seminal vesicles and ventral prostate indicates androgenic activity, whereas gain in weight of musculus levator ani was considered to indicate anabolic activity (12).

Effect on serum testosterone and blood urea nitrogen

The blood was withdrawn from the rats by retro orbital puncture method. Blood was centrifuged to separate. The serum was analyzed for biochemical parameter blood urea nitrogen (BUN), using standard biochemical kits and serum testosterone was measured by radioimmunoassay (RIA).

Effect on histopathology of testis in non castrated rats

Immature male Wistar rats weighing 55 gm (\pm 5gm) were divided into following groups I) Vehicle treated, II) galactomannan (10 mg/kg p.o.), III) galactomannan (35 mg/kg p.o.) and IV) testosterone (10 mg/kg in sesame oil suspension, s.c. bi-weekly). After 4 weeks of treatment, animals were sacrificed. The testis from each group were excised quickly during the above studies using a separate group of noncastrated male rats and fixed in 10% buffered neutral formalin. The sections were stained with haematoxylin and eosin dye. Histopathological examination of testis was carried out.

Statistical analysis

Data for each parameter was analyzed by one-way ANOVA followed by Dunnett's test using Graph Pad Instat 3.01 for Windows 95, Graph Pad Software Inc.

Results

Acute oral toxicity test indicated that the galactomannan is safe up to 5000mg/kg orally.

Anabolic activity of galactomannan

The body weight of control and galactomannan (10 mg/kg p.o.) treated animal increased from initial 55 ± 5 g to 151.6 , 138 ± 3.98 respectively. These results indicated that galactomannan (10 mg/kg p.o.) did not increase body weight compared to control. However treatment with galactomannan (35mg/kg p.o) and testosterone (10 mg/kg s.c.) significantly ($P < 0.01$) increased body weight from 55 ± 5 g to 234.2 ± 4.9 , 254 ± 10.9 respectively. (Figure 1)

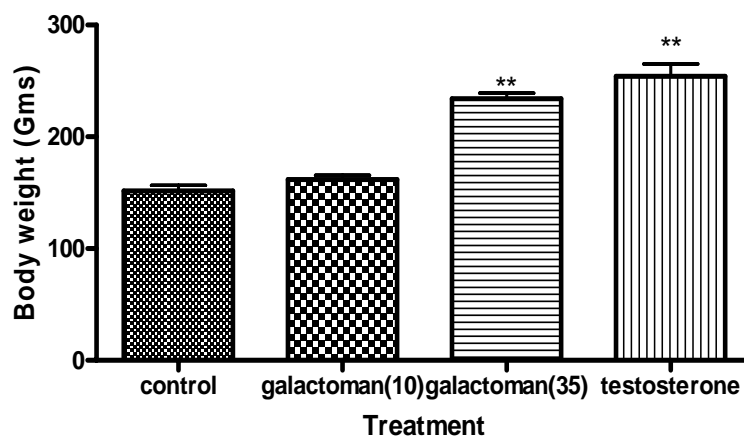


Figure 1: Effect of Galactomannan (galactoman) (10 and 35 mg/kg,p.o daily) and Testosterone (testosterone, 10 mg/kg, s.c. bi-weekly) on body weight (g.) Figures in bracket indicate dose in mg/kg. Data represented as mean weight (g.) of five rats \pm S.E.M. ** $P < 0.01$, as compared with castrated control group.

The organ weights of seminal vesicle, ventral prostate, levator ani and penis weight in the castrated (vehicle) animals were 6.16 ± 1.5 , 3.96 ± 0.54 , 27.3 ± 2.5 and 36.28 ± 2.2 . Galactomannan (10) did not show significant increase in organ weights. Galactomannan (35 mg/kg) showed significant ($P < 0.001$) increase in levator ani muscle (178.18 ± 6.9) but nonsignificant increase in weights of organs

of male reproductive system. Testosterone on other hand significantly ($P < 0.001$) increased the weight seminal vesicle (32.6 ± 0.7), ventral prostate (40.6 ± 4.03), and musculus levator ani (177 ± 3.96). (Figure 2)

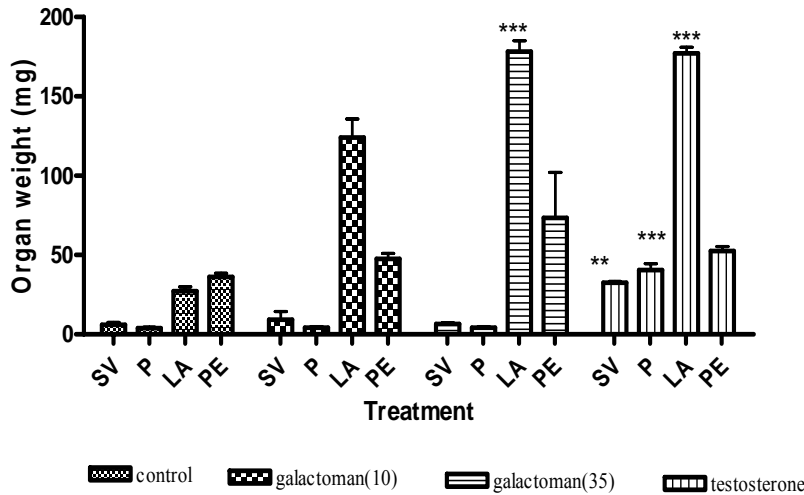


Figure 2. Effect of Galactomannan (galactoman) (10 and 35 mg/kg,p.o daily) and Testosterone (testosterone, 10 mg/kg, s.c. bi-weekly) on organ weight of male castrated rats. Figures in bracket indicate dose in mg/kg. Data represented as mean weight (g.) of five rats \pm S.E.M. ** $P < 0.01$, *** $P < 0.01$, as compared with castrated control group. SV- Seminal Vesicle, P- ventral Prostate, LA-Levator ani muscle, PE-Penis.

Effect on and Blood Urea Nitrogen (BUN)

Galactomannan (35 mg/kg p.o) and testosterone group did not show significant increase in BUN compared to control group (noncastrated vehicle treated). However lower dose of galactomannan (10 mg/kg p.o) produced significant ($P < 0.01$) increase in BUN.

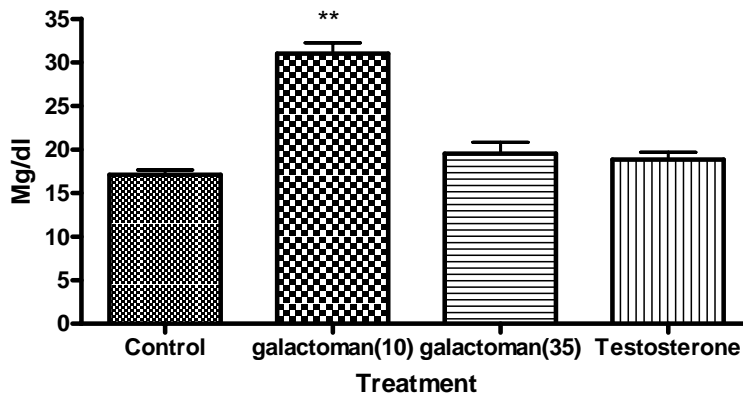


Figure 3: Effect of Galactomannan (galactoman) (10 and 35 mg/kg p.o daily) on BUN in male rats after 4 weeks of treatment. Separate groups for vehicle and standard drug testosterone 10 mg s.c. twice weekly were also maintained. Figures in bracket indicate dose in mg/kg. Data represented are mean BUN (mg/dl) in castrated male rats (five per group) and analyzed by one-way ANOVA followed by Dunnett's post hoc test. ** P < 0.01 as compared with normal (non castrated) untreated group.

Effect on serum testosterone

Testosterone (10 mg/kg s.c) treatment significantly increased serum testosterone level whereas galactomannan (10, 35 mg/kg p.o.) did not increase serum testosterone level. In the control group decrease in testosterone was observed as a result of castration. Figure 4

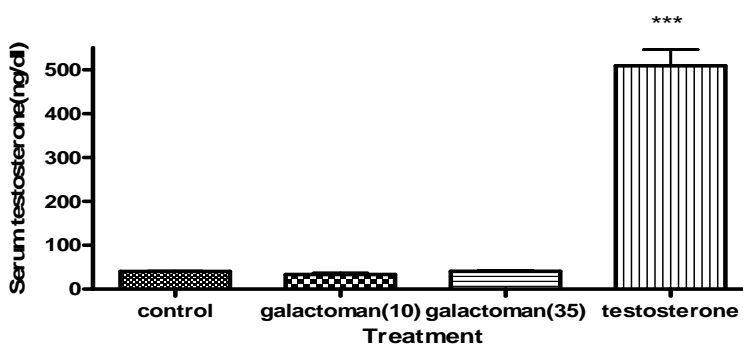


Figure 4: Effect of Galactomannan (galactoman) (10 and 35 mg/kg p.o daily) on serum Testosterone (ng/dl) in male rats after 4 weeks of treatment. Separate groups for vehicle and standard drug testosterone 10 mg s.c. twice weekly were also maintained. Figures in bracket indicate dose in mg/kg. Data represented are Testosterone level (ng/dl) ± SEM in castrated male rats (five per group) and analyzed by one-way ANOVA followed by Dunnett's post hoc test. *** P < 0.001 as compared control (castrated) untreated group.

Effect on histopathology of testis

The testes of rats treated with vehicle, testosterone or galactomannan showed normal features with successive stages of transformation of the seminiferous epithelium into spermatozoa with no sign of atrophy or toxicity with respect to pachytene spermatocytes, germ cells, Leydig cells, or Sertoli cells. (Figure 5)

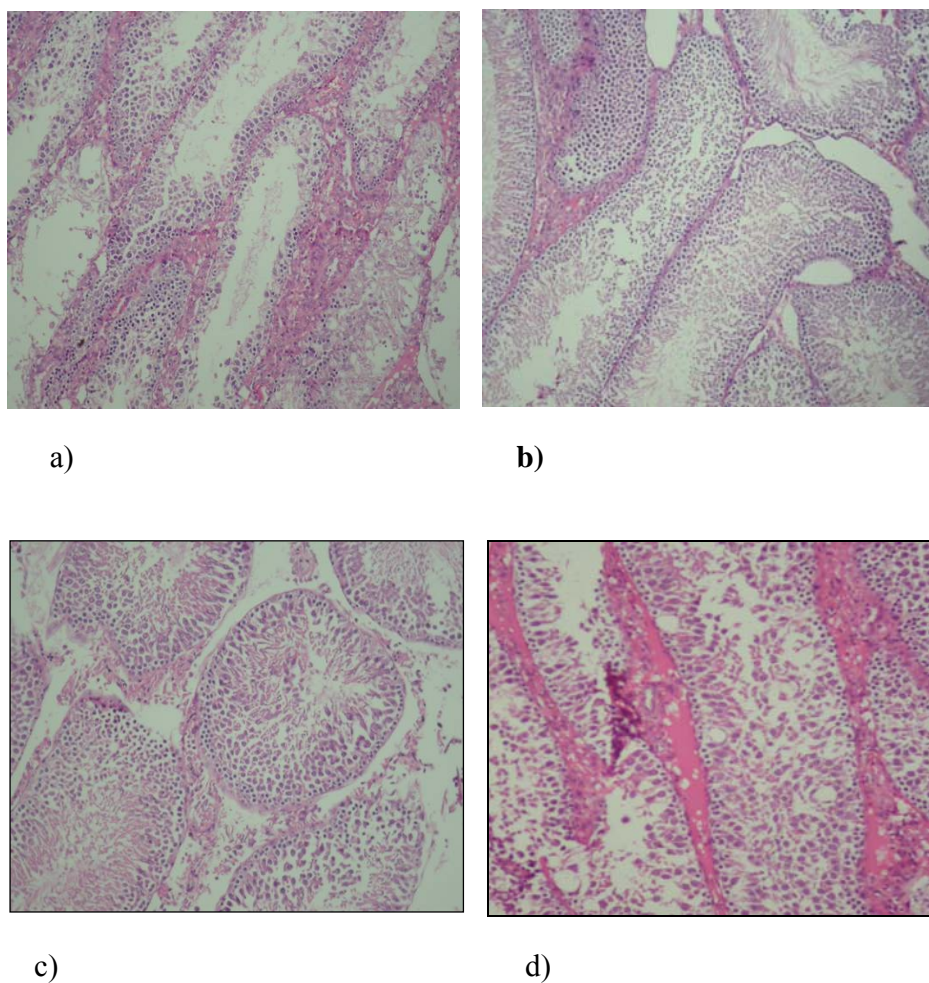


Figure 5. Effect on histopathology of testis of male noncastrated animals pretreated for one month with a) vehicle, b) galactomannan (10 mg/kg p.o.) c) galactomannan (35 mg/kg p.o.) and testosterone (10 mg/kg s.c. twice weekly) in male noncastrated rats.

Discussion

Seeds and leaves of TF are used as food as ingredient in traditional medicines. Fenugreek leaves contains calcium, iron, β - carotene and other vitamins (13). The seeds are reported to contain lysine and L- tryptophan rich proteins, mucilaginous fibre, 3 minor steroidal saponins – similagenin, savsalpogenin and yuccagenin, coumarin, fenugreekine, nicotinic acid, saponin, phytic acid, scopletin and trignelline (14). The mucilage of seeds contains galactomannans (15). These galactomannans have a unique structure and may be the responsible for some of the characteristic therapeutic property attributed to fenugreek (16).

Many synthetic analogues of testosterone were prepared in order to separate the anabolic activity of C₁₉ steroids from their androgenic activity. Although a pure synthetic anabolic with no androgenic has not been successfully prepared. The marketed preparation anabolic steroid preparation have high anabolic-androgenic ratio (17).

Anabolic agents induce positive nitrogen (N) balance in living organisms. Measurements of N excretion in castrated rat fed with liquid diet are used to determine nitrogen balance. (18) The castrated male rat serves as most sensitive model for N retention. Another bioassay for anabolic activity involves measurement of increase in weight of levator ani muscle in rat upon oral administration of anabolic agent. This measure of myotropic activity effect correlate well with N retention bioassay and two are usually performed in determination of anabolic activity (17). In the present investigation galactomannan (10 mg/kg p.o.) was ineffective as anabolic agent as it did not significantly increase weight of levator ani but increased BUN. However higher dose of galactomannan (35 mg/kg) and testosterone (10 mg/kg p.o.) significantly increased weight of levator ani muscle without increasing BUN indicating anabolic activity.

Androgens affect the development of secondary sex organs in male. In rat growth of ventral prostate, seminal vesicle and musculus levator ani is dependent on the presence of male sex hormones. Lack of increase in weight of the male sex organ by galactomannan (35 mg/kg) indicated absence of androgenic activity. Testosterone (10mg/kg s.c biweekly) treatment increased weight of male sex organs.

In a separate study we have observed that galactomannan (60 mg/kg) increased body weight of alloxan induced diabetic rats (unpublished data) .This observation confirmed in the present study and regarded as the experimental evidence of anabolic activity of galactomannan. Galactomannan is a polysaccharide consisting of mannose backbone with branch points from their 6 positions linked to alpha-D-galactose. The galactomannan in fenugreek seed contain galactose and mannose in the ratio of 48:52. Galactomannan in the fenugreek seed is also the factor responsible in controlling plasma sugar and cholesterol level in both animal

and human models of diabetes mellitus. The antidiabetic and hypocholesterolaeic properties of fenugreek, both of which are mainly attributable to this intrinsic dietary fiber constituent galactomannan have promising nutraceutical value (19, 20)

Conclusion

Galactomannan appears to be a unique preparation of plant origin devoid of androgenic activity but a strong anabolic activity. The demonstrated ability of galactomannan increase muscle mass without affecting hormonal status of the body makes it favorable use in sports and nutrition.

Acknowledgement

We are grateful to Dr.K.R.Mahadik Principal, Poona College of Pharmacy for providing all the facilities for carrying out this work.

References

1. Mc Whorter LS. Biological Complementary Therapies: A Focus on Botanical Products in DiabetesDiabetes Spectrum 2001; 14: 199-208.
2. Nath D, Sethi N, Srivastava S, Jain AK. Survey on indigenous medicinal plants used for abortion in some districts of Uttar Pradesh. 1997 Fitoterapia; 68(3):223-225.
3. El-Kamali HH, Khalid. The most common herbal remedies in Central Sudan. Fitoterapia 1996; 67 (4): 301-306.
4. Ziyyat A, Legssyer A, Mekhfi H, Dassouli A, Serhrouchni M, Benjelloun W. Phytotherapy of hypertension and diabetes in oriental Morocco.J Ethnopharmacol 1997; 58: 45-54.
5. Santillo H. Natural Healing with Herbs, 10th ed. Hohm Press, Prescott, AZ, USA, 1993: 119-120.
6. Hardman R. Recent work on plant of therapeutic interest. Phytochemistry 1969; 8: 1319-1322.
7. Kassem A, Aghbari A, Habori M, Mamary M. Evaluation of potential antifertility effect of fenugreek seeds in male and female rabbits. Contracept 2006; 73: 301 – 306.
8. Kamal R, Yadav R, Sharma JD. Efficacy of the steroidal fraction of fenugreek seed extract on fertility of male albino rats. Phytother Res 1992; 7 (2): 134-138.
9. Sharma R D, Effect of fenugreek seeds and leaves on blood glucose and serum insulin responses in human subjects. Nutr Res 1986; 6(12); 1353
10. Organization for Economic Co-operation and Development. 2001; Guidance Document on Acute Oral Toxicity Testing. Paris, Environment Directorate, OECD.

11. Ottani A, Giuliani D, Ferrari F. Modulatory activity of sildenafil on copulatory behaviour of both intact and castrated male rats. *Pharmacol Biochem. Behav* 2002; 72: 717-22.
12. Eisenberg E, Gordon GS. The levator ani muscle of the rat as an index of myotrophic activity of steroidal hormones. *J Pharmacol Exp Ther* 1950; 99: 38-44.
13. Sharma RD, Sarkar A, Hazra DK. Hypolipidaemic effect of fenugreek seeds: a chronic study in non insulin diabetic patient. *Phytother Res* 1996; 10: 332-334
14. Billaud C, Composition, nutritional value and physiological properties. *Adrian J Fenugreek. Sciences-des-ailments* 2001; 21(1); 3-26
15. Puthenpura B, Bala N, Perumana S. Hypolipidaemic effect of chemically different mucilages in rats: a comparative study. *B J Nutr* 2006; 96(6); 1021-1029
16. Madar Z, Abel R, Samish S, Arad J. Glucose –lowering effect of fenugreek in non insulin dependent diabetics. *Eur j Clin Nutr* 1988; 42: 51-54.
17. Brueggemeier R.W. Sex Hormones (Male): Analogs and Antagonists. In: Meyers R.A. ed. *Encyclopedia of Molecular Cell Biology and Molecular Medicine*, 2nd edn. Wiley-VCH Verlag GmbH & Co. KGaA, Weinheim, 2005: 13: 30-31
18. Vogel H, *Drug Discovery and Evaluation Pharmacological Assays*, 2nd edition, Springer publication, Germany, 2002: 1177-1178
19. Al-Habori M, Raman A. Antidiabetic and hypocholesterolaemic effects of fenugreek. *Phytother Res.* 1998; 12: 233-242
20. Srinivasn K. fenugreek (*Trigonella foenum gracum*): A Review of Health Beneficial Physiological Effects. *Food reviews international* 2006; 22(2): 203-224.

*Corresponding author: Dr. Subhash L. Bodhankar,
Professor and Head, Department of Pharmacology,
Bharati Vidyapeeth University,
Erandawane, Paud Road, Pune-38.
Tel: +91-20-25437237 Ext-29, Fax: +91-20-25439383,
E-mail: sbodh@yahoo.com