

**ANALYSIS OF THE SISTEMIC TOXICITY OF DEXAMETHASONE AND
THERAPEUTIC EFFECT OF OMEPRAZOLE IN THE GASTRIC MUCOSE IN
RATS – HYSTOPATOLOGICAL ANALYSIS**

**Ana Paula Emmendorfer Pereira¹, Amanda Karenine Pampuch¹, Ana Paula Camargo
Martins³, Sérgio Aparecido Ignácio², Maria Ângela Naval Machado³, Antônio Adílson
Soares de Lima³, Luciana Reis de Azevedo⁴, Ana Maria Trindade Grégio^{1*}**

**¹ Department of Pharmacology and Therapeutics, ² Department of Statistics,
³ Department of Oral Pathology, ⁴ Department of Oral Medicine and Surgery, School of
Dentistry, Pontifical Catholic University of Paraná, 80215-901, PR, Brazil.**

SUMMARY

Steroidal anti-inflammatory drugs are the most common therapeutic drugs in the medical clinic and dentistry. The majority of steroidal anti-inflammatory exhibit undesired side effects, and when under chronic use problems such as nephrotoxicity, hepatotoxicity and severe gastric lesions may occur. This study verified the systemic toxicity of dexamethasone and therapeutic effect of omeprazole in the prevention of gastric injuries induced for the dexamethasone in rats. A total of 36 Wistar male rats were divided in three groups and submitted to the following chronic treatments: group 1 – Saline (0.1 mL intraperitoneal), group 2 – dexamethasone (1,0 mg/kg intramuscular) and group 3 – dexamethasone (1,0 mg/kg intramuscular) plus omeprazole (5,0 mg/kg intraperitoneal). After the treatment period (30 days) the animals were sacrificed - group 1 and 2 had liver, kidney, stomach and intestine removed, group 3 only stomach were removed. These organs were processed for HE and analyzed using the software Pro Image Plus. Both associations of drugs (dexamethasone and dexamethasone + omeprazole) exhibited a predominance of neutrophils, lymphocytes and macrophages. In the liver it had increase in the number of neutrophils, lymphocyte and macrophage. In the kidney it had proliferation of neutrophils, macrophage and lymphocyte. In the intestine it had increase in the number of neutrophils. In the stomach it had proliferation of neutrophils and macrophage and with the association of omeprazole it had reduction of lymphocyte.

Key-word: anti-inflammatory, toxicity, nephrotoxicity, hepatotoxicity and gastric lesions.

* Corresponding author: Department of Pharmacology and Therapeutics – PUCPR, Rua Imaculada Conceição, n. 1155, 80215-901, Curitiba, PR, Brazil; e-mail: ana.gregio@pucpr.br
Telephone number: (5541) 3243-4541; Fax number: (5541) 3271-1405

INTRODUCTION

The corticosteroids are anti-inflammatory steroids widely used in the medical clinic and dentistry (1). They are synthetic drugs, however the chemical structure derives of the hormones steroids synthesized starting from the suprarenal. The endogenous glicocorticoid are produced starting from the cholesterol, captured from the circulation under the form of lipoprotein of low density. The synthetic corticoid are produced starting from the obtained colic acid of the cattle or of plants of the families of *Liliaceae* and *Discoriaceae*. The main indications elapse from the action of anti-inflammatory and immunosuppressant. It is worth to emphasize that the physiologic and pharmacological actions occurs for the activation of the same receptors. The concentrations that cause the wished effects promote the forthcoming of adverse reactions equally that, they are just exacerbation of the events observed usually.

The main therapeutic uses of the corticoids: in allergies, neurology, psychiatry, diseases of the digestive system, endocrinology, infectious diseases, pneumology, treatment of the shock, nephrology, disease of the collagen and ophthalmology. The chronic use of these drugs leave a severe adverses effects. Among them the systemic toxicity on the treatment gastrointestinal, liver and kidneys. The aim of this study is analyse the systemic toxicity of the dexamethasone in the stomach, intestine, liver and kidney, in animals cronicaly treated by a period of thirty days and still, the therapeutic effect of the omeprazole was verified in the prevention of the gastric lesions induced by the dexamethasone.

MATERIAL AND METHODS

The sample of the population investigated in this study was constituted of male rats of the type *Rattus norvegicus albinus*, *Rodentia*, *Mammalia* of the lineage Wistar, originating from of Central Vivarium of the Catholic University of Parana, Brazil.

This project had approval of the Committee of Ethics in Research with Animals of the Tuiuti University of Parana (UTP), Brazil.

The whole experimental part followed the norms for the Didactic-scientific Practice for the vivissecção of animals in agreement with the Law 6.638, May 08, 1979 (GOLDIM, 1995).

The animals received feeding and water *ad libitum*. The atmosphere was maintained in ideal conditions to guarantee a correct cycle in the metabolism of the animals and so that there was not interference in the final result of the research, respecting the photo period of 12 hours.

The animals were divided in 03 groups with 12 animals each one, being the first group the control (group 1) and the others experimental (dexamethasone = group 2 and dexamethasone + omeprazole = group 3), totaling 36 mice. The dose of the drugs administered in the rats was calculated basing in the Manual of Veterinary Drugs (ALLEN et al., 1998).

The group control received 0,1mL of saline solution through intraperitoneal, the experimental group for Dexamethasone (Duct - Brazil, lot -50185) it received 1,0 mg/Kg through intramuscular and other, Dexamethasone (1,0 mg/Kg through intramuscular) more 5mg/kg of Omeprazole (Cosmetic - drugstore PR / Brazil), through intraperitoneal. All the animals were submitted to the chronic treatment by 30 days.

The animals were anesthetized properly with sodic Tiopental (Cristália - Brazil) in the dose of 100 mg/Kg. After the sacrifice of the animals, in the groups 1 and 2 took out the organs (kidney, liver, stomach and intestine), and in the group 3 took out only the stomach. Elapsed the histological processing, using the hematoxiline-eosine coloration, the specimens of the animals of each group was analyzed the microscopic sheet through the light microscopy, being used a microscope and the computer program IMAGE FOR PLUS version 4.5 for Windows.

The statistical analysis was accomplished seeking to compare if difference existed among the medium values of cellular attachés in the kidneys, liver, intestine and stomach according to groups (saline and experimental) the test was used no parametric Friedman, and to test the distribution normality among the groups, the test of Komolgorov-Smirnov was used.

RESULTS

A total was analyzed (group 1 and 2) of 96 microscopic sheets, of these the stomach, intestine, kidney and liver were observed. And in the group 3 they were analyzed a total of 12 microscopic sheets, being only observed the stomach. The cells more observed were neutrophils, macrophages, lymphocytes and plasma cell. The dexamethasone promoted neutrophils emergence and macrophages in all of the studied organs, even in the group of animals that received dexamethasone plus omeprazole (Illustration 1 and 2, Graph 1 and 2).

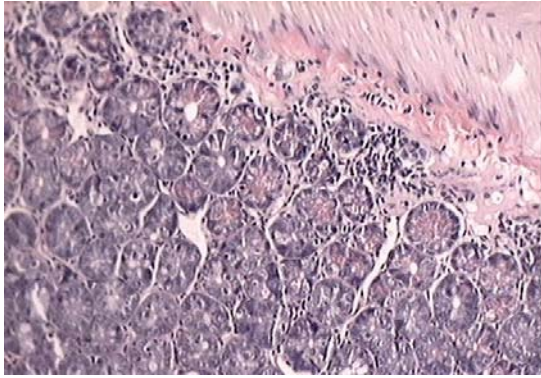


Illustration 1 - Histological aspect of the stomach after 30 days of treatment with Dexamethasone, presence of infiltrated inflammatory (HE, original increase of 100X).

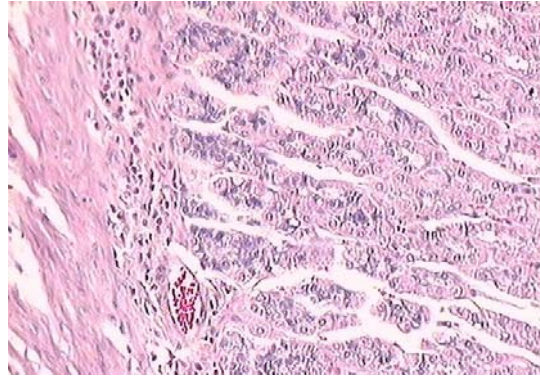
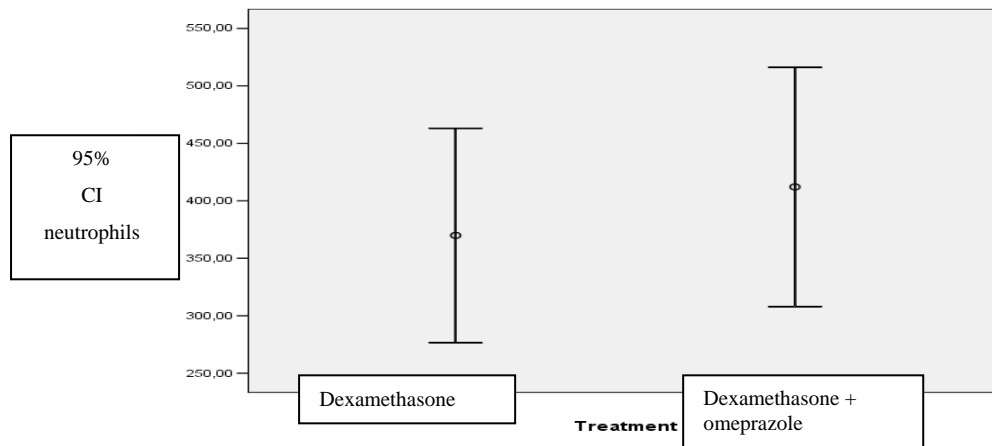
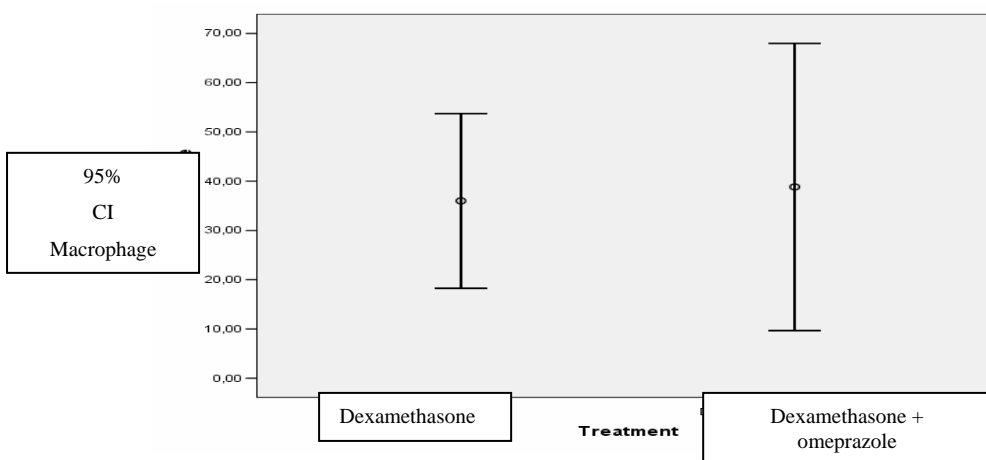


Illustration 2 - Histological aspect of the stomach after 30 days of treatment with Dexamethasone + Omeprazole, presence of having infiltrated inflammatory (HE, original increase of 100X).

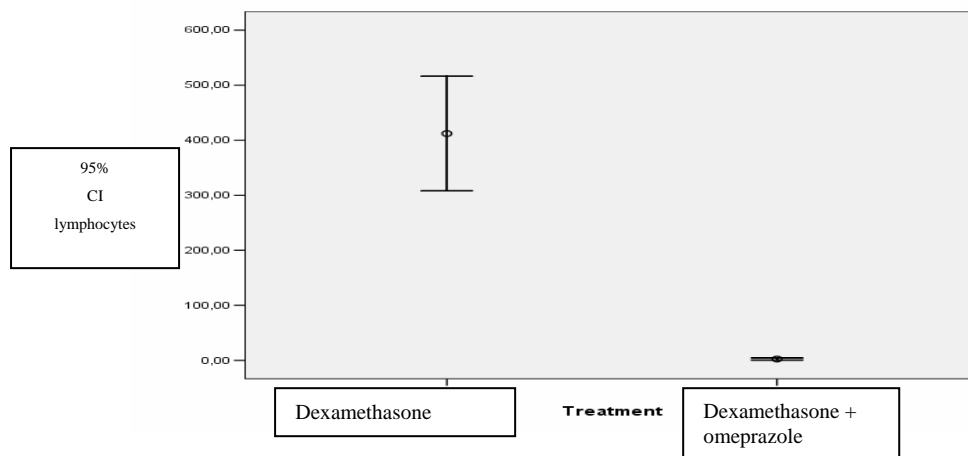


Graph 1 - Evaluation of the amount of neutrophils in stomach the animals treated with dexamethasone and dexamethasone+omeprazole.



Graph 2 - Evaluation of the amount of macrophages in stomach the animals treated with dexamethasone and dexamethasone+omeprazole.

About the number of lymphocytes, there was decrease in the group of animals that received dexamethasone plus omeprazole (stomach) (Graph 3).



Graph 3 - Evaluation of the amount of lymphocytes in the animals treated with dexamethasone and dexamethasone+omeprazole.

In the liver there was increase in the neutrophils number, lymphocytes and macrophages, characterizing a chronic and acute inflammatory process (Illustrations 3 and 4).

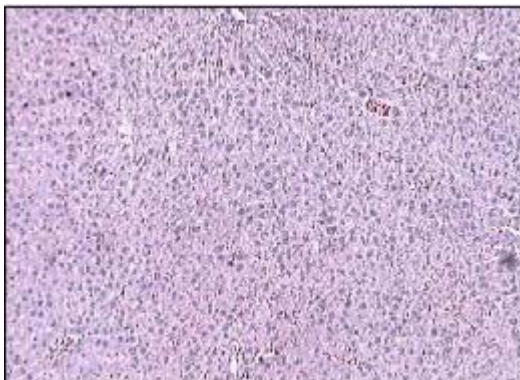

Illustration 3 - Histological aspect of the liver of the group controls - normality aspect (HE, original increase of 20X).

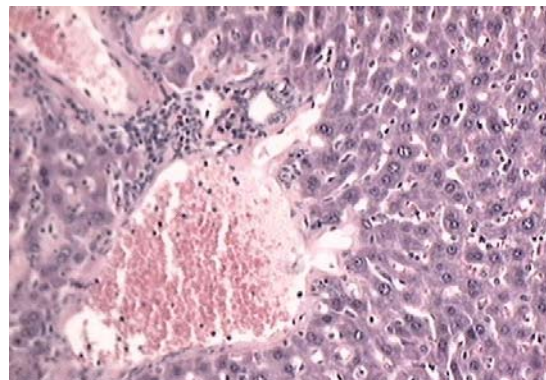


Illustration 4 - Histological aspect of the liver after 30 days of treatment with Dexamethasone, presence of having infiltrated inflammatory (HE, original increase of 100X).

About the kidney, there were neutrophils, macrophages and lymphocytes proliferation (Illustrations 5 and 6).

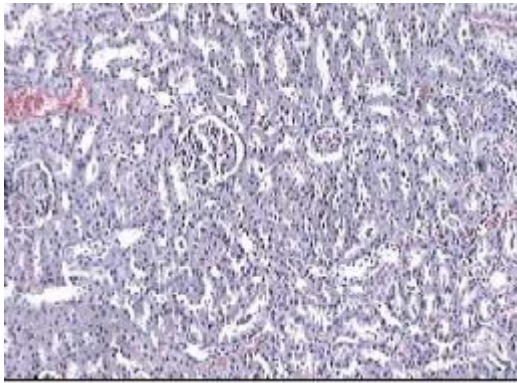


Illustration 5 - Histological aspect of the kidney of the group controls - normality aspect (HE, original increase of 20X) .

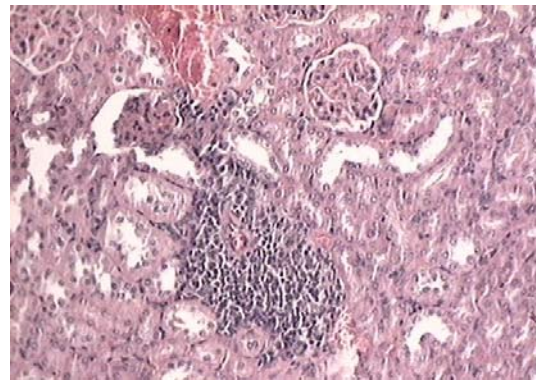


Illustration 6 - Histological aspect of the kidney after 30 days of treatment with Dexamethasone, presence of having infiltrated inflammatory (HE, original increase of 100X).

In the intestine there was neutrophils exacerbation, characterizing an acute inflammatory process (Illustrations 7e 8).

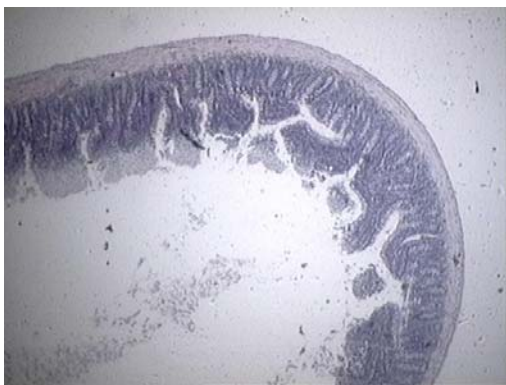


Illustration 7 - Histological aspect of the intestine of the group controls - normality aspect (HE, original increase of 20X).

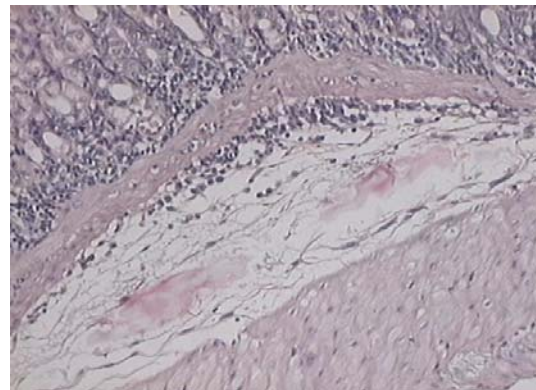
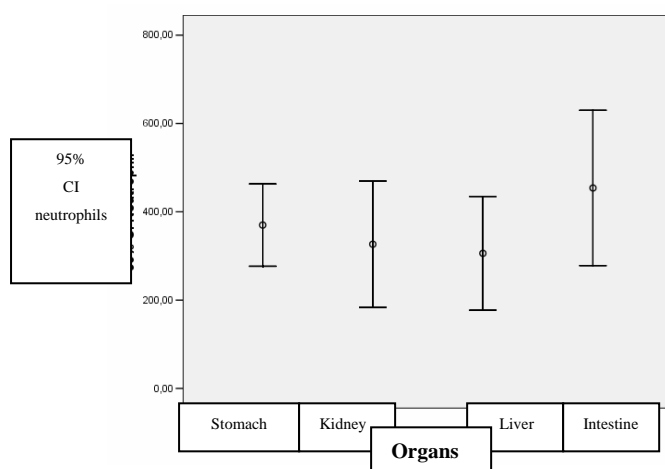
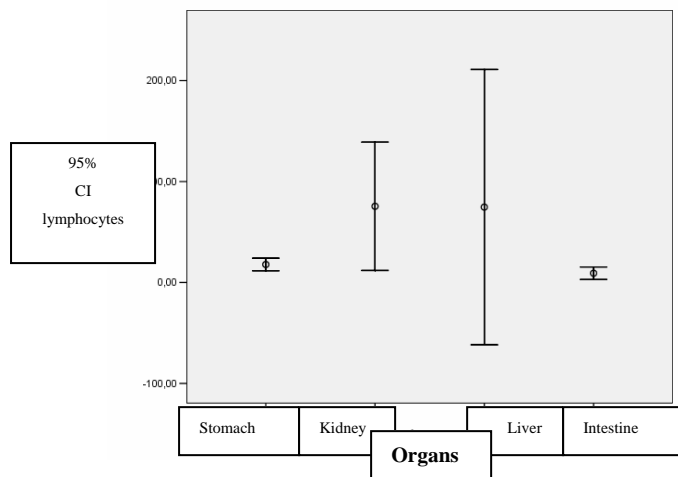


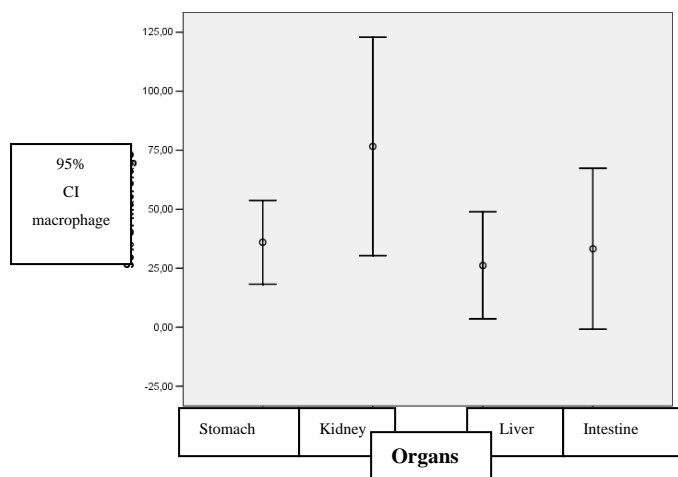
Illustration 8 - Histological aspect of the intestine after 30 days of treatment with Dexamethasone, presence of having infiltrated inflammatory (HE, original increase of 100X).



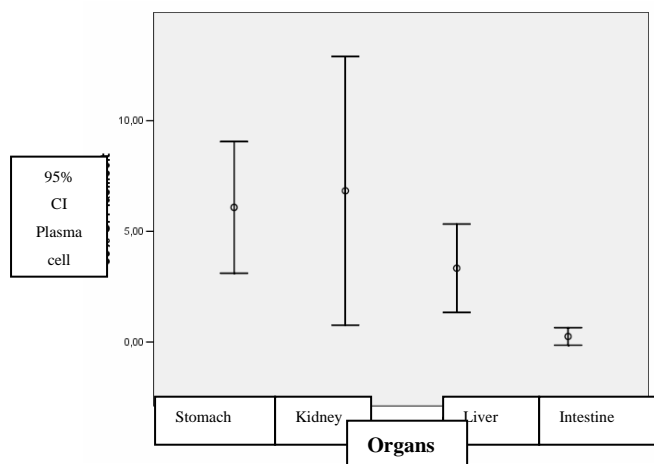
Graph 4 - Comparison of the amount of neutrophils in their different organs, in rats treated for 30 days with Dexamethasone (1mg/kg).



Graph 5 - Comparison of the amount of lymphocytes in their different organs, in rats treated for 30 days with Dexamethasone (1mg/kg).



Graph 6 - Comparison of the amount of macrophages in their different organs, in rats treated for 30 days with Dexamethasone (1mg/kg).



Graph 7 - Comparison of the amount of plasma cell in their different organs, in rats treated for 30 days with Dexamethasone (1mg/kg).

DISCUSSION

The dexamethasone, a synthetic corticosteroid, has been widely used in the practice clinic (2). The corticosteroids are derived of the hormones steroids, they are the most potent known anti-inflammatory agents (3). The glicocorticoids present anti-inflammatory potencies and immunosuppressant (4), in other words, they demonstrate to inhibit the inflammatory cellular answer (5). The effectiveness of the corticoids in the inflammatory process can be dramatic and mean clinically for the decrease of the classic signs of the inflammation. Adverse effects of the therapeutics with the anti-inflammatories steroids can happen with the prolonger using, systemic or topic of pharmacological doses. In chronic systemic treatments, undesirable effects appear in the validity of pharmacological doses or suspension of those.

Besides the use in many and in several specialties, the corticoids are used in varied preparations, in doses very different from a case for other, for different ways and time of use no uniform, what turns possible an enormous amount of side effects. The reason why the glicocorticoids produce so many and so varied side effects elapses of the numerous metabolic actions that that group of drugs produces. As the glicocorticoids have systemic actions, their side effects also reach several organs and systems (3). These data corroborate with our discoveries, because it was observed in our research damages to the analyzed organs: stomach, liver, kidneys and intestine.

The longered corticoterapy induces the light increment of the production of hydrochloric acid for the gastric mucous membrane; however, increase doesn't exist in the incidence of peptic ulcers, in agreement with recent data, except in those individuals receiving anti-inflammatories no-steroids concomitantly (11). According to the authors DAMIANI, D., KUPERMAN, H., DICHTCHEKENIAN, V., MANNA T.D., SETIAN, N. (2000) the glicocorticoids induce to the emergence of peptic ulcers, due to the decrease of the levels of mucous secretion and of the factor of epidermal growth (6, 7). As observed in our research there was an increase in the neutrophils number and macrophages in the rats treated with Dexamethasone, suggesting the formation chronic and acute of an inflammatory process, demanding the care on the part of the professional from the medical area when prescribing these drugs to patient with gastric compromising.

Nor used in appropriate doses the omeprazole nor the misoprostol they were effective in the cure and prevention of lesions of the gastric mucous membrane in dogs (8). In the group of animals that received dexamethasone + omeprazole there were the neutrophils and macrophages proliferation, indicating the emergence of chronicle and acute inflammatory lesion.

There are evidences that the corticosteroids are the responsible for ulceration and colon perforation, be for direct offenses or for interference with the normal mechanism of repair (1). In the present I also study the presence of cellular attachés was verified, with prevalence of neutrophils, indicating an inflammatory process acute.

It is frequent the renal adverse effects under the continuous exhibition with corticoids, this event is characterized by the edema, systemic arterial hypertension and hypokalemia, we observed a great infiltrated inflammatory in the kidney demonstrated by the excessive number of macrophages and lymphocytes. Suggesting an alteration in the glomerulus filtration caused by the renal toxicity of the corticosteroid. In an administration of dexametasone in rats for 7 days was verified in the histological and histochemical analysis that the drug didn't cause damages to the renal parenchyma (9). Meantime in the chronic use the presence of renal offenses was verified, with emergence of neutrophils, suggesting an acute toxicity, however due to the longering treatment of the drug and the passage for the kidneys in the process of glomerulus filtration this lesion became chronicle, characterized by the increase of the number of lymphocytes and macrophages.

Tends in view that Aines (anti-inflammatories no-steroids) they present hepatotoxicity for they be drugs of high molecular weight and soluble in fat, they are more difficult of be broken for the hepatic enzymes and they can be widely found in the hepatocytes after long administration period. The nimesulide is a drug that can cause hepatitis fulminant by medication (10). The corticoids when chronicle administered can also cause hepatic damages, jaundice (icterus), hepatomegalia and hepatitis by medication (5). Being analyzed the prevalent cells in the liver, great amount of lymphocytes was observed, suggesting a chronic inflammation, this is probably due to the fact of this organ to be the main metabolyzer of the corticoids and due to the 30 days of exhibition of the organism by action of the drug.

CONCLUSIONS

Based on the discoveries of this study can be ended that:

1. Dexamethasone induced the emergence of inflammatory cells (macrophages, lymphocyte, neutrophils) in the kidneys, stomach, intestine and liver.
2. Omeprazole did not prevent the lesions of the gastric mucous membrane when associate to Dexamethasone.
3. Dexamethasone is potentially aggressive and it causes damages to the stomach, intestine, kidneys and liver when chronic administered.

ACKNOWLEDGMENTS

The authors would like to profusely thank the laboratory of Pathologic of Pontifical Catholic University of Parana.

REFERENCES

- [1] A.L. Warshaw, J.P. Welch, L.W. Ottinger. Acute perforation of the colon associated with chronic corticosteroid therapy. *Am J Surg* 131, 1976, 442-446.
- [2] R.J. Dinis-Oliveira, J.A. Duarte, F. Remiao, A. Sanchez-Navarro, M.L. Bastos, F. Carvalho. Single high dose dexamethasone treatment decreases the pathological score and increases the survival rate of paraquat-intoxicated rats. *Toxicology* 227, 2006, 73-85.
- [3] D. Damiani, H. Kuperman, V. Dichtchekian, T.B. Manna, N. Setian. Repercussions of corticotherapy: the cost-benefit ratio. *IPLD of FMUSP*, 2000.
- [4] C.A. Longui, M.C. Santos, C.B. Formiga, D.V.A. Oliveira, M.N. Rocha, C.D.C. Faria, C. Kochi, O. Monte. Antiproliferative and apoptotic potencies of glucocorticoids: nonconcordance with their antiinflammatory and immunosuppressive properties. *Arq. Bras. Endocrinol. Metab.* 49, 2005, 378-383.
- [5] A.M. Morariu, B.G. Loef, L.P.H.J. Aarts, G.W. Rietman, G. Rakhorst, W.V. Oeveren, A.H. Epema. Dexamethasone: Benefit and Prejudice for Patients Undergoing On-Pump Coronary Artery Bypass Grafting. *Chest*, 128, 2005, 2677-2687.
- [6] B. Elitok, O.M. Elitok, M.A. Ketani, D. Kurt, Z. Kanay. The effect of dexamethasone on gastric mucosal changes following sialoadenectomy in rat. *J Endocrinol. Invest.* 28, 2005, 700-703.
- [7] L.C. Luo, C.W. Chi, H.Y. Lin, F.Y. Chang, C.L. Lu, C.Y. Chen, S.D. Lee. Dexamethasone inhibits epidermal growth factor-stimulated gastric epithelial cell proliferation. *J Pharmacol. Exp. Ther.* 320, 2007, 687-694.
- [8] R. Neiger, F. Gaschen, A. Jaggy. Gastric mucosal lesions in dogs with acute intervertebral disc disease: characterization and effects of omeprazole or misoprostol. *J Vet Intern Med* 14, 2000, 33-36.
- [9] K. Czerny, E. Kifer-Wysocka, J. Romanowska-Sarlej, E. Kurnicka. Histochemical and histologic examination of kidney from white rats after experimental administration of dexamethasone. *Ann Univ Mariae Curie Sklodowska Med* 46, 1991, 59-63.
- [10] A. Schattner, N. Sokolovskaya, J. Cohen. Fatal hepatitis and renal failure treatment with nimesulide. *Journal of Internal Medicine* 247, 2000, 153-155.
- [11] S. Faical, M.H. Uehara. Efeitos sistêmicos e síndrome de retirada em tomadores crônicos de corticosteróides. *Rev. Ass. Med. Brasil* 44, 1998, 69-74.