

**HYPOLIPIDEMIC EFFICACY OF *OCIMUM SANCTUM* IN THE PREVENTION OF ATHEROGENESIS IN MALE ALBINO RABBITS**

**Geetha Samak<sup>1</sup>, Muddanna S. Rao<sup>2\*</sup>, Rajendra Kedlaya<sup>3</sup> and D. M. Vasudevan<sup>4</sup>**

<sup>1</sup>DVS College of Arts and Science, Shimoga, Karnataka, India, <sup>2</sup>Department of Anatomy, KMC, Manipal, Karnataka, India, <sup>3</sup>Department of Biochemistry, KMC, Manipal, Karnataka, India, <sup>4</sup>Amrita Institute of Medical Sciences and Research Center, Cochin, Kerala, India.

\* Corresponding author-Associate professor, Department of anatomy, KMC, Manipal, Karnataka, India, 576104. E-mail: muddannas@yahoo.com

**Summary**

Effect of aqueous extract of *Ocimum sanctum* on experimentally induced atherosclerosis in rabbits has been studied. Feeding 0.5g cholesterol /day for 45days has induced atheroma in control group. A dose dependant reduction in atheroma in *Ocimum sanctum* extract treated groups was noticed. *Ocimum sanctum* extract treatment brought down the lipid levels of blood, liver and aortic tissue. Along with strong hypolipidemic effect, *Ocimum sanctum* inhibited the atherogenesis.

*Key wards: Ocimum sanctum, Atherosclerosis, atherogenesis, hypolipidemic, atheroma*

**Introduction**

The plant *Ocimum sanctum* (Linn.), holy basil (family *Labiatae*) is traditionally being used in Ayurveda and Siddha system of medicines in India for treating infections, skin diseases, hepatic disorders, cold, cough, malarial fever and as an antidote for snake bite (1). Earlier studies on *Ocimum sanctum* have shown that oral administration of leaf powder and aqueous extract found to be hypoglycemic, hypolipidemic and antioxidant booster in streptozotocin induced diabetic rats (2, 3). Earlier works pertaining to *Ocimum sanctum* have shown significant reduction in lipid profile in normal rabbits (4, 5, 6).

Atherosclerosis is characterized in blood vessels by their tunica intimal fatty lesions and formation of fibrous plaques called atheromas. Hypercholesterolemia and hypertriglyceridemia are major risk factors of atherosclerotic vascular diseases (7, 8). High plasma concentration of low-density lipoprotein (LDL)-cholesterol, and free radical driven lipid peroxidation are the key factors in the pathogenesis of Atherosclerosis (9).

This study was planned to study the effect of *Ocimum sanctum* under hypercholesterolemia induced oxidative stress and experimentally induced atherosclerosis in male albino rabbits. Adult male rabbits were fed with 0.5mg/kg cholesterol with or without different doses of aqueous extract of *ocimum sanctum* for 45 days. Biochemical evaluation of serum lipid profiles in normal control, cholesterol control and *ocimum sanctum* groups (10mg, 25mg, and 50mg/kg body weight/day) are followed up to 4 months. At the end of experimental period (at the end of 4 months), tissues were analyzed for their fat content. Histopathological evaluation of aorta and liver were done to see the hypercholesterolemia induced changes in these tissues. *Ocimum sanctum* brought down the blood and tissue cholesterol levels and hypercholesterolemia induced fatty changes in liver and aorta. *Ocimum sanctum* prevented atherogenesis in experimentally induced atherosclerosis in male albino rabbits. These actions may be attributed to the anticholesterol property of the *ocimum sanctum* in male rabbits

### **Materials and methods**

#### **Chemicals**

Butylated hydroxy toluene(BHT), Reduced Glutathione(GSH), Reduced nicotinamide adenine dinucleotide phosphate(NADPH), Glutathione reductase, Cumene Hydroperoxide, Sodium dodecyl sulphate were from Sigma Chemical Company(St Louis,MO). All other chemicals were of analytical grade purchased from SRL Research chemicals, India. Cholesterol Kit, Triglyceride Kit was purchased from Biocon Diagnostics, Bangalore, India.

#### **Preparation of extract**

Leaves of naturally grown *Ocimum sanctum* were collected from local area (Fig.1). Leaves were washed, dried in shade and powdered. The powder was used for extraction. 100g of leaf powder was refluxed with 750ml of double distilled water for 1 hr at 75-80°C, cooled and filtered. This procedure was repeated 3 times; extracts were pooled and evaporated using Lyophiliser (10).



**Fig.1: Ocimum sanctum (Linn) Plant**

### **Animals**

Male albino rabbits weighing about 1kg were housed individually in metallic cages. They were given food and water *ad libitum* and made to acclimatize over a period of 15 days. Total experimental duration was four months. Animals were grouped as (i) **Normal control-** rabbits were fed with normal diet throughout the experimental period, (ii) **Cholesterol group-** rabbits were fed with normal diet through out the experimental period + 0.5g cholesterol/ day for first 45 days of experimental period. (iii) ***Ocimum sanctum* treated group-** rabbits were fed with normal diet and cholesterol as in the cholesterol group. In addition they received *Ocimum sanctum* extract throughout the experimental period. Treated groups were divided into 10mg, 25mg and 50mg, aqueous extract treatment groups. Blood was collected at regular intervals( at the end of 1,2,3,4<sup>th</sup> months). At the end of experimental period (4months), rabbits were anesthetized with anesthetic ether, aorta and liver were dissected out and perfused in chilled saline to remove blood from these organs. A part of the tissue was fixed in 10% formalin for histopathological studies. Tissues were homogenized using Teflon-glass homogenizer (Remi, India) at 4°C. 10% homogenate was prepared with saline-EDTA.

### **Determination of LDL-cholesterol and atherogenic Index (14)**

By using kit supplied by Biocon diagnostics, Bangalore, total cholesterol and Triglyceride content of the Blood was estimated. The value of Low density lipoprotein cholesterol (LDL-C) was derived from calculation. High density lipoprotein cholesterol (HDL-C) value and Very low density lipoprotein cholesterol (VLDL-C) value were subtracted from total serum cholesterol to obtain LDL cholesterol. Value of Atherogenic index was obtained by the ratio of Total cholesterol with that of HDL cholesterol.

### **Estimation of total cholesterol in tissue (15)**

To 0.1ml of tissue homogenate, 10ml of 0.05% FeCl<sub>3</sub> – CH<sub>3</sub>COOH reagent was added and mixed well and allowed to stand for 15 minutes. This was centrifuged at 3500 rpm for 10mins; 5ml supernatant was transferred to a clean dry test tube. 3ml concentrated sulfuric acid(H<sub>2</sub>SO<sub>4</sub>) was added, the contents were mixed and allowed to stand for 30 min. The colour developed was read at 560nm. Tissue cholesterol content was calculated using a standard graph.

### **Estimation of triglyceride content in Tissue (16)**

0.5ml of tissue homogenate was added to 3.5ml isopropanol. The contents were mixed and 2ml heptane and 1ml 0.04M H<sub>2</sub>SO<sub>4</sub> were added. After shaking, the phases were allowed to separate. Upper layer (0.2 ml) was transferred to a clean test tube, added with 2ml isopropanol, 0.6ml saponification reagent. Contents were mixed and allowed to stand at room temperature for 5 minutes. After adding 1.5ml sodium meta periodate and 1.5ml of 0.1% acetyl acetone in isopropanol, the tubes were placed in water bath at 60-70°C for 15 minutes. After cooling for 30 minutes, absorbance was read at 415nm. Triglyceride content of the tissue was calculated using a standard graph, and was expressed as mg per gm of tissue.

**Histopathological Studies**

A small portion tissue was fixed in 10% formalin, processed and embedded in paraffin. These paraffin blocks were cut into 5µm thick sections, which were processed and stained with haematoxylin and eosin stain. Histopathological evaluation was done under light microscope.

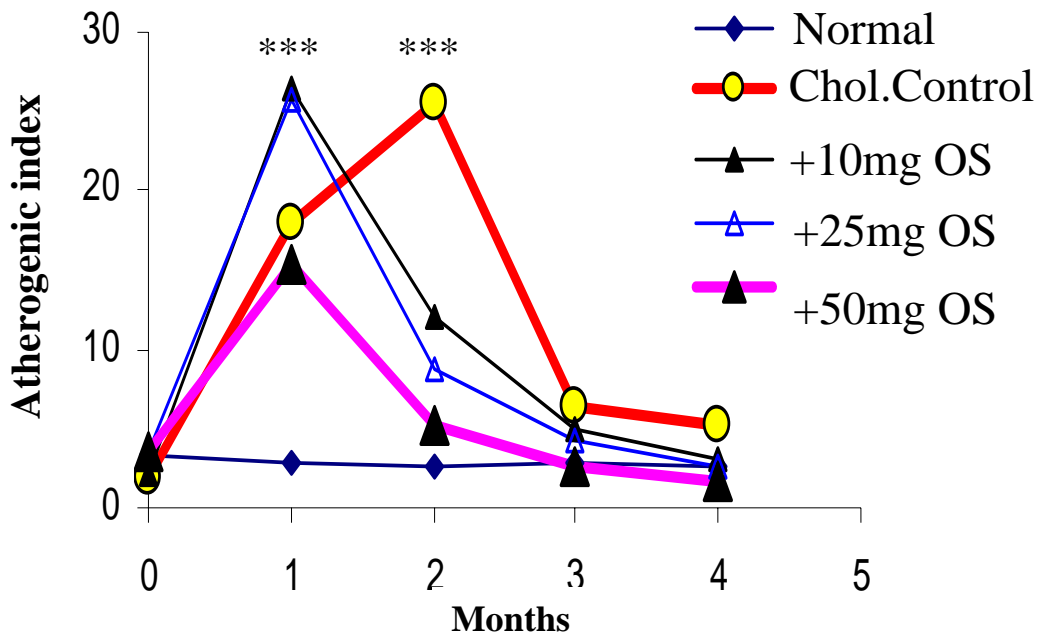
**Data Analysis**

Mean ± SEM values were calculated and statistical significance of different groups was evaluated with one-way ANOVA test followed by Bonferroni’s test.

**Results**

Atherogenic index (Total cholesterol/HDL-C)

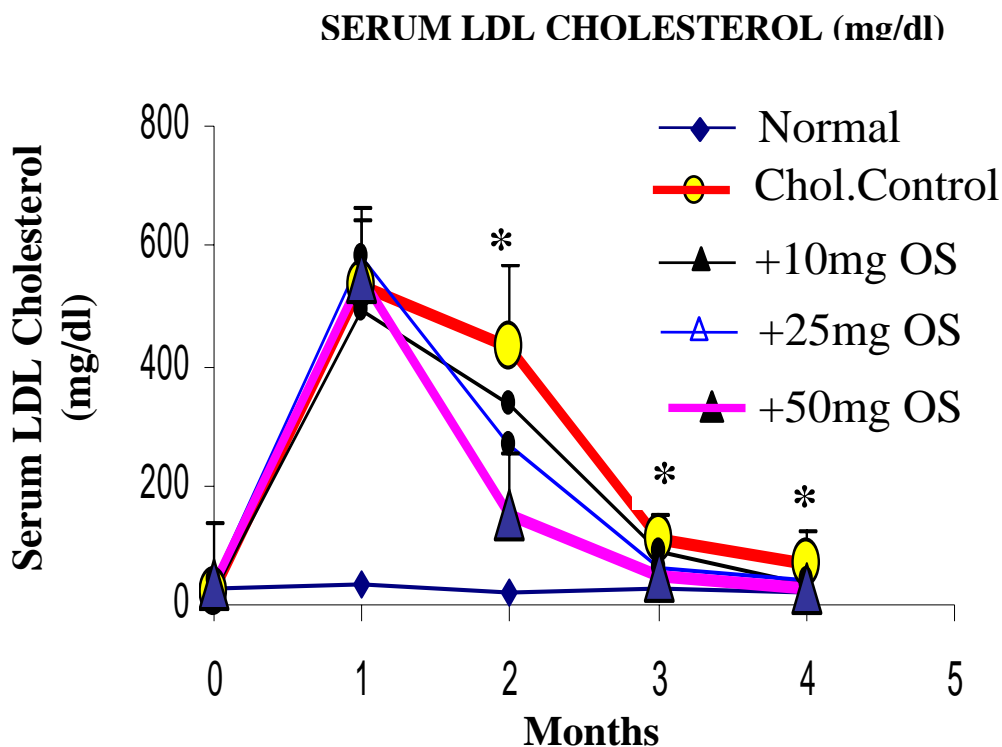
**ATHEROGENIC INDEX**



**Fig.2:** Atherrogenic index (total cholesterol/high density lipoprotein cholesterol) in different groups at the beginning and after 1,2,3,4 months after cholesterol treatment. Note there is a rapid and significant increase in the atherogenic index a month after the commencement of cholesterol treatment in all groups. There was a rapid and significant decrease in atherogenic index 15 days after cessation of treatment (2 months point). \*\*\* P<0.001.

Atherogenic index showed 6,9,9 and 5 fold increases following the cholesterol diet for a month period in cholesterol control group( $P<0.001$ ),ocimum sanctum 10mg/kg group( $P<0.001$ ),ocimum sanctum 25 mg/kg group( $P<0.001$ ) and ocimum sanctum 50mg/kg group( $P<0.001$ ) respectively (Fig 2).Fifteen days after cessation of cholesterol diet atherogenic index remained heigh in cholesterol control group(10 fold increase compared to normal control, $P<0.001$ ),where as ocimum sanctum treated groups showed only 5 fold(10 mg/kg group,  $P<0.001$ ),3 fold(25 mg/kg group, $P<0.001$ ) and 2 fold (50mg /kg group, $P<0.001$ ) increase in the atherogenic index.There was no differenc in the atherogenic index of all the groups after 1.5 and 2.5 months after cessation of cholesterol diet.

### Low Density Lipoprotein Cholesterol (LDL-C)



**Fig.3:** Serum low density lipoprotein cholesterol (LDL-C) in different groups before the commencement of cholesterol treatment (0 month) and at 1,2,3,4 months after the commencement of cholesterol treatment. Note there is a rapid increase in the serum LDL-C in all treated groups, rapid reversal of LDL-C in rats treated with 50 mg/kg body weight *ocimum sanctum* extract and gradual reversal of LDL-C in other groups.\* Cholesterol control vs 50 mg/kg *ocimum sanctum* treated group,  $P<0.05$ .

There was a 24-fold increase in the level of serum LDL-C in cholesterol control group during cholesterol feeding compared to control value. The increase in the LDL-C in 10mg/kg, 25mg/kg, and 50mg/kg *ocimum sanctum* treated groups are 23,15,and 15 folds respectively. After cessation of cholesterol diet there was a gradual decrease in the levels of LDL-C in cholesterol control group, whereas the *ocimum sanctum* leaf extract treated groups showed a sharp decrease.10,25 and 50 mg /kg *ocimum sanctum* reduced the LDL-C by 31%,53%,and 73% respectively when evaluated 15 days after cessation of cholesterol diet. At 1.5 months after cessation of cholesterol diet, the percentage reduction of LDL-C in 10,25, and 50 mg /kg group are 82.22%,89.8%,91.13% respectively.2.5 months after cessation of cholesterol diet, percentage reduction of LDL-C in 10, 25,and 50 mg/kg group are 93.29%,92.79%,95.28% respectively. At 2,3,4 months time 50mg *Ocimum sanctum* extract treated group showed a significant reduction in the LDL-C level (P<0.01, Fig.3).

Tissue Cholesterol

Cholesterol -mg/g wet tissue

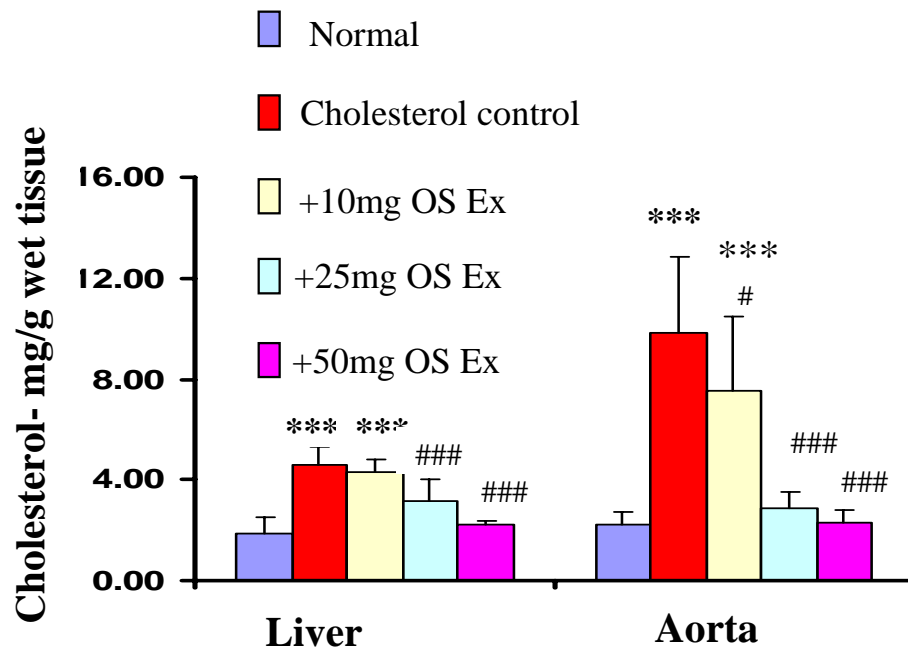
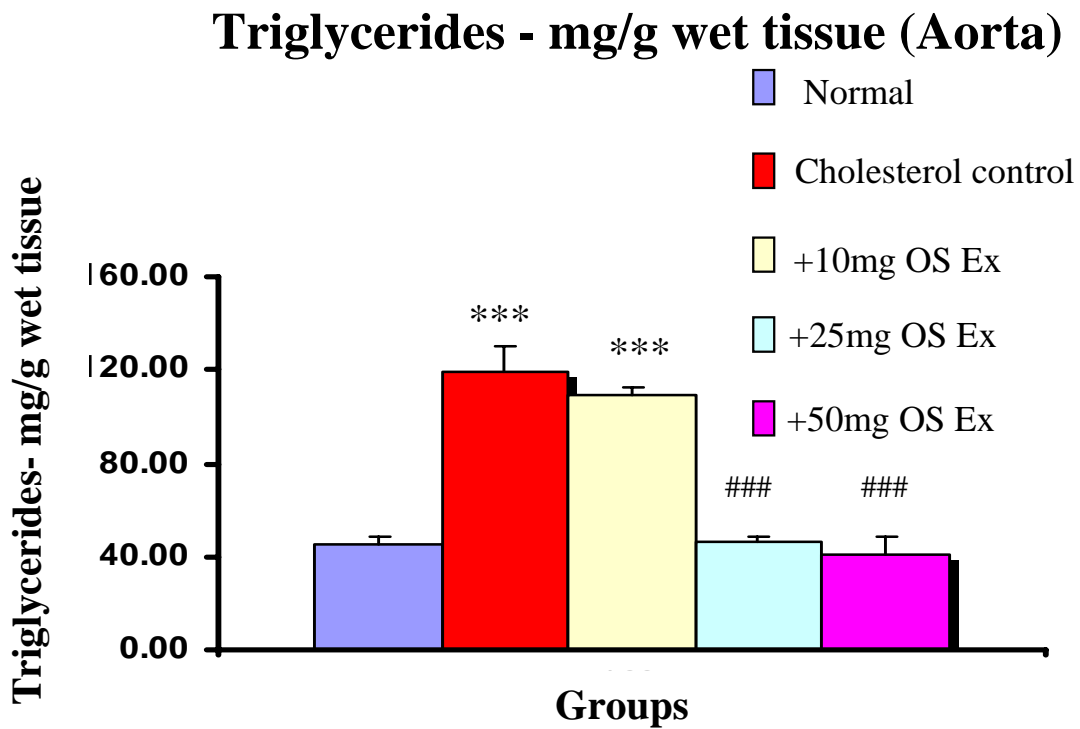


Fig.4: Cholesterol content in liver and aorta in different groups at the end of experimental period (4<sup>th</sup> month).Note there is a significant increase in the cholesterol level in liver and aorta in cholesterol fed and cholesterol+10mg/kg body weight *ocimum sanctum* extract treated rabbits compared to control rabbits(\*\*\*) ,P<0.001).Rabbits treated with cholesterol+ 25mg/kg body weight *ocimum sanctum* extract and cholesterol+50 mg /kg body weight *ocimum sanctum* extract showed a significant reduction in cholesterol level compared to cholesterol control group(###, P<0.001).

Liver and Aorta cholesterol assessed at the end of the experimental period has showed a significant high amount of cholesterol in rabbits fed with Cholesterol rich diet (cholesterol control group,  $4.6 \pm 0.2$  mg/g tissue of liver and  $9.83 \pm 0.3$  mg/g tissue of aorta). In liver there was 2 fold increases and in Aorta 5 fold rise in cholesterol content. 10, 25, and 50 mg/kg *ocimum sanctum* reduced the cholesterol by 6%, 35% and 52% ( $P < 0.001$ ) in liver tissue and by 23%, 70% and 76% ( $P < 0.001$ ) in aortic tissue. The 50mg *Ocimum sanctum* extract treated group showed normal cholesterol content both in liver and aorta ( $P < 0.01$ , Fig 4).

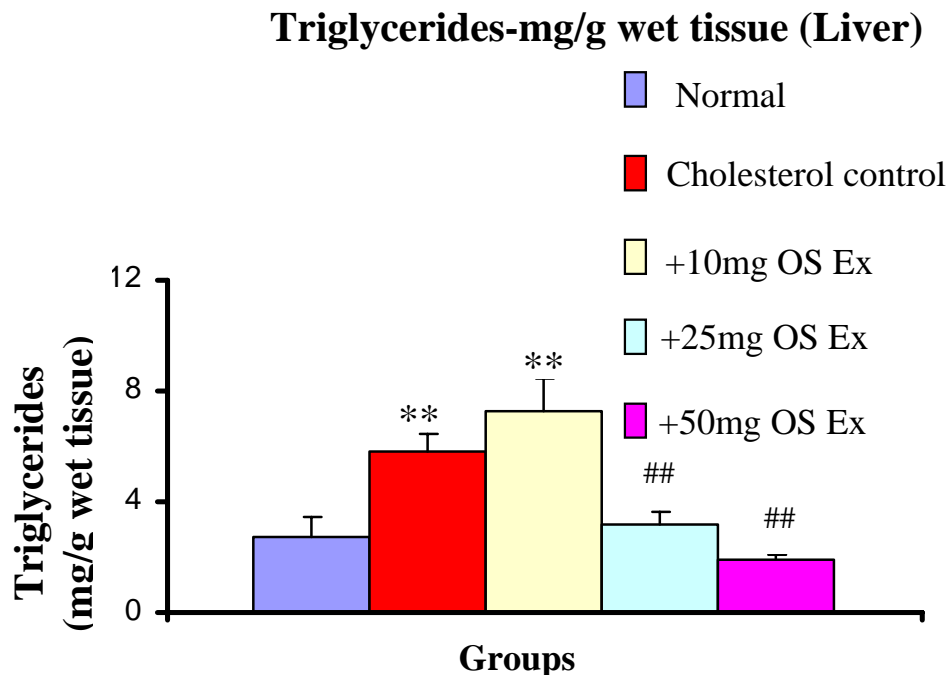
Triglycerides in aorta



**Fig.5:** Triglyceride content in aorta in different groups at the end of experimental period (4<sup>th</sup> month). Note there is a significant increase in the Triglyceride level in aorta in cholesterol fed and cholesterol+10mg/kg body weight *ocimum sanctum* extract treated rabbits compared to control rabbits(\*\*\*,  $P < 0.001$ ). Rabbits treated with cholesterol+ 25mg/kg body weight *ocimum sanctum* extract and cholesterol+50 mg /kg body weight *ocimum sanctum* extract showed a significant reduction in Triglyceride level compared to cholesterol control group(###,  $P < 0.001$ ).

Triglyceride content in aortic tissue was 20 fold more when compared to liver tissue. Cholesterol diet for first 45 days of experimental period brought 3-fold increase in the Triglyceride content of aorta (Fig.5).The *Ocimum sanctum* extract treated groups (25 and 50 mg/kg body weight) maintained normal triglyceride content( $46.0\pm 2.8$ , and  $41.0\pm 7.9$  mg/g wet tissue). *Ocimum sanctum* at the dose of 25, 50 mg /kg body weight significantly reversed the triglyceride content in the aorta (61.63% reduction in 25 mg/kg group,  $P<0.001$  and 65.54% reduction in 50 mg/kg body weight group, $P<0.001$ ).

### Triglycerides in Liver



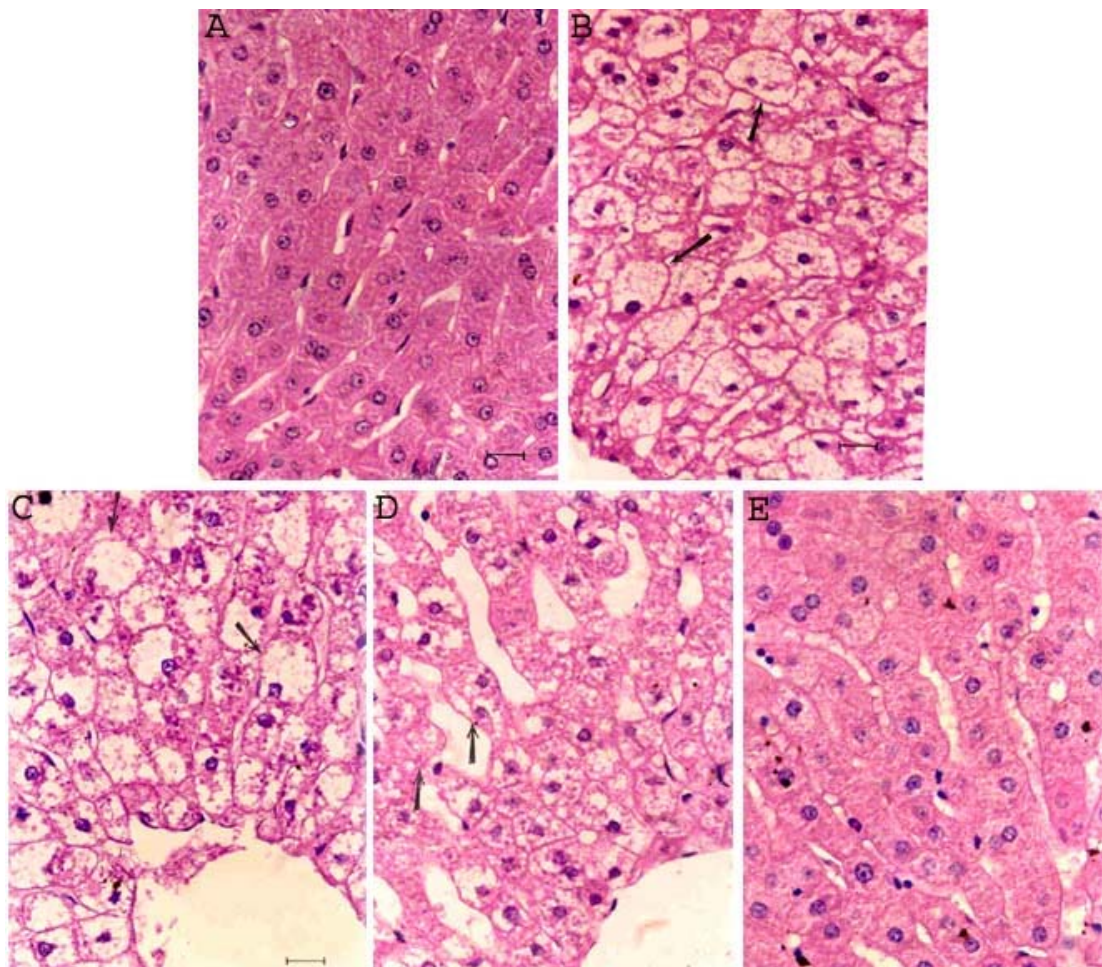
**Fig.6:** Triglyceride content in liver in different groups at the end of experimental period (4<sup>th</sup> month).Note there is a significant increase in the triglyceride level in liver in cholesterol fed and cholesterol+10mg/kg body weight *ocimum sanctum* extract treated rabbits compared to control rabbits(\*\*,  $P<0.001$ ).Rabbits treated with cholesterol+ 25mg/kg body weight *ocimum sanctum* extract and cholesterol+50 mg /kg body weight *ocimum sanctum* extract showed a significant reduction in Triglyceride level compared to cholesterol control group(##,  $P<0.001$ ).

Cholesterol diet for first 45 days of experimental period brought 2-fold increase in the Triglyceride content of liver (Fig.5).The *Ocimum sanctum* extract treated groups (25 and 50 mg/kg body weight) maintained normal triglyceride content( $3.2\pm 0.4$ , and  $1.9\pm 0.2$  mg/g wet tissue). *Ocimum sanctum* at the dose of 25, 50 mg /kg body weight significantly reversed the triglyceride content in the liver (44.82% reduction in 25 mg/kg group,  $P<0.01$  and 82.75% reduction in 50 mg/kg body weight group,  $P<0.01$ ).



### Histopathological changes in liver

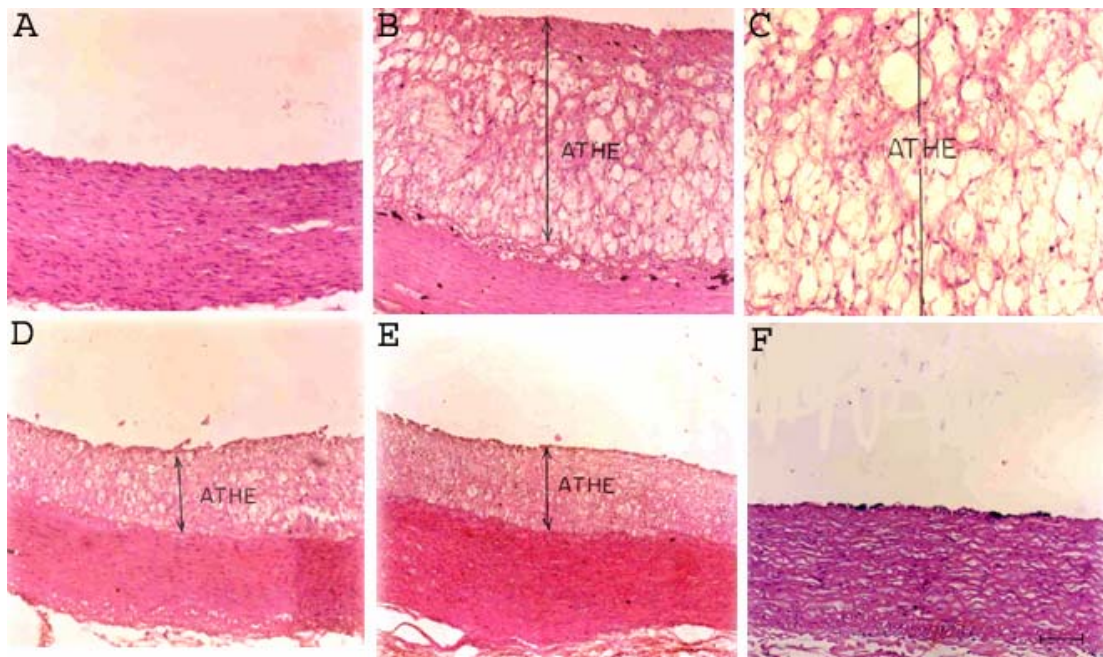
Photomicrographs of sections of liver of normal, cholesterol control and *Ocimum sanctum* extract treated rabbits revealed that Cholesterol diet for 45 days in control group led to fatty degenerative changes in the liver cells (Fig.7). Hepatocytes were loaded with fat droplets. The cells were remarkably hypertrophied with peripherally displaced nucleus. Pericellular fibrosis could also be seen in the section. In *Ocimum* treated groups similar changes can be observed in 10mg dose of extract. A significant decrease in fatty microvesicular formation was seen in 25mg and 50mg *Ocimum* extract treated groups.



**Fig.7:** Photomicrographs of liver tissue from control (A), Cholesterol control(B), *ocimum sanctum* leaf extract treated groups:10mg/kg(C),25mg/kg(D), and 50 mg/kg(E).Note the fatty degeneration( arrows) in cholesterol control and 10 mg/kg body weight *ocimum sanctum* treated groups. Liver tissue appears to be near to normal in 25 mg/kg body weight *ocimum sanctum* treated group(D) and normal in 50 mg/kg body weight *ocimum sanctum* treated group(E).Scale bar=20µm.

### Histopathological changes in aorta

Photomicrographs of cross section of thoracic aorta of normal, cholesterol control and *Ocimum sanctum* extract treated rabbits revealed that cholesterol feeding for 45 days resulted in the development of atheroma (Fig.8) Micrograph of normal aorta shows intima having thin monolayer of endothelial cells on muscular media. In cholesterol control intima was invaded by fibro fatty atheroma. Sections of aortas of *Ocimum sanctum* extract treated animals showed progressive regression of atheroma in a dose dependent manner. In 50mg/kg body weight *Ocimum* extract treated group 100% regression has taken place.



**Fig.8:** Photomicrographs of cross section of aorta from control(A), Cholesterol control(B), *ocimum sanctum* leaf extract treated groups:10mg/kg(D),25mg/kg(E), and 50 mg/kg(F).Photomicrograph C is the magnified view of atheroma (ATHE) seen in B. Note the atheroma ( ATHE ) in cholesterol control(B) , and its reduction in thickness in 10 mg/kg body weight *ocimum sanctum* (D),and in 25 mg/kg body weight *ocimum sanctum* treated groups(E). Arterial structure is normalized in 50 mg/kg body weight *ocimum sanctum* treated group (F).Scale bar=20 $\mu$ m.

### Discussion

The present study showed a hypolipidimic activity of *ocimum sanctum* extract. Aqueous extract of the plant given at the dose of 25, or 50 mg/kg body weight decreased the atherogenic index, serum LDL- Cholesterol, cholesterol and triglyceride content in liver and aorta in male albino rabbits. Histological study of liver tissue revealed hepatoprotective role of this plant extract. The plant extract also reversed the atherosclerosis in the aortic tissue. Data strongly suggestive of anti atherosclerotic and hypolipidimic properties of the *ocimum sanctum* plant extract.

Atherosclerosis, the primary cause for cardiovascular diseases, is a progressive multifactorial disease of arterial wall resulting mainly from hypercholesterolemia induced oxidative stress (17). Hypercholesterolemia, elevated plasma total cholesterol level and low-density lipoprotein cholesterol (LDL-C) constitute major risk factors for atherosclerosis. Hypercholesterolemia induces an increased production of reactive oxygen species and Lipid peroxidation. Free radical driven oxidative modification of LDL plays a key role in atherogenesis. Lipid peroxidation of PUFAs of LDL results in a number of cytotoxic lipid hydroperoxides and aldehydes which contribute to the initial endothelial cell damage that is thought to be the starting point of the whole process of atherosclerosis (18). Lipid peroxides activate several genes including vascular cellular adhesion molecule-1 (VCAM-1). VCAM-1 recruits monocytes and lymphocytes to the surface of endothelial cell, initiating the chronic inflammatory reaction that ultimately results in atherosclerosis (19).

In this study atherosclerosis in aorta of high cholesterol fed rabbits were effectively prevented by *Ocimum sanctum* extracts. The protective effect of *Ocimum sanctum* could be possible due to their hypolipidemic property. Significant reduction in lipid levels of blood, liver, aortic tissues clearly indicates their strong hypocholesterolemic and hypotriglyceridemic properties. Cholesterol feeding for 45 days has brought heavy accumulation of fats in liver and which induced fatty changes. High level of cholesterol and triglyceride had been found even after 3 months of discontinuation of cholesterol feed. This clearly indicates the poor mobilization of fats in liver. But *Ocimum sanctum* extract treated groups have showed the clearance of lipid and restoration of normal architecture in liver tissues.

Feeding atherogenic diet makes rabbits to build up long lasting stores of fats in their reticulo-endothelial system (20). Prolonged hypercholesterolemia has brought microvesicular fatty changes in hepatic cells. Dose dependent reduction of fatty changes in liver cells, tissue cholesterol and triglyceride content in *Ocimum sanctum* extract treated group further substantiate its hypolipidemic effect.

Hypercholesterolemia induces oxidative metabolic stress by elevating lipid profiles and depleting endogenous antioxidants. After discontinuing cholesterol feeding a slow rate of recovery towards normalcy was noticed in both antioxidant and lipid levels of control groups, which might have initiated the process of atherogenesis. The poor mobilization of cholesterol in liver has resulted in the accumulation of cholesterol. This becomes the source for circulating cholesterol leading to hypercholesterolemia even after the cessation of cholesterol feed and the progression of atheroma in aorta.

Fresh *Ocimum* leaves administration in normal albino rabbits has increased faecal sterol excretion, which indicated the increased hepatoenteric excretion of sterols [4]. It also inhibited cholesterol biosynthesis. Pharmacological active principles of *Ocimum sanctum* consists number of polyphenolic flavonoids (21,22). Polyphenolic flavonoids are cardioprotective antioxidants and they prevent coronary artery diseases by reducing plasma cholesterol levels or by inhibiting LDL oxidation, a process which play a key role in atherosclerosis (23). They also known to inhibit aortic smooth muscle cell proliferation, macrophage migration and are found to be antineoplastic, antiinflammatory antilipoperoxidant and metalchelators (24, 25). Hence *Ocimum sanctum* extracts have got strong anti-atherogenic properties. A significant reduction of liver cholesterol and triglyceride level indicates their efficient mobilization and excretion as fecal sterols. This brings significant reduction in the circulating LDL-C. Antioxidant and anti-lipidperoxidative properties of *Ocimum sanctum* and upregulation of endogenous antioxidant enzymes protected LDL-C from

oxidative modifications. These factors prevented the fat accumulation in aortic tissues and subsequent atherogenesis.

Present study clearly elucidate *Ocimum sanctum* as a efficient lipid lowering agent Hypolipidemic and lipid clearing active principles of this plant can be beneficial to man kind. Antioxidant action shielded LDL from oxidative modifications. Along with strong hypolipidemic effect *Ocimum* inhibited the atherogenesis.

### **Acknowledgements**

This work was supported by University Grant Commission of India vide Lr.No.FIP 99 SWRO/UGC Bangalore dated 26/10/1999 under faculty improvement programme in IX plan period. This work was carried out in Department of Biochemistry, KMC, MAHE, Manipal, Karnataka, India

### **References**

1. Satyavathi GV, Gupta KA, Tandon N (Edn.). *Ocimum* Linn. *Medicinal plants of India*, ICMR. New Delhi, 1987; 2: 354.
2. Rai V, Iyer U, Mani U V. Effect of tulasi (*Ocimum sanctum*) leaf powder supplementation on blood sugar levels, serum lipids in diabetic rats. *Plants Foods Hum Nutr* 1997;50:9.
3. Hussain EHMA, Jamil K, Rao M. Hypoglycemic, hypolipidemic and antioxidant properties of Tulsi (*Ocimum sanctum* Linn) on Streptozotocin induced Diabetes in rats. *Indian Journal of Clinical Biochemistry* 2001; 16[2]:190-194.
4. Angshula Sarkar, Lavania SC, Pandey DN, Pant MC. Changes in blood lipid profile after administration of *Ocimum sanctum* (Tulsi) leaves in the normal albino rabbits. *Indian J Physiol Pharmacol* 1994; 38[4] : 311-312.
5. Geetha S, Kedlaya R, Vasudevan D M. Superoxide and Hydrogen Peroxide Scavenging action of *Ocimum sanctum* extracts and their fractions. *Natural Product Sciences* 2003; 9(4): 223-225.
6. Geetha S, Kedlaya R, Vasudevan D M. Inhibition of lipid peroxidation by botanical extracts of *Ocimum sanctum*: *In vivo* and *in vitro* studies. *Life Sciences*, 2004; 76:21-28
7. Davies M J. Woolf N., Atherosclerosis: what is it and why does it occur? *Br Heart J*, 1993; 69:S3-S11.
8. Ridker P M, Genest J, Libby P. Risk Factors for Atherosclerotic Disease. A Text Book of Cardiovascular Medicine. Harcourt International Edition WB Saunders Company, Philadelphia 2001: 1010-1041
9. Witztum. JL, The Oxidation hypothesis of atherosclerosis. *The Lancet*, 1994; 344:793-795
10. Ganasoundari A, Uma Devi P, Rao BSS. Enhancement of bone marrow radioprotection and reduction of WR-2721 toxicity by *Ocimum sanctum*. *Mutation Research* 1998; 397: 303-312.

11. Pagalia DE, and Valentine WN. Studies on the quantitative characterization of erythrocyte peroxidase. *J.Lab. Clin. Med.*1967; 70:158-169.
12. Aebi H E, Catalase. *Methods in Enzymatic Analysis*. 1074; 3:273-28413. Friedwald WT, Levy R T, Friederickson DS. Estimation of plasma low density lipoprotein cholesterol concentration with out use of the preparative ultracentrifuge. *Clin.Chem*, 1972; 18:449-502.
14. Berg JE, Hostmark AT..Cardiovascular risk determination: discrepancy between total cholesterol evaluation and two compound laboratory indices in Norway. *Journal of Epidemiology and Community Health* 1994 ;48: 338-343
15. Varley H In:Gowenlock A.H(ed);Varley's practical clinical biochemistry, 4<sup>th</sup> edn; London. Heinemann Medical Book. 1967; 813.
16. Jose M; Barry F; Harry G, Simple Manual Procedure for Determination of Serum Triglycerides. *Clin.chem* 1975; 21:768-770.
17. Esterbauer H, Schmidt R, Hayn M, *Advances in Pharmacology* Edt. Sies H. Academic Press, London, 1997; 38:425
18. Steinberg D, Parthasarathy S, Carew TE, Khoo JC, Witztum JL. Beyond Cholesterol: Modification of low density lipoprotein that increase its atherogenicity. *N Engl J Med* **320**: 915-924, 1989.
19. Stix.G., Signal Jammer, *Scientific American* 2003 July:29-31.
20. Wissler RW ,Vasselinovitch D. Can Atherosclerotic Plaques Regress?Anatomic andBiochemicalEvidence from Nonhuman Animal Models. *The American Journal of Cardiology*1990; 65: 33F-40F.
21. Skaltsa H., Tzakou O., Singh M., Polyphenols of *Ocimum sanctum* from Suriname. *Pharmaceutical Biology* 1999;37(1): 92-94.
22. Norr H, Wagner H, New Constituents from *Ocimum sanctum*. *Planta Medica*1992; 58: 574.
23. Fuhrman B, Rosenblat M, Hayek T, Coleman R., Aviram M, Ginger extract consumption reduces plasma cholesterol, inhibits LDL oxidation and attenuates development of atherosclerosis in atherosclerotic apolipoprotein E- deficient Mice. *Journal of Nutrition* 2000; 130: 1124-1231
24. Alcocer F, Whitley D, Salazan Gonazalez JF, Jordan WD, Sellers MT, Eckhoff DE, Suzuki K, Macrae C, Bland KI, Quercetin inhibits human vascular smooth muscle cell proliferation and migration. *Surgery* 2002;131(2):198-204.
25. Mojzisova G, Kuchta M, Dietary Flavonoids and Risk of Coronary Heart Disease *Physiol Res* 2001; 50(6): 529-535.