

**ANTIHEPATOTOXIC ACTIVITY OF *TRICHOSANTHES CUCUMERINA* ON CARBON TETRACHLORIDE INDUCED LIVER DAMAGE IN RATS**

Sathesh Kumar S, Ravi Kumar B and Krishna Mohan G\*

Department of Pharmacognosy and Centre for Ethnopharmacology, University College of Pharmaceutical Sciences, Kakatiya University, Warangal 506009, India

**Summary**

The methanolic extract of *Trichosanthes cucumerina* Var *cucumerina* L. (cucurbitaceae) was evaluated for antihepatotoxic activity using carbon tetrachloride (CCl<sub>4</sub>) intoxication in rats. The toxic group which received only CCl<sub>4</sub> (1ml/kg of 50% carbon tetrachloride dissolved in olive oil) by subcutaneous (s.c) route had exhibited significant increase in serum alanine amino transferase (ALT), aspartate amino transferase (AST), alkaline phosphatase (ALP) and total bilirubin (TB) levels. It also caused significant ( $P < 0.001$ ) decrease in total protein levels. The groups received treatment of methanolic extract of *T. cucumerina* (TCME) at doses of 250mg/kg and 500mg/kg body weight per oral after CCl<sub>4</sub> intoxication had significantly reduced ( $P < 0.001$ ) the AST, ALT, ALP and total bilirubin levels when compared with toxic group. Significant increase in total protein (TP) and albumin (ALB) levels were also observed in the animals treated with the extract. The effects of TCME on the biochemical parameters were comparable with standard drug (silymarin 100mg/kg b.w.p.o). The animals that received TCME showed not only reduced hepatocellular degeneration but also signs of hepatocellular regeneration when compared to the liver of those exposed to CCl<sub>4</sub> intoxication alone. Thus the histopathological studies also supported the antihepatotoxic activity of the extract.

**Keywords:** CCl<sub>4</sub> induced liver injury, *Trichosanthes cucumerina*, antihepatotoxic activity, biochemical parameters, hepatocellular regeneration

\*Corresponding author

E.mail: drgkrishnamohan@yahoo.co.in

Mobile: +91-9849793783

## Introduction

Liver plays a pivotal role in regulating various physiological processes such as metabolism, secretion and storage. It involves in detoxification of various components of xenobiotics. Hence it is exposed to toxic substances and drugs absorbed from the intestine may consequently leads to the damage of liver. Apart from the toxins and drugs<sup>1</sup> the hepatic viral infections (Hepatitis A, B, C, D etc.) are the main causes of hepatic damage. Hepatocellular damage is also worsened by microbial infections of *Entamoeba histolytica*<sup>2</sup>. Despite of extensive medical research, no drug in modern medicine can be claimed to cure liver disorders. On the other hand globally, plant based drugs like *Silybium marinum*<sup>3</sup>, *Picrorhiza kurroa*<sup>4</sup>, *Phyllanthus emblica*<sup>5</sup> and *Phyllanthus amarus*<sup>6</sup> are experimentally proved and successfully used in the clinical treatment of liver disorders.

*Trichosanthes cucumerina* Var *cucumerina* L(cucurbitaceae) is a slender hispid climber distributed in various parts of India and also in Srilanka, tropical Himalaya, Malesia, Polynesia and N. Australia. It is one agent among the major constituents of important Ayurvedic preparations like *Gulgultiktakam Kāsayam*, *Mahatiktaka ghratam*, *Vajrakam kāsayam* and *Mahatiktaka kāsayam*. It is used as blood purifier, appetizer, digestive, germicidal and aphrodisiac<sup>7</sup>. Hypoglycemic<sup>8</sup> and antiinflammatory<sup>9</sup> activities of *T. cucumerina* were reported. It is also used traditionally in the treatment of intestinal disorders, liver disorders, concocted poisons and to cure diseases caused by pitta. In our present study we evaluated the restoration of biochemical parameters, recovery and regeneration of hepatic architecture, by using methanolic extract of *T. cucumerina*(TCME) against CCl<sub>4</sub> induced hepatotoxicity in rats.

## Materials and Methods

**Animals:** Male wistar albino rats(120-150g) and albino mice(15-20g) were purchased from Mahaveera Enterprises (Regn.No.146/1999/CPCSEA) (Hyderabad, India) and used for the studies. They were provided with standard laboratory diet and given tap water ad libitum. They were maintained at 27 °C (±2) with 12 hrs light and dark cycle throughout the period of experiment.

**Chemicals:** Silymarin was supplied as a gift sample by Micro Labs, Hosur , India. The solvents used were purchased from Merck India Ltd. (Mumbai). ALT, AST, ALP, TB and protein estimation kits were purchased from Span diagnostics, Surat, India.

**Preparation of plant extract:** *Trichosanthes cucumerina* Var *cucumerina* L(cucurbitaceae) was collected from Kolli Hills, Tirunellveli, Tamilnadu(India) and authenticated by the taxonomists of Sidha Research Institute Tirunellveli, Tamilnadu(India). The whole plant was washed in running tap water, shade dried and pulverized to a coarse powder by using a cutter mill. The methanolic extract of whole

plant of *Trichosanthes cucumerina* (TCME) was obtained by maceration technique by using 97% methanol. The methanol in crude extract was completely removed by evaporation using Rotavapour<sup>®</sup> (BÜCHI, Switzerland) under reduced pressure.

**Acute toxicity study:** Wistar albino mice were divided into five groups of six animals each. First group served as normal control. TCME was administered orally to different groups at the dose level of 250, 500, 1000 and 2000 mg/(kg p.o.) body weights. All animals were observed for toxic symptoms and mortality for 72 h.

**Antihepatotoxicity studies:** The experimental protocols were duly approved by the Institutional animal ethics committee. In this study female albino wistar rats weighing 150-220gm were taken and divided into five groups each consisting of six animals. Group I (control) received the vehicle alone (2% w/v acacia 1ml/kg body weight per oral) from day 4 -10. Group II (Toxic) received equal mixture of CCl<sub>4</sub> and olive oil (1ml/kg of 50% CCl<sub>4</sub> in olive oil) for day 1 and 3 by s.c route. Group III and IV were administered subcutaneously on day 1 and 3 and TCME at doses of 250 and 500mg/kg.b.w.p.o per day respectively for 7 days (from day 4 to 10). Group V (Standard) received silymarin (100mg/kg per day p.o.) from day 4-10 and CCl<sub>4</sub> (on day 1 and 3)<sup>10</sup>. The total duration of the study was 10 days and the administration of extract, standard, vehicle or CCl<sub>4</sub> were only once a day.

**Estimation of Biochemical Parameters:** The separated serum was used for the estimation of various biochemical parameters like ALT, AST<sup>11</sup> ALP<sup>12</sup>, TB<sup>13</sup>, TP and ALB<sup>14</sup> levels.

**Histopathological Studies:** The animals were sacrificed; livers were taken out and washed with normal saline (0.9%). Approximately 2-3 pieces of liver measuring 6cu.mm. size were cut and fixed in phosphate buffered 10% formaldehyde solution. After embedding in paraffin wax, thin sections of 5µm thickness of liver tissue were cut and stained with haematoxylin-eosin. The thin sections of liver were made into permanent slides and examined<sup>15</sup> under high resolution microscope with photographic facility and microphotographs were taken.

**Statistical analysis:** All data are expressed as mean ± S.D. The results were subjected to analysis of variance (ANOVA) followed by students *t*-test. *P* values of >0.05 were considered significant.

## Results

The acute toxicity study exhibited no mortality up to a dose level of 2000 mg/kg body weight. As per the ranking system European Economic Community (EEC) for acute oral toxicity, the LD<sub>50</sub> dose of 2000 mg/kg and above is categorized as unclassified (EC Directive 83/467/EEC, 1983).

The results obtained from the evaluation of biochemical parameters were presented in table 1. Rats treated with CCl<sub>4</sub> alone developed significant ( $P < 0.001$ ) liver damage and it was well indicated by elevated serum levels of hepatospecific enzymes like ALT ( $171.01 \pm 7.59$ ), AST ( $153.82 \pm 4.19$ ) and ALP ( $87.17 \pm 6.22$ ) when compared with control. A marked significant elevation in TB level ( $0.90 \pm 0.05$  mg/dl) was observed in the group received CCl<sub>4</sub> and they were significantly high when compared with control. The TP and ALB levels decreased considerably ( $P < 0.001$ ) in the toxic group.

The groups received TCME doses of 250 and 500 mg/kg body weight positively altered the biochemical parameters. The extract at a dose level of 500 mg/kg had exhibited a sharp decrease of the serum enzyme levels and were significant ( $P < 0.001$ ) when compared with toxic. The effect exhibited by this group was comparable with the standard group treated with silymarin (100 mg/kg b. w). The TP and ALB levels were significantly ( $P < 0.001$ ) increased in groups administered with TCME at doses of 250 and 500 mg/kg b.w. The increase in dose levels of TCME had exhibited an increase in efficacy which was reflected in the values of biochemical parameters.

The areas of necrosis and ballooning degeneration of hepatocytes were observed in the toxic group. The group of animals which received post treatment of TCME after CCl<sub>4</sub> intoxication exhibited decreased necrotic zones and hepatocellular degeneration. The histopathological (Figure.a,b,c) studies also supported the antihepatotoxic effect of TCME.

Table 1: Antihepatotoxic Activity of Methanolic Extract of *Trichosanthes cucumerina*

GROUPS	ALT (IU/l)	AST (IU/l)	ALP (KA/dl)	TB ( mg/dl)	TP (gm%)	ALB (gm%)
CONTROL	26.61± 1.33	48.60± 2.85	13.46± 1.45	0.14±0.02	3.50±0.11	2.67± 0.09
TOXIC	171.01±7.59 <sup>be</sup>	153.82±4.19 <sup>e</sup>	87.17±6.22 <sup>be</sup>	0.90±0.05 <sup>e</sup>	1.40±0.16 <sup>e</sup>	0.61±0.06 <sup>e</sup>
STANDARD	46.30± 4.69 <sup>e</sup>	59.37± 6.09 <sup>ac</sup>	32.34± 2.56 <sup>e</sup>	0.34±0.03 <sup>a</sup>	3.19±0.14 <sup>a</sup>	2.36±0.08 <sup>a</sup>
TCME 250	113.46±8.33 <sup>abe</sup>	97.28±5.50 <sup>ab</sup>	57.83±2.47 <sup>abe</sup>	0.68±0.02 <sup>abe</sup>	2.62±0.14 <sup>abe</sup>	1.45±0.08 <sup>abe</sup>
TCME 500	69.83±4.51 <sup>abe</sup>	78.34±6.05 <sup>ab</sup>	45.94±4.92 <sup>abe</sup>	0.39±0.04 <sup>ade</sup>	2.80±0.11 <sup>abe</sup>	1.87±0.15 <sup>abe</sup>

n=6, Values expressed in mean ± standard deviation. a =compared with toxic P<0.001, b =compared with standard P<0.001, c =compared with control P<0.01, d =compared with standard P<0.05, e =compared with control P<0.001

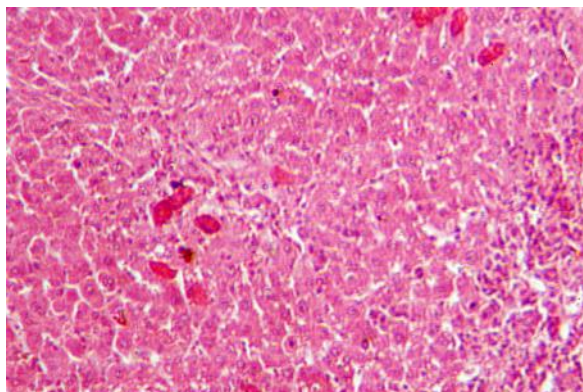


Figure a. Microphotographs of histopathological studies in rat showing normal hepatic architecture.

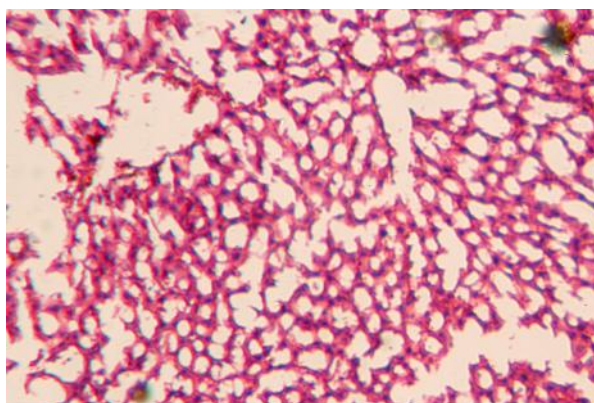


Figure b. Microphotographs of liver sections of rat treated with CCl<sub>4</sub> showing a high degree of hepatic degeneration.

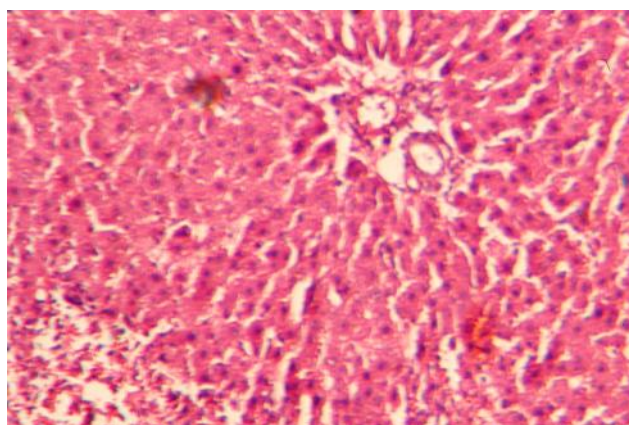


Figure c. Antihepatotoxic effect of methanolic extract of *Trichosanthes cucumerina* (500mg/kg) against CCl<sub>4</sub> induced hepatotoxicity in rat showing improved hepatic histology with regeneration of the hepatocytes.

### Discussion

Due to the metabolic activation of the hepatotoxic agent ( $\text{CCl}_4$ ), the liver cells are selectively intoxicated and maintained in semi-normal functional status.  $\text{CCl}_4$  is biotransformed by the cytochrome *P* 450 in the endoplasmic reticulum to produce trichloromethyl free radical ( $\bullet\text{CCl}_3$ ). Trichloromethyl free radical then combined with cellular lipids and proteins in the presence of oxygen to form a trichloromethyl peroxy radical. This may attack the lipids on the membrane of endoplasmic reticulum faster than trichloromethyl free radical. It also causes functional and morphological changes in the cell membrane. Furthermore, influx of extracellular  $\text{Ca}^{2+}$  ions into the cell is claimed to be an important step in cell death. The hepatic cells are involved in a variety of metabolic activities. They consist of higher concentrations of AST and ALT in cytoplasm and AST in particular exists in mitochondria<sup>16</sup>. Due to the damage caused to hepatic cells, the leakage of plasma membrane<sup>17</sup> will lead to increase in levels of hepatospecific enzymes in serum. The elevated serum enzyme levels like AST and ALT are indicative of cellular leakage and functional integrity of cell membrane in liver<sup>18</sup>. The antihepatotoxic effect of a drug can be evaluated by its capability to cure the injuries or to restore the normal hepatic physiology by regeneration mechanisms, which have been induced by a hepatotoxin. By nature, the liver possesses regenerative capacity and this should be considered in the experimental design by including a toxic control. The measurement of serum AST, ALT and ALP levels serves as a means for the indirect assessment of condition of liver. The post treatment of the animals with TCME with respect to intoxication with  $\text{CCl}_4$  reduced the AST, ALT and ALP levels when compared with the toxic group.

A high concentration of bilirubin in serum is an indication of increased erythrocyte degeneration rate. It also reflects the necrotic conditions of hepatocytes<sup>19</sup>. The oral administration of TCME at 500mg/kg b.w effectively reduced the serum TB levels.

The TP levels including albumin levels will be depressed in hepatotoxic conditions due to defective protein biosynthesis in liver<sup>20</sup>. The  $\text{CCl}_4$  intoxication causes disruption and disassociation of polyribosomes on endoplasmic reticulum and thereby reducing the biosynthesis of protein. The 5 days treatment with TCME at the doses of 250mg /kg and 500 mg/kg had considerably increased the protein levels whereas the toxic group had exhibited decreased levels.

The histopathological studies are direct means for assessing the antihepatotoxic activity of the drug. The hepatocellular degeneration were found to be more in the groups that received  $\text{CCl}_4$  alone, whereas the groups that received post treatment of TCME showed curative and regenerative properties. The histopathological studies also indicate the restoration of hepatic architecture. The rate of hepatocellular regeneration of TCME treated group was found to be more when compared with the toxic group, in which normal regeneration, if any occurs.

### Conclusion

The methanolic extract of *Trichosanthes cucumerina* var. *cucumerina* could effectively reduce the AST, ALT, ALP and TB levels and increase the protein levels in the

antihepatotoxic studies. The histopathological studies also substantiate the activity of the drug. Therefore the study scientifically supports the usage of this plant as antihepatotoxic agent

### Acknowledgement

The financial support provided by AICTE, New Delhi, India, to one of the authors, Sathesh Kumar S. is greatly acknowledged.

### References

1. Marina N. Hepatotoxicity of antiretrovirals: Incidence, mechanisms and management. *J. Hepat.* 2006; 44: S132–S139.
2. Sharma MP, Ahuja V. Amoebic liver abscess: Clinicians perspective. *Bomb. Hosp. J.* 1997; 39: 615-619.
3. Scott LND. A review of plants used in the treatment of liver disease: Part 1, *Alter. Med. Rev.* 1998; 3: 410-419.
4. Chander R, Kapoor NK, Dhawan BN. Effect of picroliv on glutathione metabolism in liver and brain of *Mastomys natalensis* infected with *Plasmodium berghei*. *Ind. J. Exp. Biol.* 1992; 30: 711-714.
5. Gulati RK, Agarwal S, Agrawal SS. Hepatoprotective studies on *Phyllanthus emblica* Linn. and quercetin. *Ind. J. Exp. Biol.* 1995; 33: 261–268.
6. Wongnawa M, Thaina P, Bumrungwong N, Rattanapirun P, Nitiruangjaras A, Muso A, Prasarthong V. The protective potential and possible mechanism of *Phyllanthus amarus* Schum. & Thonn. aqueous extract on paracetamol-induced hepatotoxicity in rats. *Songklanakarin J. Sci. Tech.* 2006; 28: 551-561.
7. Sivarajan VV, Indra B. *Ayurvedic drugs and their plant sources.* Oxford and IBH Publishing Co. Pvt.Ltd., New Delhi, 1994.
8. Kar A, Choudhary BK, Bandyopadhyay NG. Comparative evaluation of hypoglycaemic activity of some Indian medicinal plants in alloxan diabetic rats. *J. Ethnopharmacol.* 2003; 84: 105-108.
9. Kolte RM, Bisan VV, Jangde CR, Bhalerao AA. Antiinflammatory activity of root tubers of *trichosanthes cucumerina* Linn. In mouse hind paw oedema induced by carageenin. *Ind. J. Indigen. Med.* 1996; 18: 117-121.
10. Rasheeduz Zafar S, Mujahid A. Anti-hepatotoxic effects of root and root callus extracts of *Cichorium intybus* L. *J. Ethnopharmacol.* 1998; 63: 227–231.
11. Reitman S, Frankel S. A colorimetric method for the determination of serum glutamic oxaloacetic acid and glutamic pyruvic transaminases. *American J. Clinic. Path.* 1957; 28 56–63.
12. Kind PRN, King EJJ. Estimation of plasma phosphatase by determination of hydrolyzed phenol with aminopyrines. *J. Clinic Path.* 1954; 7: 332
13. Jendrassik, L. Grof P. Simplified photometric methods for. The determination of the blood bilirubin. *Biochem.* 1938; Z 297: 81-89.
14. Reinhold JG. In: Reiner, M. eds. *Standard Method in Clinical Chemistry*, vol. I. Academic Press, New York, 1953.
15. Valeer J D. Liver tissue examination. *J. Hepat.* 2003; 39: S43–S49.
16. Wells FE. Tests in liver and biliary tract disease. In: Gowenlock, H.A. eds. *Varley's Practical Clinical Biochemistry.* CRC Press, Florida. 1988.



17. Zimmerman HJ, Seef LB. Enzymes in hepatic disease. In: Goodly, E.I. eds. Diagnostic Enzymology. Lea and Febiger, Philadelphia. 1970.
18. Drotman RB, Lawhorn GT. Serum enzymes as indicators of chemical-induced liver damage. *Drug. Chem. Tox.* 1978;1: 163–171.
19. Singh B, Saxena AK, Chandan, BK, Anand KK, Suri OP, Suri KA, Satti NK. Hepatoprotective activity of verbenalin on experimental liver damage in rodents. *Fitoterapia* 1998; 69: 135–140.
20. Clawson GA. Mechanism of carbon tetrachloride hepatotoxicity. *Path. Immunopath. Res.*1989; 8: 104–112.