

Investigation of Acute Liver Toxicity and Anti-Inflammatory Effects of *Artemisia Austriaca* J. Jacq.

**Ufuk Mercan^a, Ahmet Cihat Öner^a, Hatice Öntürk^b, Nureddin Cengiz^c,
Remzi Erten^d, Fevzi Özgökçe^e, Hanefi Özbek^{f*}**

^a *Yüzüncü Yıl University, Faculty of Veterinary, Department of Pharmacology-Toxicology, Van-Turkey*

^b *Bitlis Eren University, Health College, Bitlis-Turkey,*

^c *Yüzüncü Yıl University, Medical School, Dep. of Histology-Embryology, Van-Turkey,*

^d *Yüzüncü Yıl University, Medical School, Department of Pathology, Van-Turkey.*

^e *Yüzüncü Yıl University, Faculty of Arts and Sciences, Department of Biology, Van-Turkey*

^f *Yüzüncü Yıl University, Medical School, Department of Pharmacology, Van-Turkey.*

Summary

The aim of this study was to investigate hepatoprotective and anti-inflammatory activities of *Artemisia austriaca* J. Jacq. essential oil (AA). *Artemisia* groups were injected AA in doses of 0.05 mL/kg (AA-I), 0.1 mL/kg (AA-II) and 0.2 mL/kg (AA-III) in both inflammatory and hepatotoxicity experiments. The hepatotoxicity was induced by carbon tetrachloride (CCl₄) administration. *Artemisia* did not have an anti-inflammatory effect matching to that of control group at any doses. It was found that reduction in inflammation was 96.62% with indomethacin, 5.71% with AA-I, 10.54% with AA-II and 31.37% with AA-III. AA-I significantly reduced the serum alanine aminotransferase and aspartate aminotransferase levels when compared to the CCl₄ group. The histopathological findings showed a significant difference between the AA-I and CCl₄ groups. The results showed that *Artemisia austriaca* J. Jacq. had considerable hepatoprotective activity while it did not show an anti-inflammatory activity.

Key Words: *Artemisia austriaca* J. Jacq., anti-inflammatory activity, hepatoprotective activity, rat.

*Corresponding author: hanefiozbek@hotmail.com (Dr. Hanefi Özbek) Fax:+90 432 216 83 52

Introduction

Artemisia austriaca J. Jacq. (AA), a member of the compositae family, is a perennial plant which grows up to 40-120 cm height. *Artemisia* species are widely distributed in Europe, Asia, North Africa and North America. This plant grows widely in Middle and East Anatolia (1,2). *Artemisia* species are used as folk medicine due to their hepatoprotective, antimalarial, antiparasitic, antibacterial, diuretic, expectorant and anti-icteric activities (2-4).

Cha et al reported that essential oil of *Artemisia feddei* acts as an antibacterial agent (5). Sayyah et al demonstrated anticonvulsant activity of *Artemisia dracunculus* L. essential oil (6). Li et al showed that the essential oil of *Artemisia annul* L. could induce apoptosis of cultured hepatocarcinoma cells SMMC-7721 (7). Remberg et al reported that a nasal spray formulation containing an extract characterised by a mixture of essential oils and flavonols from the *Artemisia abrotanum* L. genotype "Tycho", appears to be clinically useful and suitable for the prophylactic and therapeutic management of patients with allergic rhinitis and adjuvant symptoms (8). Masotti et al showed that the volatile components of the aerial parts of *Artemisia molinieri* have shown interesting antioxidant activities on the basis of alpha-tocopherol as reference compound (9). Some researches showed analgesic, antipyretic and anti-inflammatory activity of the essential oil of *Artemisia caerulea* subsp. gallica (10).

The effectiveness of *Artemisia species* in hepatotoxicity has been especially emphasized among traditional claims (3). Hence, in the present study we studied *Artemisia austriaca* J. Jacq. essential oil for their above mentioned properties and anti-inflammatory activity.

Materials and Methods

Plant material

Artemisia austriaca J. Jacq. was collected from the vicinities of Çaldıran-Van in July, 2007. Taxonomic identity of the plant was confirmed by Dr. F. Özgökçe, a plant taxonomist in the Department of Biological Sciences, Yüzüncü Yıl University, Van-Turkey. The plant specimens with their localities and the needed other field records were written and enumerated. They were pressed, dried according to herbarium techniques and identified by Flora of Turkey (Davis, 1986). All of the plant specimens were kept at the herbarium of Yüzüncü Yıl University (VANF Nr. 13193).

Dried leaves were ground in electrical mill and boiled in Clevenger (Ildam, Turkey). The essential oil collected in the instrument was taken into tubes and productivity for essential oil was calculated as 0.4 % (w/v).

Animals

Female and male Sprague-Dawley rats weighing 140-240 g were used in these experiments. The animals were housed at room temperature (20 ± 2 °C) in standard cages with standard pellet food and water *ad libitum*, in rooms lit in a rhythm of 12 h light, 12 hours dark and kept under controlled environment following the standard operating procedures of the animal house with approval of animal ethics committee. Prior to administration of the drugs, the animals were fasted for 18 h with free access to drinking water.

Chemicals

Lambda-carrageenan Type IV, indomethacin and silibinin were obtained from Sigma (Steinheim, Germany), carbon tetrachloride (CCl₄) was obtained from Merck (Darmstadt, Germany) and olive oil was obtained from Fluka (Steinheim, Germany). Lambda-carrageenan was dissolved in distilled water (w/v), silibinin and indomethacin were dissolved in ethyl alcohol (w/v), CCl₄ was dissolved in olive oil (1:1) (v/v).

Anti-inflammatory activity

The method of Winter et al with slight modification was used (11). Thirty rats of either sex were divided into five groups of six animals each. Inflammation of the hind paw was induced by injecting 0.05 mL fresh lambda-carrageenan (phlogistic agent) into the subplantar surface of the right hind paw. The experimental groups were as follows (n=6):

- Group 1: Isotonic saline solution (0.9 % NaCl), 0.1 mL, po,
- Group 2: Indomethacin (3 mg/kg), ip,
- Group 3: AA-I (0.05 mL/kg), ip,
- Group 4: AA-II (0.10 mL/kg), ip,
- Group 5: AA-III (0.20 mL/kg), ip,

The dose of indomethacin has been chosen according to Rimbau et al (12). These doses of the extract utilized in the current study have been chosen according to Morán et al Sayyah et al (6,10). The measurement of foot volume was accomplished by displacement technique using a plethysmometer (Ugo Basile 7140 plethysmometer, Italy), immediately before and three hours after the injection. The inhibition percentage of the inflammatory reaction was determined for each animal by comparison with controls and calculated by the formula (13):

$$I\% = [(1-(dt/dc)] \times 100$$

where *dt* is the difference in paw volume in the drug-treated group and *dc* is the difference in paw volume in the control group.

Hepatoprotective activity

The CCl₄ model described by Handa&Sharma (14) and Shenoy et al (15) was used for scheduling the dose regimen. Intraperitoneal injection of 0.8 mL/kg carbon tetrachloride diluted in olive oil (1:1 dilution) was employed for inducing acute liver toxicity. The experimental groups were as follows (n=6):

- Group 1: Isotonic saline solution (0.9 % NaCl), 0.1 mL,
- Group 2: CCl₄:olive oil (1:1) (0.8 ml/kg), ip,
- Group 3: Silibinin 50 mg/kg and CCl₄:olive oil (1:1) (0.8 mL/kg),
- Group 4: AA-I (0.05 mL/kg) and CCl₄:olive oil (1:1) (0.8 mL/kg),
- Group 5: AA-II (0.10 mL/kg) and CCl₄:olive oil (1:1) (0.8 mL/kg),
- Group 6: AA-III (0.20 mL/kg) and CCl₄:olive oil (1:1) (0.8 mL/kg).

The doses of the AA utilized in the current study have been chosen according to Morán et al and Sayyah et al (6,10). The dose of the silibinin utilized in the current study has been chosen according to Horváth et al (16). All injections were applied once a day for seven days, intraperitoneally. Carbontetrachloride and AA, CCl₄ and silibinin were applied using different injectors. All the animals were observed daily and any dead animals were subjected to post-mortem examination to find the cause of death. At the end of the treatment (8th day), blood samples were collected by direct cardiac puncture and the serum was used for the assay of marker enzymes, aspartate aminotransferase (AST) and alanine aminotransferase (ALT).

Body weights of the rats were measured once a day during eight days. Daily changes in body weights as percentages were recorded. The percentage of daily changes in body weights was calculated according to the following formula:

$$\text{Change in body weights as percentage} = 100 \times (\text{Weight}_n - \text{Weight}_{\text{initial}}) / \text{Weight}_{\text{initial}}$$

Weight_{initial}: measurement of first day.

Weight_n: measurement in 2., 3., ... 8. days.

The serum AST and ALT concentrations were determined with a commercial kit (Vitros) by Vitros DT60-II Autoanalyzer (USA, Rochester-New York). The livers of the experimental animals were extracted after killing the animals by cervical dislocation and fixed in 10% neutral buffered-formalin prior to routine processing in paraffin-embedded blocks. Sections (4 μ m thick) were cut and stained using Hematoxylin-eosin (HE) stain. Histological damage was expressed using the following score system; 0:absent; +:mild; ++:moderate; +++:severe.

Statistical analysis

All data were represented as mean \pm standard error of the mean (SEM) or as percentages. Analysis of variance (ANOVA) was used for the statistical analysis of data. Dunnett's test, Tukey's HSD test (Tukey's honestly significant difference test) and LSD test (least significant difference test) were used for determining significance. Results with $p < 0.05$ were considered as statistically significant.

Results

Anti-inflammatory activity

Table 1 shows the results on anti-inflammatory effect of intraperitoneally administered AA on carrageenan paw oedema in rats. None of the doses of AA caused a significant reduction in paw oedema. There was no difference between the effects of AA at three doses ($p > 0.05$). As seen in Table 1, indomethacin (reference drug) produced a significant inhibition (96.62 %). It was found that reduction in the inflammation was 5.71% with AA-I, 19.54% with AA-II and 31.37% with AA-III.

Table 1. Effects of AA on carrageenan-induced hind paw oedema ($n=6$).

Groups	Dose	Paw edema (mL %)	Inhibition (%)
Control (ISS)	0.1 mL	0.848 \pm 0.053	-
Indomethacin	3 mg/kg	0.029 \pm 0.048 ^a	96.62
AA-I	0.05 mL/kg	0.800 \pm 0.093 ^b	5.71
AA-II	0.10 mL/kg	0.759 \pm 0.105 ^b	10.54
AA-III	0.20mL/kg	0.582 \pm 0.145 ^b	31.37
<i>F/p value</i>		<i>11.620 / 0.000</i>	

The values represent the mean \pm S.E.M. (standard error of the mean). ED₅₀: 0.1474 mL/kg.

Post-hoc Tukey's HSD (honestly significant difference) test:

a : $p < 0.05$ with respect to the control (ISS) group,

b : $p < 0.05$ with respect to the indomethacin group.

Hepatoprotective activity

Levels of serum AST and ALT were markedly elevated in CCl₄ treated animals compared to control animals, as shown in Table 2. Administration of silibinin at a dose of 50 mg/kg remarkably prevented CCl₄-induced elevation of serum enzymes. AA treated group (0.05 ml/kg) had significantly lower levels of AST and ALT when compared with the CCl₄:olive oil group. But administration of AA at doses of 0.10 mL/kg and 0.20 mL/kg did not reduce CCl₄-induced elevation of serum enzymes.

Table 2. Effect of AA on serum AST and ALT levels ($n=6$).

Groups	ALT	AST
	Serum (U/L)	Serum (U/L)
Control (ISS)	38.08 ± 4.54	149.17 ± 11.53
CCl ₄	994.57 ± 142.98 ^a	1890.29 ± 251.14 ^a
Silibinin + CCl ₄	154.86 ± 29.20 ^b	554.00 ± 60.48 ^b
AA-I + CCl ₄	666.67 ± 146.11	521.33 ± 123.77 ^b
AA-II + CCl ₄	2323.27 ± 1357.00 ^{ac}	1937.60 ± 1023.04 ^{acd}
AA-III + CCl ₄	2444.00 ± 1721.63 ^{ac}	1584.00 ± 707.65 ^{acd}
<i>F/p Value</i>	<i>3.090 / 0.021</i>	<i>5.223 / 0.001</i>

The values represent the mean ± S.E.M. (standard error of the mean).

Post-hoc LSD (least significant difference) test and Dunnett test:

a: $p < 0.05$ with respect to control (ISS) group,

b: $p < 0.05$ with respect to CCl₄ group,

c: $p < 0.05$ with respect to silibinin group,

d: $p < 0.05$ with respect to AA-I group.

Histopathological examination

In control group (ISS), liver sections showed normal hepatic parenchyma and stroma. Cell apoptosis was not observed in this group. Liver hepatocyte cords, sinusoids and stroma were histologically normal.

Table 3. Histopathological changes in the liver of rats.

Groups	Microscopic Observation			
	Ballooning deg. and steatosis	Apoptosis and/or necrosis	Bridging necrosis	Average score*
Control (ISS)	0	0	0	0/6=0.00
CCl ₄	15	14	13	42/6=7.00
Silibinin	7	8	4	19/6=3.17
AA-I	8	8	8	24/6=4.00
AA-II	11	10	12	33/6=5.50
AA-III	12	11	13	36/6=6.00

* Average score = Total score / n

In carbon tetrachloride treated liver, drastic alterations were observed. Histopathological examination demonstrated that CCl₄ (compared to ISS control group) induced ballooning degeneration, centrilobular necrosis, bridging necrosis and apoptosis (acidophilic change) in hepatocytes (Table 3). Ballooned hepatocytes were of different sizes and much larger than normal hepatocytes and occasionally appeared as confluent areas (Fig. 1).

Artemisia austriaca essential oil (AA-I) or silibinin treated livers showed significant recovery. These changes were minimized by AA-I or silibinin treatment (Fig. 2). AA-II and AA-III treated livers did not show significant recovery (Fig. 3-4). One rat died in AA-II group and two rats died in AA-III group during the study.

The effects of AA on the body weights of CCl₄-intoxicated rats were as follows:

Group 1: Isotonic saline solution (0.9 % NaCl): 9.17 %,

Group 2 (CCl₄:olive oil): -13.50 %,

Group 3 (silibinin + CCl₄:olive oil): -11.89 %,

Group 4 (AA-I + CCl₄:olive oil): -9.69.

Group 5 (AA-II + CCl₄:olive oil): -10.48.

Group 6 (AA-III + CCl₄:olive oil): -11.36.

The daily body weight changes as percentages indicated that CCl₄ group had a significant reduction in weight compared to the control group. This reduction was also observed in AA and silibinin groups.

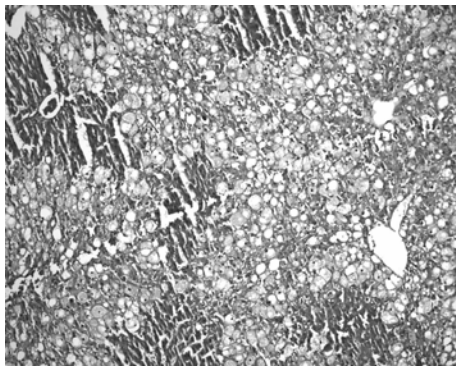


Figure 1. Numerous ballooned hepatocytes are seen in the liver in CCl₄-induced hepatotoxicity. (HE stain, original magnification, x100).

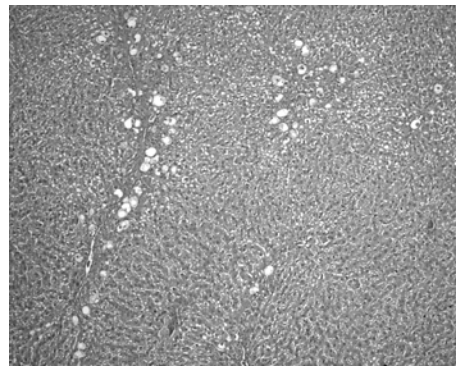


Figure 2. A few ballooned hepatocytes are seen in the liver of the AA-I group (HE stain, original magnification, x100).

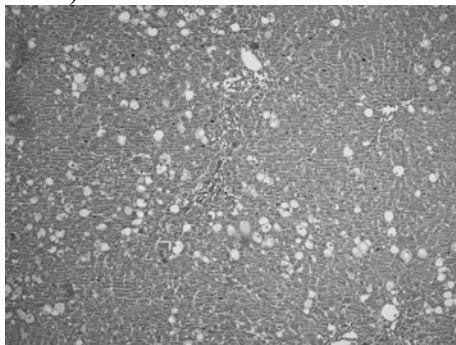


Figure 3. Numerous ballooned hepatocytes are seen in the liver of the AA-II group (HE stain, original magnification, x100).

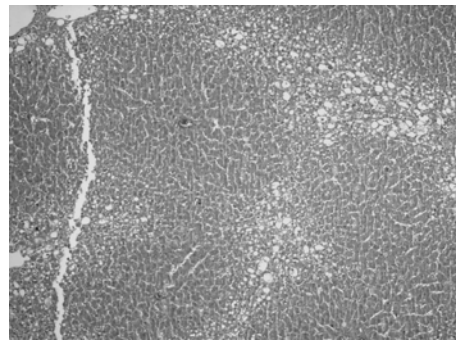


Figure 4. Numerous ballooned hepatocytes are seen in the liver of the AA-III group (HE stain, original magnification, x100).

Discussion

The effectiveness of *Artemisia austriaca* J. Jacq. in hepatotoxicity has been especially emphasized among traditional claims (3). The results showed that essential oil of *Artemisia austriaca* J. Jacq. has hepatoprotective effect at the dose of 0.05 mL/kg, but it has not anti-inflammatory effect at any doses. Other studies have demonstrated that several compounds were isolated and identified such as 1,8-cineole, chamazulene, alpha-terpineol, alpha-phellandrene, alpha-thujone, alpha-terpinyl acetate, borneol, beta-caryophyllene, camphor, terpinen-4-ol, cis-chrysanthenol, borneol, trans-beta-farnesene, yomogi alcohol, alpha-humulene oxide, beta-pinene,

capillene from the essential oil of *Artemisia species* (5, 17, 18). The hepatoprotective effect of the AA at the dose of 0.05 mL/kg may be due to one or more of the content listed above. *Artemisia austriaca* did not show any improvement in liver toxicity at doses of 0.10 mL/kg to 0.20 mL/kg which were even higher than the previous dose. In addition serum AST and ALT levels were higher than the CCl₄ group. This may be due to administration of doses higher than the toxic dose which is unknown to us. This is the first experimental study with the volatile oil of *Artemisia austriaca* J. Jacq; no previous study reported before. Therefore we preferred the doses used in two previous studies with two different *Artemisia species* (6,10). It may be more appropriate to use doses lower than 0.05 ml/kg in subsequent studies with this species. To be more accurate acute and chronic toxicity studies could help to determine therapeutic range. Morán et al showed that the essential oil of *Artemisia caerulescens* subsp. gallica possess anti-inflammatory properties (10). Our results are opposite to the above mentioned article. The inconcordance of their therapeutic effects of *Artemisia caerulescens* subsp. gallica and *Artemisia austriaca* J. Jacq could have been resulted from different components or different ratios of their constituents in their essential oils.

It is concluded that the essential oil of *Artemisia austriaca* J. Jacq. has a hepatoprotective effect, but it does not have an anti-inflammatory effect. The results of the present study support the traditional use of *Artemisia austriaca* J. Jacq. in hepatotoxicity. Further studies are needed to better evaluate this activity and the potential of *Artemisia austriaca* J. Jacq.

References

1. Akgül A. *Spices Science & Technology*. First ed. Ankara-Turkey. Society of Food Technology Publishing, Nr:15, 1993, pp: 135-137.
2. Baytop T. *Therapy with Medicinal Plants in Turkey*. 2nd ed. Istanbul-Turkey, Nobel Tip Kitapevleri, 1999, pp: 313-315.
3. Öztürk Y, Başer KHC, Aydın S. Hepatoprotective (antihepatotoxic) plants in Turkey. Proceedings of the 9th Symposium on Plant Drugs Eskişehir-Turkey, 16-19 May 1991; pp: 40-50.
4. Pamuk A. *The Encyclopedia of Herbal Medicine*. Pamuk Yay. ve Matb: Istanbul-Turkey, 1998; p: 674.
5. Cha JD, Jung EK, Kil BS, Lee KY. Chemical Composition and Antibacterial Activity of Essential Oil from *Artemisia feddei*. J Microbiol Biotechnol 2007; 17(12):2061-2065.
6. Sayyah M, Nadjafnia L, Kamalinejad M. Anticonvulsant activity and chemical composition of *Artemisia dracunculus* L. essential oil. J Ethnopharmacol 2004; 94(2-3):283-287.
7. Li Y, Li MY, Wang L, et al. Induction of apoptosis of cultured hepatocarcinoma cell by essential oil of *Artemisia annul* L. Sichuan Da Xue Xue Bao Yi Xue Ban 2004; 35(3):337-339.
8. Remberg P, Björk L, Hedner T, Sterner O. Characteristics, clinical effect profile and tolerability of a nasal spray preparation of *Artemisia abrotanum* L. for allergic rhinitis. Phytomed 2004; 11(1):36-42.
9. Masotti V, Juteau F, Bessière JM, Viano J. Seasonal and phenological variations of the essential oil from the narrow endemic species *Artemisia molinieri* and its biological activities. J Agric Food Chem 2003; 19;51(24):7115-7121.
10. Morán A, Martín ML, Montero MJ, et al. Analgesic, antipyretic and anti-inflammatory activity of the essential oil of *Artemisia caerulescens* subsp. gallica. J Ethnopharmacol 1989; 27(3):307-317.
11. Winter CA, Risley EA, Nuss GW. Carrageenin-induced edema in hind paw of the rats as an assay for antiinflammatory drugs. Proc Soc Exp Biol Med 1962; 111:544-547.
12. Rimbau V, Cerdan C, Vila R. Antiinflammatory activity of some extracts from plants used in the traditional medicine of North-African countries (II). Phytother Res 1999; 13:128-132.

13. Kouadio F, Kanko C, Juge M, et al. Analgesic and antiinflammatory activities of an extract from *Parkia biglobosa* used in traditional medicine in the Ivory Coast. *Phytother Res* 2000; 14: 635-637.
14. Handa SS, Sharma A. Hepatoprotective activity of andrographolide from *Andrographis paniculata* against carbontetrachloride. *Indian J Med Res [B]* 1990; 92, 276-283.
15. Shenoy KA, Somayaji SN, Bairy KL. Hepatoprotective effects of *Ginkgo biloba* against carbon tetrachloride induced hepatic injury in rats. *Ind J Pharmacol* 2001; 33: 260-266.
16. Horváth MÉ, González-Cabello R, Blázovics A, et al. Effect of silibinin and vitamin E on restoration of cellular immune response after partial hepatectomy. *J Ethnopharmacol* 2001; 77: 227-232.
17. Cha JD, Jeong MR, Choi HJ, et al. Chemical composition and antimicrobial activity of the essential oil of *Artemisia lavandulaefolia*. *Planta Med* 2005a; 71(6):575-577.
18. Cha JD, Jeong MR, Jeong SI, et al. Chemical composition and antimicrobial activity of the essential oils of *Artemisia scoparia* and *A. capillaris*. *Planta Med* 2005b; 71(2):186-190.