

**PROTECTIVE EFFECTS OF FEW INDIAN MEDICINAL HERBS
AGAINST HEPATIC DAMAGE IN ANIMALS: A COMPARATIVE STUDY**

**Feroz Khan Z, Syed Mohammed Basheeruddin Asdaq^{*}, Prem Kumar N
and Mohammed Asad**

^{*}Department of Pharmacology, Krupanidhi College of Pharmacy,
5, Sarjapur Road, Koramangala, Bangalore-560 034, INDIA;
E-mail: basheer_1@rediffmail.com/sasdaq@gmail.com
Phone: +91-80-25535751; Fax: +91-80-51309161

Summary

The present work was undertaken for comparative evaluation of *Phyllanthus nirruri* (PN, 142.5 mg/kg, po), *Andrographis paniculata* (AP, 300 mg/kg, po) and *Picrorhiza kurroa* (PK, 200 mg/kg, po) against hepatic damage induced by paracetamol (PCM) or thioacetamide (TAA) in experimental animals. Female Sprague-Dawley rats (150-200 g) were prophylactically treated with PN, AP and PK for 10 days and subsequently liver damage was induced by either PCM or TAA. The hepatoprotective activity was monitored by estimating alanine aminotransaminase (ALT), aspartate aminotransaminase (AST), alkaline phosphatase (ALP) and bilirubin (total and direct) levels in both serum and liver tissue homogenate (LTH). The effect of standardised extracts on antioxidant enzymes; superoxide dismutase (SOD) and catalase (CAT) activities in LTH and histopathological changes in liver were also determined. Administration of PN, AP and PK significantly caused elevation and depletion of endogeneous biomarkers in LTH and serum respectively compared to PCM and TAA toxic control. Additionally, all treatments significantly showed incline in SOD and catalase activities compared to toxic control. Moreover, standardised herbal extracts significantly ameliorate the histological scores demonstrated by hepatotoxic control. Among the three herbal extracts, PK was found to be superior to AP, which was more protective than PN at times of hepatic stress induced by PCM and TAA. These pharmacologic effects suggest that PK is most effective in reverting back the normalcy to hepatocytes in presence of damaging agents such as PCM and TAA.

Key words: *Andrographis paniculata*; Hepatoprotection; Paracetamol; *Picrorhiza kurroa*; *Phyllanthus nirruri*; Thioacetamide.

Introduction

Liver is an organ of paramount importance as it plays an essential role in maintaining the biological equilibrium of vertebrates (1). Damage to the liver inflicted by hepatotoxic agents has grave consequences. In spite of tremendous advances in modern medicine no effective drugs are available, which stimulate liver functions and offers protection to the liver from the damage or help to regenerate hepatic cells (2)¹. In absence of reliable liver-protective drugs in modern medicine, a large number of medicinal preparations are recommended for the treatment of liver disorders (3)¹ and quite often claimed to offer significant relief. There are large numbers of medicinal plants that are used to treat hepatic diseases and their extracts are standardized (4). Most of the formulations available as remedy from hepatic manifestation are polyherbal. Most commonly used plants in herbal formulation in India are *Andrographis paniculata*, *phyllanthus niruri*, *Picrorrhiza kurroa*, *Eclipta alba*, *Tinospora cordifolia*, *Apium graveolens*, *Boerhaavia diffusa* and *Acanthus ilifolius*. Three Indian herbs that are easily available, inexpensive and have a well-established place in traditional Indian medicine were selected in the present study. They possess similar stress relieving, antioxidant, immunostimulatory and cellular protective potential.

Phyllanthus niruri belongs to the family Euphorbiaceae and is mainly found in the tropical areas of the world including southern India and China. It has been claimed to be an excellent remedy for jaundice (5) and infective hepatitis (6). It is reported to possess diuretic, analgesic, stomachic, antispasmodic, febrifugal, and cell protective properties. It is also reported to decrease the amount of hepatitis B virus found in the blood stream (7).

Andrographis paniculata is from the family Acanthaceae and found throughout plain regions in India and other Asian countries. The different parts of the plant were reported to have anti-asthmatic (8), anti-inflammatory (9), antiviral (10), cardioprotective (11), antimicrobial (12), antiprotozoal (13) and hepatoprotective (14) properties. It was also reported to attenuate CCl₄-induced increase in the pentobarbitone sleep time in mice (15).

Picrorrhiza kurroa belongs to the family Scrophulariaceae and commonly found in the himalayas, from Kashmir to Sikkim regions of India at elevation of 2700-4500 meters. It was reported to demonstrate choleric hepatoprotective (16), neuroprotective (17) and immunostimulant (18) activities.

Eventhough the pharmacological efficacy of these herbs are very well documented and many Ayurvedic formulation manufacturers have incorporated these extract in their formulations, but so far no comparative evaluation of these herbs are carried out to suggest their degrees of potency in the formulation. Hence the present study was aimed at determining the hepatoprotective efficacy of different standardized extracts of PN, AP and PK against hepatic injury induced by paracetamol (PCM) and thioacetamide (TAA) in experimental animals.

Methods

Chemicals & reagents

AST, ALT, ALP and Bilirubin kits were procured from Crest Biosystems (Goa, India). Nitroblue tetrazolium (NBT) was purchased from Loba Chemicals. All other chemicals used were of analytical grade and purchased from standard companies.

Plant extracts

The standardized extracts of *Phyllanthus nirruri*, *Andrographis paniculata* and *Picrorrhiza kurroa* were gifted by Phytotech extracts Bangalore (India), Natural Remedies Pvt Ltd, Bangalore (India) and All Seasons Herbs, Bangalore (India) respectively. Silymarin was procured from Micro labs, Hosur, Tamil Nadu (India).

Experimental animals

Laboratory bred female Sprague-Dawley (SD) rats weighing 150-200 g were housed at 25° ± 5°C in a well-ventilated animal house under 12:12 h light dark cycle. Institutional Animal Ethics Committee approved the experimental protocol. The animals were maintained under standard conditions in an animal house as per the guidelines of Committee for the Purpose of Control and Supervision on Experiments on Animals (CPCSEA). The rats had free access to standard rat chow (Amrut Laboratory Animal feed, Maharashtra, India) containing (% w/w) protein 22.10, oil 4.13, fibre 3.15, ash 5.15, sand (silica) 1.12, and water *ad libitum*.

Paracetamol (PCM) induced hepatic damage

The animals were divided into six groups consisting of six animals each. They were treated orally with either vehicle or extract for 10 days as follows: The animals of Group I and II were treated with vehicle for 10 days. Group III animals received silymarin (100 mg/kg, po) (19). The group IV, V and VI were administered standardized *Phyllanthus nirruri* extract (PN) 142.5 mg/kg (20), standardized *Andrographis paniculata* extract (AP) 200 mg/kg (21) and standardized

Picrorrhiza kurroa extract (PK) 200 mg/kg (22), respectively. On 11th day, PCM (2 g/Kg, po) (2) suspended in sucrose solution (40% w/v) was administered in 3 divided doses to animals of groups II, III, IV, V and VI. Food was withdrawn 12 h before PCM administration to enhance the acute liver toxicity. Animals were sacrificed 48 h after the administration of PCM. Blood samples were collected and the serum was used for determinations of activities of aspartate aminotransferase (AST), alanine aminotransferase (ALT) and alkaline phosphatase (ALP) and serum bilirubin levels (Total and direct). The liver was immediately isolated and washed with normal saline, blotted with filter paper and weighed. Liver tissue homogenate (LTH) was prepared in sucrose solution (0.25 M) and used for estimation of endogenous marker enzymes and biological antioxidants viz., superoxide dismutase (SOD) (23) and catalase (24) activities. The liver was then subjected to histopathological examination.

Thioacetamide (TAA) induced hepatic toxicity

The animal groupings and treatments were similar to that used in PCM induced liver damage. Single dose of TAA (100 mg/kg, sc) (25) diluted with distilled water (2% solution) was administered on 11th day to animals of groups II, III, IV, V and VI and the animals were sacrificed 48 h after administration of TAA. Biochemical estimations were carried out in serum and LTH as mentioned above in PCM model.

Statistical analysis

Results are expressed as mean \pm SEM. Statistical significance was assessed using One-way Analysis of variance (ANOVA) followed by Tukey multiple comparison tests. $P < 0.05$ was considered significant.

Histopathological studies

The liver tissue was dissected out and fixed in 10% formalin, dehydrated in gradual ethanol (50–100%), cleared in xylene, and embedded in paraffin. Sections were prepared and then stained with hematoxylin and eosin (H–E) dye for photomicroscopic observations. The hepatic damage was determined by giving scores depending on the intensity as follows (26); normal hepatic architecture and hepatocytes – score 00; focal degeneration of hepatocytes (1/3rd or less) – score 01; diffuse degeneration of hepatocytes (1/3rd - 2/3rd) – score 02; diffuse degeneration of hepatocytes (2/3rd or more) – score 03; diffuse degeneration of hepatocytes + Fatty vacuoles / vesicular formations – score 04.

Results

Effect on Paracetamol (PCM) induced liver toxicity (Table I to IV)

The serum and tissue levels of ALT, AST, ALP and bilirubin (total and direct) were significantly ($P<0.001$) increased and decreased in PCM control group when compared to normal control at the end of 48 h after administration of PCM. Also, there was significant ($P<0.001$) decline in SOD and catalase activities in LTH with incline in histological scores of microscopic section of hepatocytes as well as liver weight in PCM control group compared to normal control. The elevated levels of hepatic markers were significantly ($P<0.001$) reduced in serum of animals pre-treated with PN, AP, PK and silymarin compared to PCM control. The pre-treatment of animals with standardised extracts also resulted in significant ($P<0.001$) rise in biomarker enzymes in LTH compared to PCM control. The antioxidant activities were remarkably increased in LTH of all treated groups with significant ($P<0.001$) decline in liver weight and histological scores compared to PCM control. The observation of microscopic slides of PCM control group showed severe congestion of blood vessels, mild hydropic degeneration, pyknosis of nucleus and occasional necrosis (Figure Ib). Further, in PN groups, there was lesser degree of congestion in blood vessels, hydropic degeneration and pyknosis (Figure Ic). However, in AP and PK groups, degree of congestion of blood vessels were remarkable reduced with mild necrosis no pyknosis (Figure Id & Ie). Hence it is confirmed that standardized extract of AP and PK were found to be more effective than the standardized extract of PN.

Table I: Effect on serum AST, ALT and ALP levels in paracetamol (PCM) induced hepatotoxicity in rats.

TREATMENT	AST (U/L)	ALT (U/L)	ALP (U/L)
Control	107±1.04	50±2.1	485±14.4
PCM control	395±18.4 ^{***}	224.7±9.75 ^{***}	957.5±14 ^{***}
Silymarin + PCM	127.5±10.43 ^{aaa}	53.25±7.9 ^{aaa}	547±13.7 ^{aaa}
PN + PCM	174±11.6 ^{aaa}	110.7±16.4 ^{aaa}	757±14.4 ^{aaa}
AP + PCM	110.7±4.49 ^{aaa}	65.4±8.7 ^{aaa}	509±11.4 ^{aaa}
PK + PCM	144.5±17.2 ^{aaa}	51.2±12.3 ^{aaa}	537±20.1 ^{aaa}

Table II: Effect on AST, ALT and ALP levels in liver homogenate in paracetamol (PCM) induced hepatotoxicity in rats.

Treatment	AST (U/L)	ALT (U/L)	ALP (U/L)
Control	390±15.2	683±8.8	266±8.8
PCM control	93±14.5***	243±12***	65±10.4***
Silymarin + PCM	370±11.5 ^{aaa}	633±14.5 ^{aaa}	233±8.8 ^{aaa}
PN+ PCM	283±20.2 ^{aaa}	586±18.5 ^{aaa}	180±15.2 ^{aaa}
AP+ PCM	343±18.5 ^{aaa}	623±8.8 ^{aaa}	246±8.8 ^{aaa}
PK+ PCM	363±8.8 ^{aaa}	640±15.2 ^{aaa}	216±17.6 ^{aaa}

Table III: Effect on Direct (D-BIL) and Total bilirubin (T-BIL) levels in serum and liver homogenate in paracetamol (PCM) induced hepatotoxicity in rats.

TREATMENT	Serum bilirubin (mg/dl)		Tissue bilirubin (mg/dl)	
	Direct	Direct	Total	Direct
Control	1.52±0.08	2.8±0.11	4.9±0.17	2.87±0.16
PCM control	3.2±0.2***	0.86±0.06***	2±0.11***	4.8±0.14***
Silymarin + PCM	1.82±0.12 ^{aaa}	2.46±0.08 ^{aaa}	5.16±0.14 ^{aaa}	3.37±0.1 ^{aaa}
PN + PCM	1.64±0.15 ^{aaa}	2.36±0.08 ^{aaa}	4.56±0.14 ^{aaa}	3.88±0.21 ^{aaa}
AP + PCM	1.73±0.03 ^{aaa}	2.5±0.11 ^{aaa}	4.76±0.08 ^{aaa}	3.35±0.25 ^{aaa}
PK + PCM	1.93±0.14 ^{aaa}	2.6±0.05 ^{aaa}	4.93±0.12 ^{aaa}	3.52±0.12 ^{aaa}

Values are mean ±S.E.M, n=6 Symbols represent statistical significance.

*** $P < 0.001$; ** $P < 0.01$ & * $P < 0.05$, comparison between control and Hepatotoxic (HP) control, ^{aaa} $P < 0.001$; ^{aa} $P < 0.01$ & ^a $P < 0.05$ Vs hepatotoxic control. HP: Hepatotoxic; Silymarin: 100 mg/kg, po; PN: *Phyllanthus nirruri* 142.5 mg/kg, po; AP: *Andrographis paniculata* 200 mg/kg, po; PK: *Picrorrhiza kurroa* 200 mg/kg, po.

Table IV: Effect on liver weight, superoxide dismutase (SOD) and catalase (CAT) in liver homogenate and histological scores in paracetamol (PCM) induced hepatotoxicity in rats.

TREATMENT	Liver Weight (g/100g)	SOD	CAT	Histological scores
Control	2.87±0.16	5±0.08	4.9±0.2	1.00±0.0
PCM control	4.8±0.14 ^{***}	1.3±0.08 ^{***}	1.96±0.05 ^{***}	4.3±0.5 ^{***}
Silymarin + PCM	3.37±0.1 ^{aaa}	5.2±0.26 ^{aaa}	4.25±0.22 ^{aaa}	2.0±0.0 ^{aa}
PN + PCM	3.88±0.21 ^{aaa}	3.43±0.12 ^{aaa}	3.7±0.11 ^{aaa}	2.6±0.33 ^a
AP + PCM	3.35±0.25 ^{aaa}	4.58±0.42 ^{aaa}	4.83±0.32 ^{aaa}	1.6±0.33 ^{aa}
PK + PCM	3.52±0.12 ^{aaa}	4.06±0.18 ^{aaa}	4.96±0.3 ^{aaa}	2.0±0.57 ^{aa}

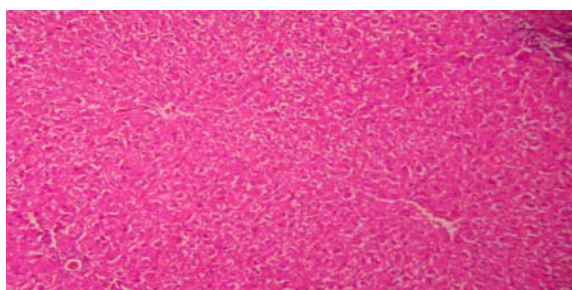


Figure Ia: Normal control - Section stained with (HE- 100X); Liver section of normal rats showing normal hepatic cells with well-preserved cytoplasm, well brought out central vein prominent nucleus and nucleolus.

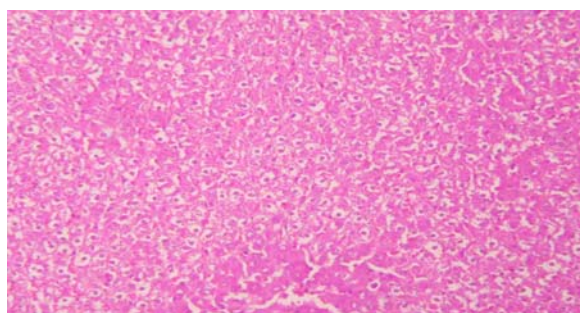


Figure Ib: Hepatotoxic (PCM) control - Section stained with (HE- 100X); liver section showing severe congestion of blood vessels, mild hydropic degeneration, pyknosis of nucleus and occasional necrosis.

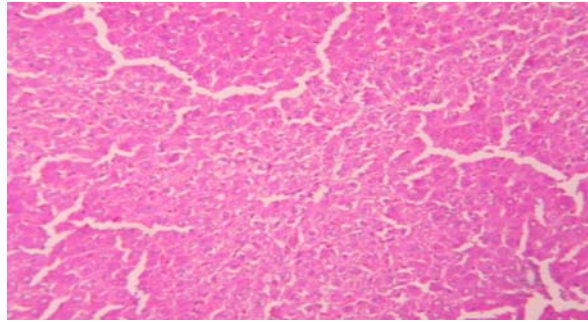


Figure Ic: PCM+ *Phyllanthus nirruri* - Section stained with (HE- 100X); liver section showing lesser degree of congestion of blood vessels, hydropic degeneration and pyknosis

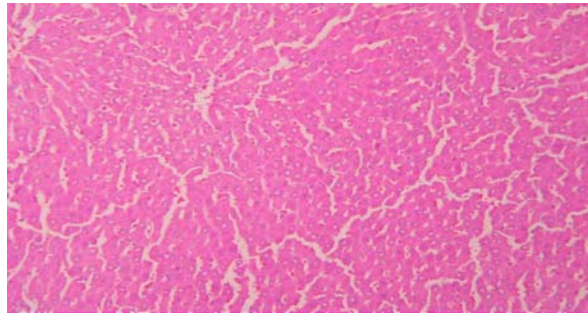


Figure Id: PCM+ *Andrographis paniculata* - Section stained with (HE- 100X); liver section showing lesser degree of congestion of blood vessels, necrosis with no pyknosis

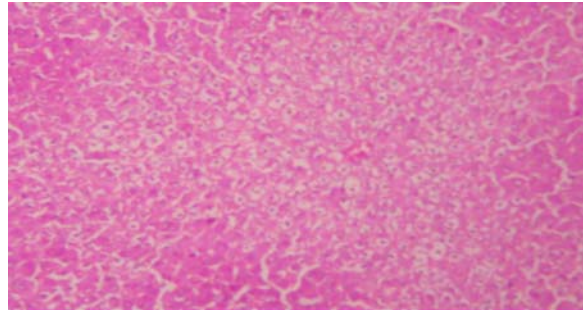


Figure Ie: PCM+ *Picrorhiza kurroa* - Section stained with (HE- 100X); liver section showing of congestion of blood vessels with no pyknosis and necrosis.

Effect on Thioacetamide (TAA) induced liver toxicity (Table V & VIII)

At the end of 48 h after administration of TAA, there was significant ($P<0.001$) increase in biomarker ALT, AST, ALP and bilirubin (total and direct) enzyme levels in serum and decrease in LTH of TAA control group when compared to normal control. Similarly, there was reduction in SOD and catalase enzyme activities in LTH of TAA control group with rise in histological scores and liver weight. The prophylactic administration of PN, AP and PK was found to protect the hepatic integrity with decrease in biomarker levels in serum and increase in LTH. Moreover, the antioxidant activities were significantly ($P<0.001$) increased in all treatment groups compared to TAA control. There was also significant fall in histological scores and liver weight in groups subjected to pretreatment of standardised extracts compared to TAA control. The histological examination (Figure IIa) shows Perilobular hepatocyte necrosis, inflammation and congestion with cytoplasmic vacuolation in TAA control group. Prophylactic administration of PN (Figure IIb) showed mild congestion and inflammation with cytoplasmic vacuolation. Moreover, in groups pre-treated with AP (Figure IIc) and PK (Figure IId), there was only mild congestion and inflammation with no necrosis. Among the three herbs investigated in the study, PK and AP were found to be superior in offering protection to hepatocytes than PN.

Table V: Effect on serum AST, ALT and ALP levels in thioacetamide (TAA) induced hepatic necrosis in rats

TREATMENT	AST (U/L)	ALT (U/L)	ALP (U/L)
Control	123±3.94	81±4	543±12
TAA control	1094±25 ^{***}	743±17 ^{***}	1164±14 ^{***}
Silymarin + TAA	207±28.8 ^{aaa}	136±18 ^{aaa}	665±27 ^{aaa}
PN+ TAA	317±16.7 ^{aaa}	279±16.8 ^{aaa}	856±29 ^{aaa}
AP+ TAA	385±18 ^{aaa}	302±21.8 ^{aaa}	833±27 ^{aaa}
PK+ TAA	195±28.9 ^{aaa}	118±21 ^{aaa}	680±23 ^{aaa}

Table VI: Effect on AST, ALT and ALP levels in liver homogenate in thiacetamide (TAA) induced hepatic necrosis in rats

TREATMENT	AST (U/L)	ALT (U/L)	ALP (U/L)
Control	533±8.8	633±15.2	320±17.3
TAA control	106±8.8 ^{***}	88±7.55 ^{***}	75±8.6 ^{***}
Silymarin + TAA	463±29.6 ^{aaa}	590±20 ^{aaa}	253±14.5 ^{aaa}
PN+ TAA	276±21.8 ^{aaa}	473±20.8 ^{aaa}	178±10 ^{aaa}
AP+ TAA	306±21.8 ^{aaa}	373±20 ^{aaa}	176±8.8 ^{aaa}
PK+ TAA	486±23.3 ^{aaa}	593±15.2 ^{aaa}	260±11.5 ^{aaa}

Values are mean ±S.E.M, n=6 Symbols represent statistical significance.

^{***} $P < 0.001$; ^{**} $P < 0.01$ & ^{*} $P < 0.05$, comparison between control and Hepatotoxic (HP) control, ^{aaa} $P < 0.001$; ^{aa} $P < 0.01$ & ^a $P < 0.05$ Vs hepatotoxic control. HP: Hepatotoxic; Silymarin: 100 mg/kg, po; PN: *Phyllanthus nirruri* 142.5 mg/kg, po; AP: *Andrographis paniculata* 200 mg/kg, po; PK: *Picrorrhiza kurroa* 200 mg/kg, po.

Table VII: Effect on Direct (D-BIL) and Total bilirubin (T-BIL) levels in serum and liver homogenate in thioacetamide (TAA) induced hepatotoxicity in rats.

TREATMENT	Serum bilirubin (mg/dl)		Tissue bilirubin (mg/dl)	
	Direct	Direct	Total	Direct
Control	1.5±0.04	3.17±0.14	2.96±0.12	4.8±0.05
TAA control	2.43±0.07 ^{***}	4.42±0.14 ^{***}	1.1±0.15 ^{***}	2.26±0.14 ^{***}
Silymarin + TAA	1.7±0.16 ^{aaa}	3.3±0.07 ^{aaa}	2.9±0.08 ^{aaa}	4.2±0.05 ^{aaa}
PN+ TAA	1.76±0.09 ^{aaa}	3.63±0.06 ^{aaa}	3.06±0.18 ^{aaa}	4.16±0.2 ^{aaa}
AP+ TAA	1.77±0.05 ^{aaa}	3.61±0.16 ^{aaa}	2.46±0.08 ^{aaa}	4.2±0.17 ^{aaa}
PK+ TAA	1.71±0.05 ^{aaa}	3.45±0.28 ^{aaa}	2.5±0.17 ^{aaa}	4.3±0.08 ^{aaa}

Table VIII: Effect on liver weight, superoxide dismutase (SOD) and catalase (CAT) in liver homogenate and histological scores in thioacetamide (TAA) induced hepatotoxicity in rats.

TREATMENT	Liver Weight (g/100g)	SOD	CAT	Histological scores
Control	2.97±0.08	4.63	7.5±0.28	1.00±0.0
TAA control	5.15±0.15 ^{***}	1.23±0.14 ^{***}	1.8±0.115 ^{***}	5.3±0.33 ^{***}
Silymarin + TAA	3.5±0.11 ^{aaa}	5.12±0.12 ^{aaa}	6.6±0.44 ^{aaa}	2.0±0.0 ^{aaa}
PN+ TAA	3.8±0.17 ^{aaa}	3.63±0.14 ^{aaa}	4.6±0.35 ^{aaa}	2.6±0.33 ^a
AP+ TAA	3.9±0.11 ^{aaa}	3.4±0.25 ^{aaa}	4.5±0.24 ^{aaa}	2.6±0.33 ^a
PK+ TAA	3.0±0.2 ^{aaa}	3.9±0.15 ^{aaa}	6.3±0.29 ^{aaa}	2.0±0.57 ^{aa}

Values are mean ±S.E.M, n=6 Symbols represent statistical significance.

^{***}*P* < 0.001; ^{**}*P* < 0.01 & ^{*}*P* < 0.05, comparison between control and Hepatotoxic (HP) control, ^{aaa}*P* < 0.001; ^{aa}*P* < 0.01 & ^a*P* < 0.05 Vs hepatotoxic control. HP: Hepatotoxic; Silymarin: 100 mg/kg, po; PN: *Phyllanthus nirruri* 142.5 mg/kg, po; AP: *Andrographis paniculata* 200 mg/kg, po; PK: *Picrorrhiza kurroa* 200 mg/kg, po.

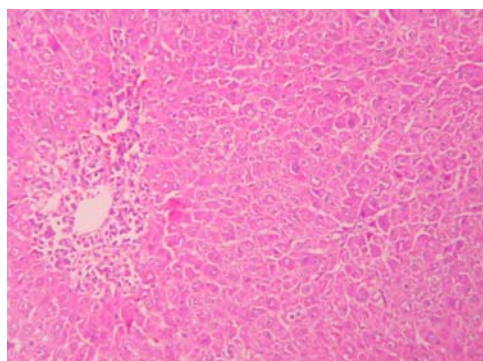


Figure IIa: Hepatotoxic (TAA) control - Section stained with (HE- 100X); liver section of rats showing perilobular hepatocyte necrosis, inflammation and congestion with cytoplasmic vacuolation.

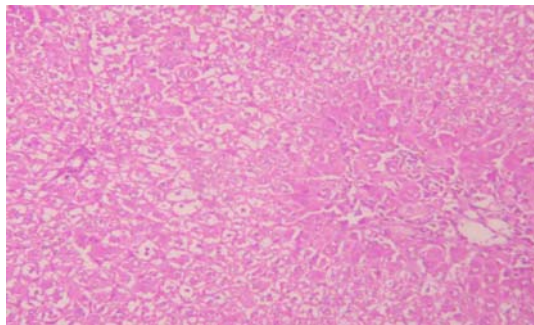


Figure IIb: TAA+ *Phyllanthus nirruri* - Section stained with (HE- 100X); liver section showing mild congestion and mild inflammation with cytoplasmic vacuolation.

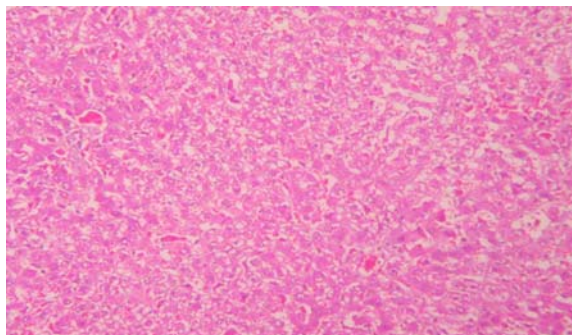


Figure IIc: TAA+ *Andrographis paniculata* - Section stained with (HE- 100X); liver section showing mild congestion and inflammation.

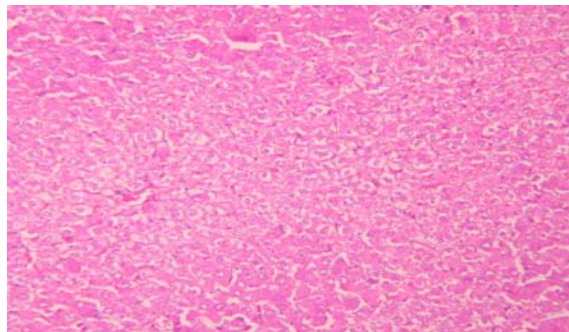


Figure II d: TAA+ *Picrorhiza kurroa* - Section stained with (HE- 100X); liver section showing lesser degree of congestion and inflammation with no necrosis.

Discussion

The present research was undertaken to evaluate comparatively the hepatoprotective efficacy of standardised herbal extracts of *Phyllanthus nirruri* (PN), *Andrographis paniculata* (AP) and *Picrorhiza kurroa* (PK) using paracetamol (PCM) and thioacetamide (TAA) induced hepatic damage in experimental animals. The result of the study shows that the standardised extract of PK was superior to AP and PN in ameliorating the damages caused by hepatotoxins in rats.

Paracetamol (PCM) is known for its analgesic and antipyretic activities and is found to be safe in therapeutic doses but induces fatal hepatic degeneration and necrosis with toxic doses (27). The toxic effect of PCM is due to oxidative damage induced by its metabolite, N-acetyl-p-benzoquinoneimine, produced by the action of cytochrome P-450 in the liver. This metabolite reacts with reduced glutathione (GSH) to yield non-toxic 3-GS-yl-PCM. Reduction of GSH causes the remaining quinone and other natural endogenous oxygen species to bind to cellular macromolecules leading to cell death (28). Toxicity exhibited by the liver during thioacetamide (TAA) poisoning results from the generation of a metabolite, thioacetamide *s*-oxide, which is a direct hepatotoxin responsible for change in cell permeability and inhibition of mitochondrial activity followed by cell death (29).

Damage induced by PCM/TAA is manifested by elevation in serum levels of endogenous biomarkers such as AST, ALT, ALP, bilirubin (total and direct) and depletion of it in tissue homogenate. Prophylactic administration of PN, AP, PK and sylimarin substantially revert back these abnormal changes in serum and LTH as evidenced by biochemical studies. The augmentation of hepatic regeneration was speculated to be the possible hepatoprotective mechanism of standardised herbal extracts. Such rapid regeneration was known to cause the liver to become more resistant to hepatotoxin induced liver injuries (30). Similarly, inclination of the functions of the reticuloendothelial system (31) or declination of protein biosynthesis (32) were also considered as some possible hepatoprotective mechanisms, which could reduce the hepatotoxicity of PCM/TAA. Picroside II of PK could be attributed for enhanced hepatoprotection than PN and AP. This active principle of PK was known to prevent hepatocytes from necrosis by the mechanism of up regulating the bcl-2 gene expression and antioxidation (33).

A major defense mechanism comprises of the antioxidant enzymes such as SOD and catalase, which convert active oxygen molecules into non-toxic compounds. The lipid peroxidation is accelerated when free radicals are formed as the results of losing a hydrogen atom from the double bond in the structure of unsaturated fatty acids. Scavenging of free radicals is one of the major antioxidant mechanisms to

inhibit the chain reaction of lipid peroxidation. The free radical scavenging activity of the crude drug extracts was evaluated by measuring SOD and catalase in liver tissue homogenate (LTH). The endogenous antioxidants were remarkably decreased at times of stress induced by hepatotoxins like PCM and TAA. Pre-treatment of animals with standardized herbal extracts shows the substantial rise in SOD and catalase activities in liver tissue homogenate. Elevated activity of catalase in LTH is more important than rise in SOD activity alone as without a simultaneous increase in catalase activity, elevated SOD activity may lead to intracellular accumulation of H₂O₂ with detrimental effects (34). The maximum increase was seen in a group treated with PK. It is speculated that the augmented antioxidant activities could be due to the presence of more potent active constituents in PK than in AP and PN. The hepatotoxin such as PCM and TAA causes significant increase in liver weight by blocking the secretion of hepatic triglycerides into the plasma (35). Administration of PN, PK and AP prevents this blockage and thereby keeps normal weight of liver at times of stress.

As saponins are found to have a membrane-stabilizing action (36), the cytoprotective effect of PN may be related to this capability. This membrane-stabilizing role of PN was responsible for keeping the integrity of hepatic membrane during PCM and TAA induced liver damage. Hence congestion in blood vessels, hydropic degeneration and pyknosis, induced by PCM, were reduced drastically in PN treated group. In addition, congestion and inflammation with cytoplasmic vacuolation were mild in PN group in TAA model.

The standardised extract of AP provided cover to hepatic damage in both PCM and TAA intoxicated animals mainly due to presence of flavonoid. The degrees of congestion in blood vessels were remarkable reduced with mild necrosis and no pyknosis in AP treated animals intoxicated with PCM. Moreover, only mild congestion and inflammation with no necrosis were found in TAA intoxicated rats with AP pre-treatment.

The picrosides I, II, III could be responsible for highly protective role of PK at times of both PCM and TAA damage to hepatocytes. Particularly, up regulating the bcl-2 gene expression and antioxidation (33) by Picroside II could be attributed to lesser degree of congestion in blood vessels with remarkable reduction in necrosis and pyknosis in PCM intoxicated rats pre-treated with PK. Similarly in TAA intoxicated rats previously treated with PK, mild congestion and inflammation with no necrosis in another indication of recovery imparted by PK.

Thus the results of the study shows that the standardized herbal extracts of PN, AP and PK were found to be effective in ameliorating the complications of damages

induced by PCM and TAA in experimental animals. Among them, PK and AP were found to be superior in preventing the damage to hepatic musculature than PN. However, as formulations are polyherbal, combination of two or more herbal extracts when used together may enhance the efficacy of each other. It is often speculated that the herbs individually might not be so efficacious than when they are combined together. Hence it is found that many formulations that are polyherbal are highly effective in reversing the manifestation of fatty changes, degenerations, necrosis, hepatitis and cirrhosis. Therefore, our future course of action will be to elucidate the possible role of two or more herbal extracts together in comparison with a individual extract in preventing the damage to hepatic cells at times of stress.

To summarise, all three standardised herbal extracts were found to be effective in preventing hepatotoxicity, considering the profile of liver enzymes and histopathological investigations. The standardized extract of AP and PK were found to be superior in preventing the damage to hepatocytes during PCM and TAA injury than PN in experimental animals.

References

1. Rathi A, Srivastava AK, Shirwaikar A, Singh Rawat AK, Mehrotra S. Hepatoprotective potential of *Fumaria indica* Pugsley whole plant extracts, fractions and an isolated alkaloid protopine. *Phytomedicine* 2008;15: 470–477.
2. Chattopadhyay RR. Possible mechanism of hepatoprotective activity of *Azadirachta indica* leaf extract. Part II. *J Ethnopharmacol* 2003; 89: 217–219.
3. Chatterjee TK. Medicinal Plants with Hepatoprotective Properties in Herbal Opinions, vol. III. Books and Allied (P) Ltd: Calcutta; 2000.
4. Sharma A, Shanker C, Tyagi LK, Singh M, Rao V. Herbal Medicine for Market Potential in India: An Overview. *Academic J Plant Sci* 2008; 1: 26-36.
5. Handa SS, Sharma A, Chakrabarti KI. National Products and Plants as liver protecting drugs. *Fitoterapia*. 1986; 57: 300-351.
6. Dixit SP, Achar MP. Bumyumulaki (*Phyllanthus niruri*) and Jaundice in children. *Journal of NIMA*. 1982; 25: 269-272.
7. Lam WY, Leung KT, Law PT, Lee SM, Chan HL, Fung KP, et al. Antiviral effect of *Phyllanthus nanus* ethanolic extract against hepatitis B virus (HBV) by expression micro array analysis. *J Cell Biochem*. 2006; 97: 795-812.

8. Bao Z, Guan S, Cheng C, Wu S, Wong SH, Kemeny DM, et al. A Novel Anti-inflammatory role for andrographolide in asthma via inhibition of the nuclear factor- κ B pathway. *Am J Respir Crit Care Med.* 2009. In Press.
9. Abu-Ghefreh AA, Canatan H, Ezeamuzie CI. In vitro and in vivo anti-inflammatory effects of andrographolide. *Int Immunopharmacol.* 2009; 9: 313-318.
10. Wiart C, Kumar K, Yusof MY, Hamimah H, Fauzi ZM, Sulaiman M. Antiviral properties of ent-labdene diterpenes of *Andrographis paniculata* nees, inhibitors of herpes simplex virus type 1. *Phytother Res.* 2005; 19: 1069-1070.
11. Thisoda P, Rangkadilok N, Pholphana N, Worasuttayangkurn L, Ruchirawat S, Satayavivad J. Inhibitory effect of *Andrographis paniculata* extract and its active diterpenoids on platelet aggregation. *Eur J Pharmacol.* 2006;553,39-45.
12. Singha PK, Roy S, Dey S. Antimicrobial activity of *Andrographis paniculata*. *Fitoterapia* 2003; 74: 692-694.
13. Dua VK, Verma G, Dash AP. In vitro antiprotozoal activity of some xanthenes isolated from the roots of *Andrographis paniculata*. *Phytother Res.* 2009; 2: 126-8.
14. Kapil A, Koul IB, Banerjee SK, Gupta BD. Antihepatotoxic effects of major diterpenoid constituents of *Andrographis paniculata*. *Biochem Pharmacol.* 1993; 46: 182-185.
15. Handa SS, Sharma A, Hepatoprotective activity of andrographolide from *Andrographis paniculata* against carbon tetra chloride induced hepatic damage. *Indian J Med Res.* 1990; 92: 276-83.
16. Visen PK, Saraswat B, Dhawan B. Curative effect of picroliv on primary cultured rat hepatocytes against different hepatotoxins: an in vitro study. *J Pharmacol Toxicol Methods.* 1998; 40: 173-179.
17. Li P, Matsunaga K, Ohizumi Y. Nerve growth factor-potentiating compounds from *Picrorhizae Rhizoma*. *Biol Pharm Bull.* 2000; 23: 890-892.
18. Gupta A, Khajuria A, Singh J, Bedi KL, Satti NK, Dutt P, et al. Immunomodulatory activity of biopolymeric fraction RLJ-NE-205 from *Picrorhiza kurroa*. *Int Immunopharmacol.* 2006; 6: 1543-1549.

19. Yadav NP, Pal A, Karuna S, Bawankule DU, Gupta AK, Darokar MP, et al. Synergistic effect of Silymarin and standardized extract of *Phyllanthus amarus* against CCL₄-Induced hepatotoxicity in *Rattus norvegicus*. *Phytomedicine*. 2008; 15:1053-1061.
20. Umarani D, Devaki T, Govindaraju P, Shanmugasundaram KR. Ethanol induced metabolic alteration and the effects of *Phyllanthus niruri* in their reversal. *Ancient Sci Life*. 1985; 43: 174-180.
21. Rana AC, Avadhoot Y. Hepatoprotective effects of *Andrographis paniculata* against carbon tetrachloride-induced liver damage. *Arch Pharm Res* 1991; 4: 93-95.
22. Vaidya AB, Antarkar DS, Doshi JC, Bhatt AD, Ramesh V, Vora PV, et al. *Picrorhiza kurroa* (Kutki) Royle ex Benth as a hepatoprotective agent--experimental & clinical studies. *J Postgrad Med*. 1996; 42: 105-108.
23. Erich F, Elastner. Inhibition of nitrite formation from hydroxyl ammonium chloride. A simple assay for super oxide dismutase . *Anal Chem*. 1976; 70: 616-620.
24. Eva ML. Mechanism of pH dependent hydrogen peroxide cytotoxicity invitro. *Arch Biochem Biophys*. 1988; 365: 362-72.
25. Ahmad A, Pillai KK, Ahmed SJ, Balani DK, Najmi AK, Marwah R, et al. Evaluation of the hepatoprotective potential of Jigrine pretreatment on thioacetamide induced liver damage in rats. *Indian. J. Pharmacol* 1999; 31: 416-521.
26. Lin HM, Tseng HC, Wang CJ, Lin JJ, Lo CW, Chou FP. Hepatoprotective effect of *Solanum nigrum* Linn extract against CCL₄ – induced oxidative damage in rats. *Chem Biol Interact* 2008; 17: 283-293.
27. Mitchell JR, Jollow DJ, Potter WZ, Gillettee JR, Brodie BN. Acetaminophen-induced hepatic necrosis. I. Role of drug metabolism. *J Pharmacol Exp Ther* 1973; 187: 185-188
28. Udem SC, Madubunyy I, Okoye JOA, Anika SM.. Anti-hepatotoxic effects of the ethanolic extracts of *Combretum dolichopetalum* root bark and *Morinda lucida* leaf. *Fitoterapia* 1997; 68: 21-25.

29. Kumar G, Banu GS, Pappa PV, Sundararajan M, Pandian MR. Hepatoprotective activity of *Trianthema portulacastrum* L. against paracetamol and thioacetamide intoxication in albino rats. *J Ethnopharmacol* 2004; 92: 37-40
30. Lesh R, Reutter W, Keppler D, Decker K. Liver restitution after acute galactosamine hepatitis: autoradiographic and biochemical studies in rats. *Exp Mol Pathol* 1970; 12: 58-63
31. Gruen M, Liehr H, Gruen W, Rasenack U, and Branswig D. Influence of liver-RES (reticulo-endothelial-system) on toxic liver damage due to galactosamine. *Acta Hepato- Gastroenterol.* 1974; 21: 5-12.
32. Castro JA, Ferreyra E C, de Castro C R.. Studies on the role of protein synthesis in cell injury by toxic agents. 1. Effect of cycloheximide administration on several factors modulating carbon tetrachloride induced liver necrosis. *Toxicol Appl Pharmacol* 1977; 41: 305-311.
33. Gao H, Zhou YW. Inhibitory effect of picoside II on hepatocyte apoptosis. *Acta Pharmacol Sin* 2005; 26: 729-736.
34. Das DK, Maulik N, Moraru II. Gene expression in acute myocardial stress. Induction by hypoxia, ischemia/ reperfusion, hyperthermia and oxidative stress. *J Mol Cell Cardiol* 1995; 27: 181-187.
35. Yoko A, Koyama T, Miyagic C, Miyahira M, Inomata C, Kinoshita S, Ichiba T. Free radical scavenging and hepatoprotective action of the medicinal herb, *Crassocephalum crepietioides* from Okinowa Islands. *Biol Pharm Bull* 2005; 28: 19-23.
36. Abe H, Sakaguchi M, Anno M, Arichi S. Erythrocyte membrane stabilization by plant saponins and sapogenins. *Naunyn-Schmiedberg's Arch Pharmacol* 1981; 316: 262-265.