

PROTECTIVE ROLE OF *ALOE VERA* AGAINST RADIATION AND CADMIUM INDUCED HISTOPATHOLOGICAL CHANGES IN THE LIVER OF SWISS ALBINO MICE

R.K.Purohit, Seema Tak, Aruna Chakrawarti and K.M.Bhartiya

Radiation Biology Laboratory, Department of Zoology, Govt. Dungar College, Bikaner (India)

E.mail- dr_rajendra_purohit@yahoo.co.in

Summary

In the present atomic age, uses of radiation and radioisotopes has increased many fold in the fields of radio diagnosis, radiotherapy, industries, agriculture, nuclear research etc. Diagnostic and therapeutic use of radiation is of prime importance and their effects especially on liver and other systems have attracted the interest to minimize them by using some agents.

Considering this state of affairs, the present study was planned to evaluate the protective effect of *Aloe vera* (a herbal drug) against radiation and cadmium induced histopathological alterations in the liver of Swiss albino mice. The animals were exposed to 5.0Gy of gamma rays with or without cadmium chloride treatment. The *Aloe vera* juice was administered since seven days prior to irradiation or cadmium chloride treatment and upto the last autopsy interval.

The animals from all the experimental groups were sacrificed by cervical dislocation at each post-treatment interval of 1, 2, 4,7,14 and 28 days. After sacrificing the animals, pieces of the liver were cut and immediately fixed in Bouin's fluid for histological observations after routine processing.

The changes observed were distortion of hepatic architecture, intracellular oedema, narrower sinusoids, cytoplasmic degranulation, vacuolation, hyperaemia, pycnotic and crenated nuclei.

After combined treatment of radiation and cadmium additive effects were noted. The *Aloe vera* pretreated mice showed less severe changes in comparison to the non drug treated animals at all the corresponding intervals. An early and fast recovery was also observed in *Aloe vera* treated groups. Thus it appears the *Aloe vera* is potent enough to check radiation and cadmium induced hepatic lesions in Swiss albino mice.

Key words: Radiation, Cadmium chloride, *Aloe vera* and Liver.

Introduction

The extensive use of atomic energy now-a-days in various branches of national economy, science and technology, biology, physiology and medicine has made radiation injury an urgent problem attracting the attention not only of specialists in a variety of clinical disciplines but also of a vast army of theoretical scientists.

Different types of ionizing radiations cause similar kinds of damage¹⁻² but all the cells in the living body do not respond to radiations to the same degree. Apparent differences in radio-sensitivity of different cell populations were recognized early in the history of radiobiology and a law was formulated³ that "The radio-sensitivity of cells is directly proportional to their reproductive activity and inversely proportional to their degree of differentiation."

Over past few years the aspect of combined effect of ionizing radiation and chemicals during prenatal development was summarized in the UNCEAR report⁴. The report states that different trace metals found at sufficiently high concentration in air, food and water in some parts of the industrialized world may induce adverse health effects. They may also conceivably combine with the action of ionizing radiation at the background level or under specific conditions of exposure.

Metals may be part of the active sites of enzymes and participate in catalysis. Then, they may stabilize macromolecular structure of proteins and nucleic acids, thereby affecting their functions directly, and they may affect enzymes or membranes or both of sub cellular or cellular particles to control biological pathways. The existence of cadmium in nature, as metallothionein in living matter and the knowledge that this element can become part of active enzymatic sites to catalyze biological reactions, all could raise expectations that it may play some biological role⁵.

Research in the field of the development of radioprotectors worldwide has focused on screening a plethora of chemical and biological compounds over the last 50 years. A number of medicinal plants evaluated for their radioprotective efficacy have shown protective effects against the damaging effects of ionizing radiation and heavy metals. Plant extracts eliciting radioprotective efficacy contain a plethora of compounds including antioxidants, immunostimulants, cell proliferators, stimulators, anti-inflammatory and antimicrobial agents, some of which may act in isolation as well as in combination with other constituents from the same plant.

Aloe vera is known to contain well over 100 separate ingredients or constituents between those found in the leaf and those found in the mucilaginous gel inside the leaf. It is also known that some of the ingredients found in the leaf such as Aloin or the Emodins are recognized as having laxative and anti-microbial properties respectively, which are not present to any significant degree in the gel itself. Little is known about the site of action of Aloe substances, namely whether they act at the systemic, organ, tissue, cell or sub cellular levels or at the surface-cytoplasmic, nuclear-genetic or structural biological and metabolic levels of cells. Accordingly, it is obvious that swallowing boiled leaf extracts will not dissolve blood vessel fatty plaques or blood clots. Aloe has a long history of its use for medicinal, cosmetic and many other purposes. The juice and pulp of leaves are usually used.

The leaf exudate is used largely as a purgative and its parenchyma against a range of spin lesions. Aloe drug is also official in Indian Pharmacopoeia and British Pharmacopoeia. Aloe has many uses in folklore medicine, Ayurveda and Unani system.

No study has appeared so far to test this plant against radiation and cadmium. Therefore, the present investigation has been initiated to determine the efficacy of *Aloe vera* juice to protect Swiss albino mice from radiation and cadmium induced hepatic lesions.

Materials and Methods

Animals

The Adult healthy male Swiss albino mice (6-8 weeks old) were procured from CCS University, Hisar (India). The animals were housed in polypropylene cages and maintained on balanced mice feed and tap water *ad libitum*. They were acclimatized to laboratory conditions before use. Occasionally tetracycline water was provided as a precaution against infection. The temperature of the room was maintained between 22-27°C.

Aloe vera

Aloe vera juice was procured from Millennium Agro Exports, Goregaon (W), Mumbai (India). The drug was fed orally at the dose rate of 0.01 ml/animal/day. The drug was given from seven days prior to cadmium chloride treatment or irradiation and continued up to the last autopsy interval.

Source of irradiation

The animals were exposed by the Cobalt-60 gamma radiotherapy source (Theratron) of AECL make, obtained from Canada. This facility was provided by the Radiotherapy Department of Prince Bijay Singh Memorial Hospital, Bikaner (India). The animals were irradiated at the dose rate ranging from 0.97 Gy/min to 1.97 Gy/min. The dose was calculated at the mid point by multiplying dose rate and tissue air-ratio. The tissues of Swiss albino mice were assumed to be equivalent to human soft tissues.

Cadmium Chloride treatment

The aqueous solution of the cadmium chloride (SDS chemicals, India) was prepared by dissolving 20 mg. of Cadmium Chloride (CdCl_2) in 1000 ml of the glass distilled water thus giving a concentration of 20 ppm, which was given to the animals as drinking water *ad libitum*.

Plan of experimentation

The animals were divided into different control groups according to the treatment given to them, i.e., given cadmium chloride solution as drinking water (Group-II) or exposed to 5.0Gy gamma radiation (Group-III) or both (Group IV). Histopathology of the liver of the animals of these groups was compared with that of those given no treatment (Group-I). Against these the animals of the experimental groups were simultaneously given *Aloe vera* besides the same treatments (Group-V, Group-VI and Group-VII respectively). Liver histopathology of the experimental groups was compared with that of the control groups.

Autopsy

A minimum of five animals from groups II to VII were sacrificed by cervical dislocation and autopsied at each post-treatment interval of 1,2,4,7,14 and 28 days. Five animals of Group-I (Normal) were also sacrificed in a similar manner. were also sacrificed in the similar manner.

Histopathological Studies

After sacrificing the animals liver was taken out, cut into pieces, which were fixed in Bouin's fixative for 24 hours. The tissues were washed in water to remove excessive fixative, dehydrated in graded series of alcohol, cleared in xylene and embedded in paraffin wax. Sections were cut at 5 μm and stained in Harris haematoxyline and alcoholic eosin.

Results and Discussion

In the present experiments histopathological changes were found in the liver of Swiss albino after cadmium chloride treatment and exposure to 5.0 Gy of gamma radiation individually as well as simultaneously. The changes observed on day-1 after exposure were cytoplasmic degranulation, vacuolation, hyperaemia, pycnotic and crenated nuclei. Many cells were lacking their nuclei. The changes were more marked on day-4 and continued up to day-14. The signs of recovery were seen on day-28. In the combined treatment of radiation and cadmium chloride similar changes were observed but they were more pronounced showing synergistic effects. The liver of *Aloe vera* treated animals exhibited less severe damage as compared to non-drug treated animals at all the corresponding intervals. An earlier and faster recovery was also noticed in *Aloe vera* pretreated animals. (Figs.1-9)

Lesions of liver, kidney, testes and severe gastrointestinal disorders have been reported due to cadmium ingestion in experimental animals. Most of the cadmium absorbed from the lung and intestine initially be deposited in the liver binding to a low molecular protein, metallothioneine, which has a high binding capacity for cadmium, zinc and copper. Cadmium is an integral part of metallothioneine. It can induce metallothioneine synthesis in many organs including liver and kidney. The binding of intracellular cadmium to metallothioneine in tissues protects against the toxicity of cadmium.

Gastrointestinal absorption of cadmium was reported by many scientists⁶⁻¹⁰. They also reported the role of metallothioneine in the absorption of cadmium through intestine. It was further reported that more cadmium is absorbed in the proximal part of intestine in natural physiological conditions¹¹.

Several workers have also observed effects of orally administered cadmium on the gastrointestinal system. A severe gastroenteritis is the chief response to ingested cadmium. The cadmium induced intestinal tumors¹² and ulcerative gastroenteritis due to cadmium poisoning¹³ have also been observed.

Combined action of ionizing radiation and other agents is of potentially great importance because there are many occasions where interactions might occur in our environment. Cadmium is a potent pollutant and enters the biological systems through air, water and food¹⁴. The living beings are also simultaneously exposed to radiation which may be man made (research labs, diagnostic clinics, nuclear reactors, radiotherapy etc.) or high background radiations. It is not enough to know the effects of a single agent because the presence of numerous pollutants results in a very complex network of interactions which often leads to an intensified impact as compared to sum total of the individual effects.

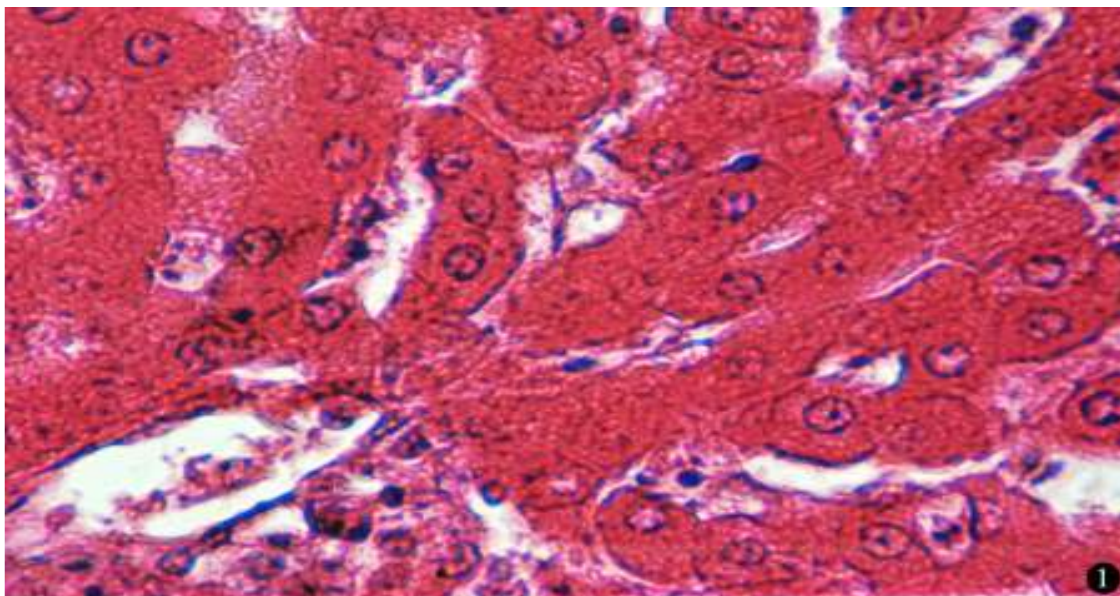
Literature is available on the gastrointestinal absorption of cadmium and the effects of cadmium on the absorption and the distribution of glucose, water, sodium, D-Galactose and Xylose. However, literature on the effects of cadmium on the histology and biochemistry of liver is scanty.

The exact mechanism by which *Aloe vera* protects the animals from radiation induced damage is not known and secondly, it may not have a single mechanism of radioprotection. It seems that *Aloe vera* may protect by different mechanisms because of its various physiological and biochemical properties which are as follows:

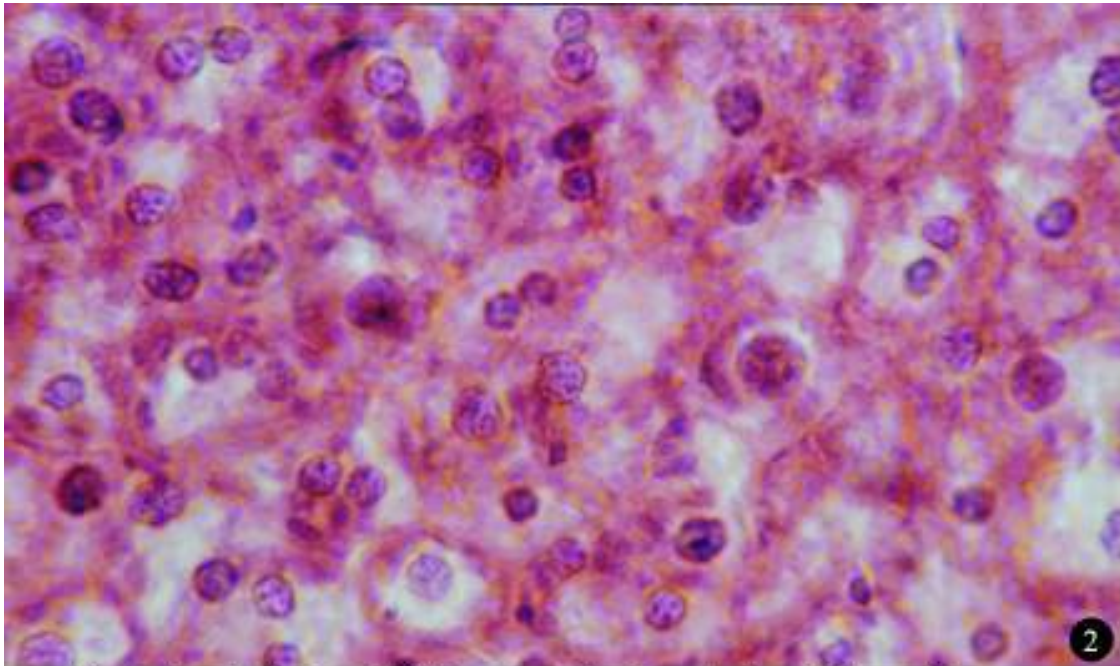
1. It has been shown that the exogenous application of *Aloe vera* increases glutathione levels in the tissues on one hand and maintains -SH groups and increases protein synthesis on the other.

2. The protection offered by *Aloe vera* has been explained by scavenging or oxidizing free-radicals Thus it can be concluded that *Aloe vera* may inhibit the Lipid peroxidation by:

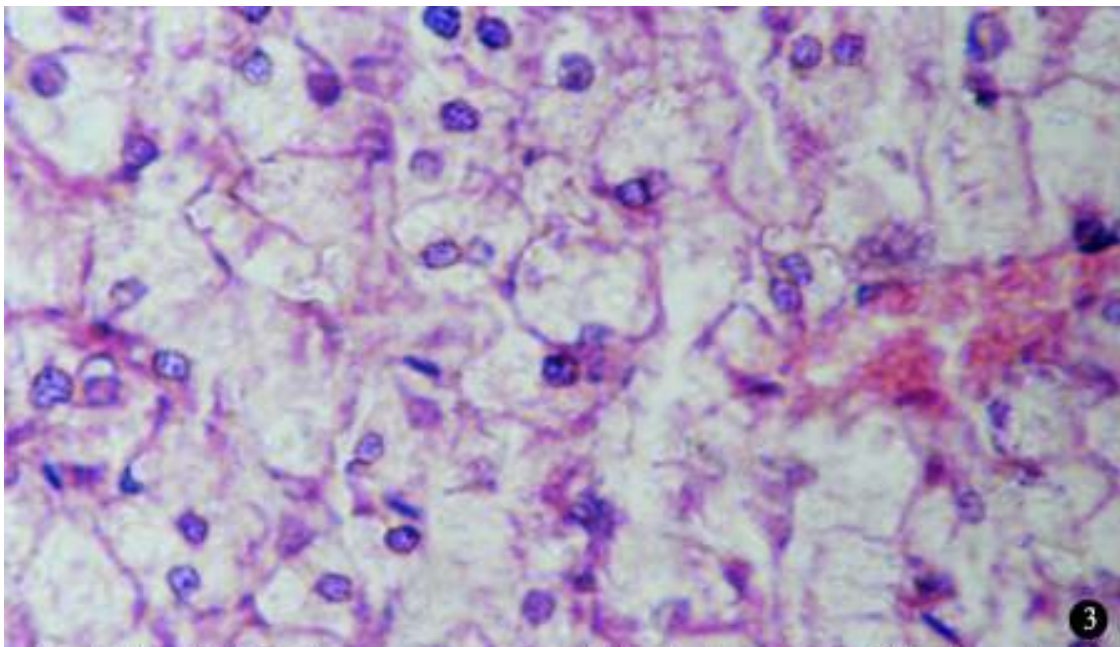
- (i) Reducing the formation of free radicals,
- (ii) Destroying the free radicals already formed,
- (iii) Exudations of the repair mechanism of damaged cell membrane.



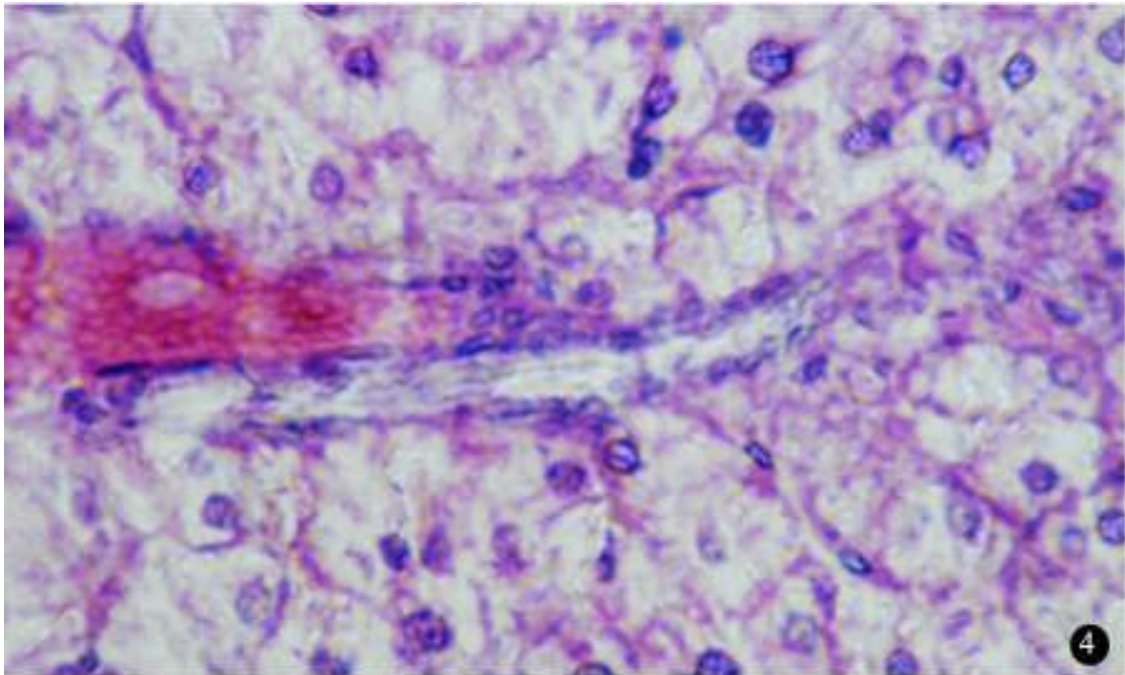
Photomicrograph of liver of normal mice. x 400



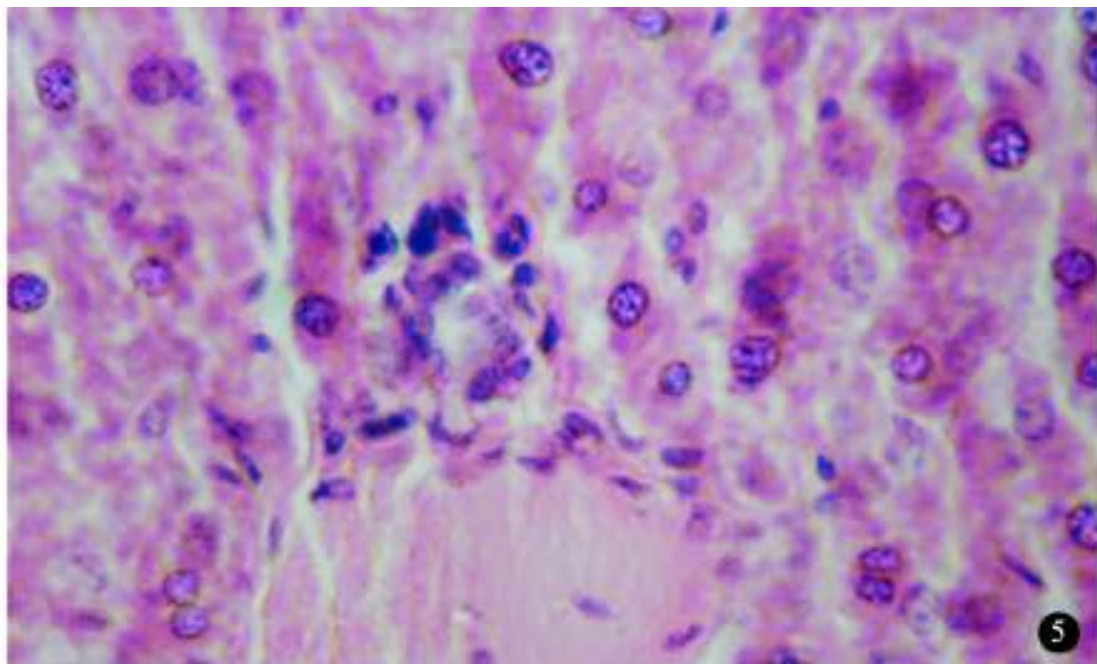
After 1-day of cadmium chloride treatment showing cytoplasmic degranulation, vacuolation and pycnotic nuclei. A few binucleated cells are also seen. x 400



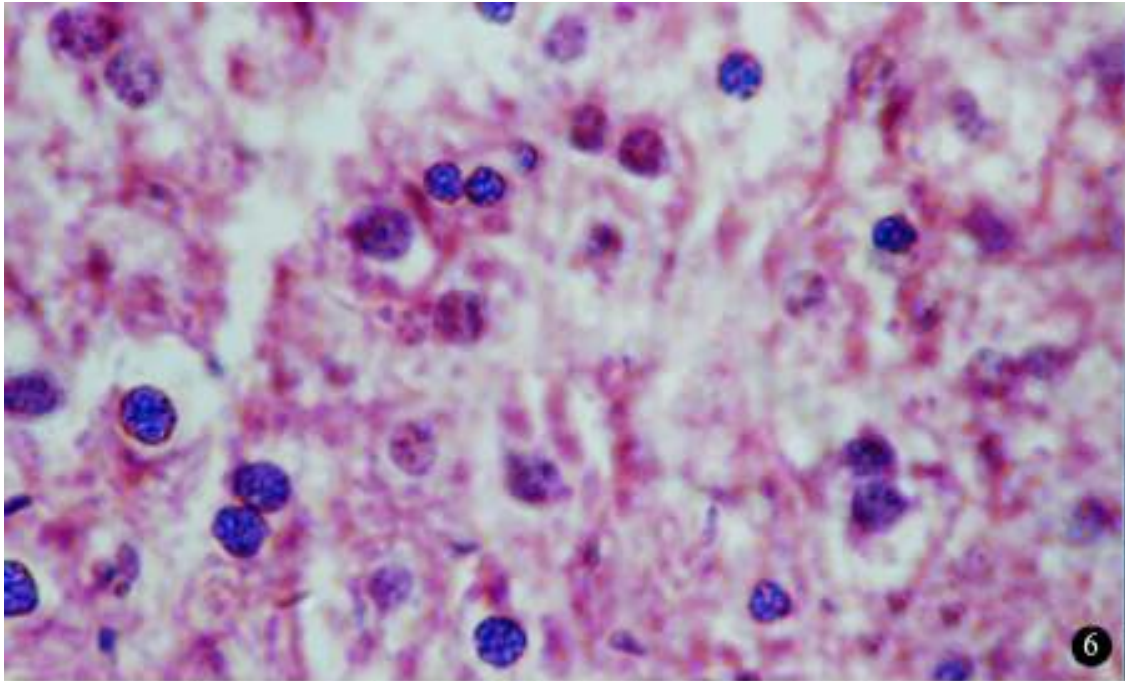
After 7-days of 5.0Gy of gamma rays exposure displaying hyperaemia of blood vessel and leucocytic infiltration. Many cells are seen devoid of nuclei. x 400



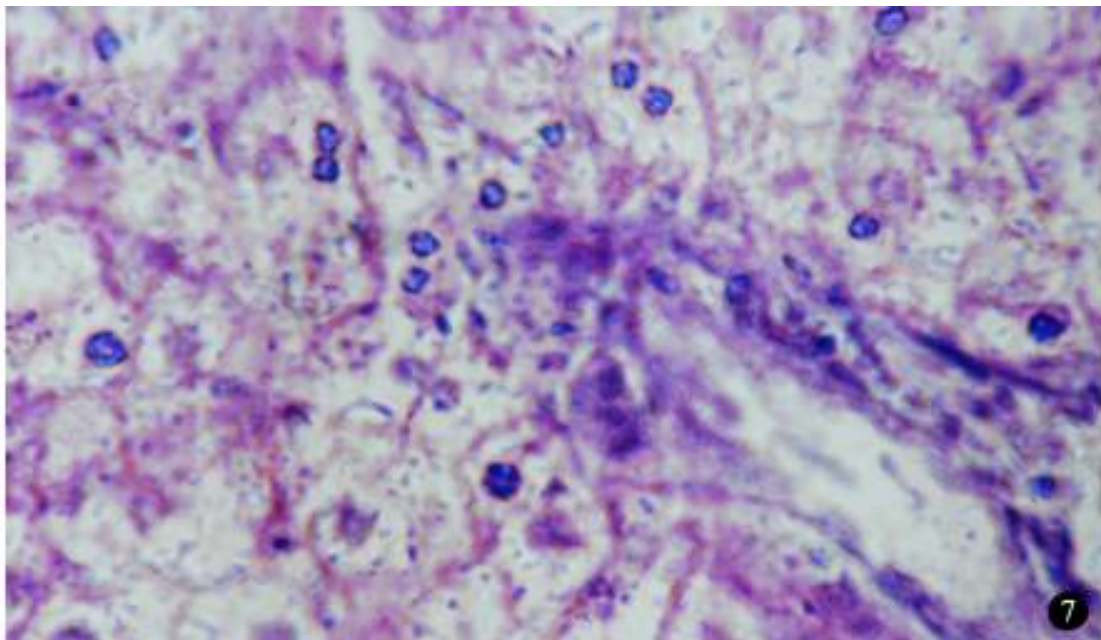
After 1-day of combined treatment of cadmium chloride and gamma rays (5.0Gy) showing cytoplasmic degranulation, vacuolation and fatty degeneration. Hyperaemia of blood vessel and leucocytic infiltration are evident. x 400



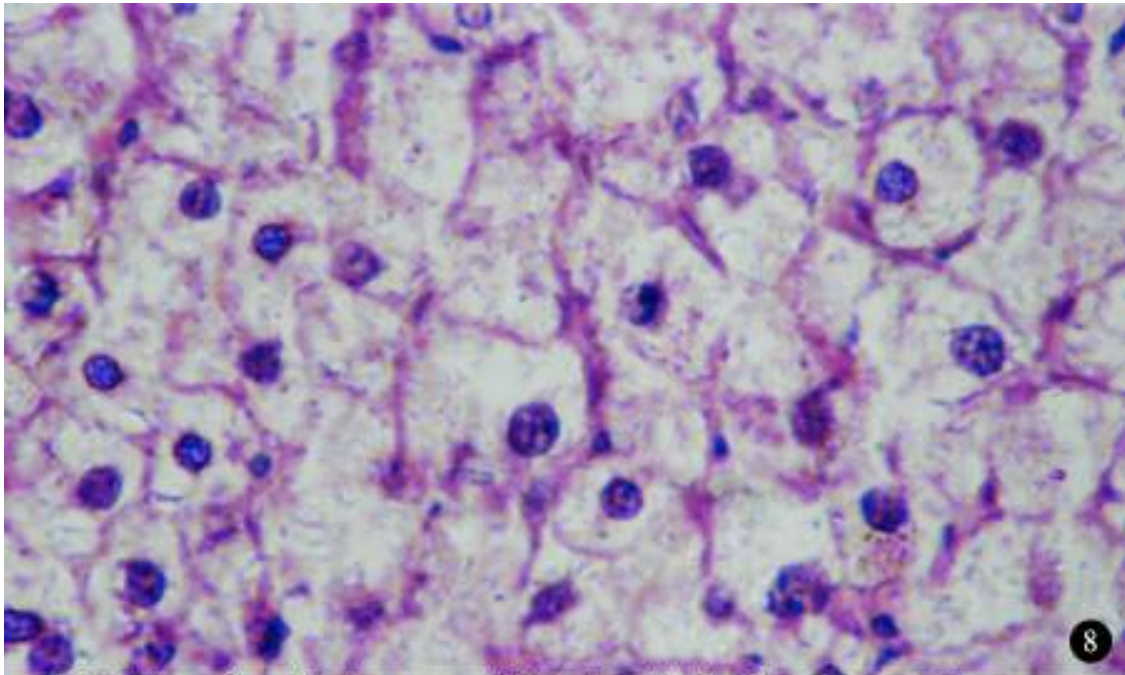
After 28 days of combined treatment of cadmium chloride and gamma rays (5.0Gy) depicting intracellular oedema, narrower sinusoids. Hyperaemia of blood vessel and leucocytic infiltration are also visible. x400



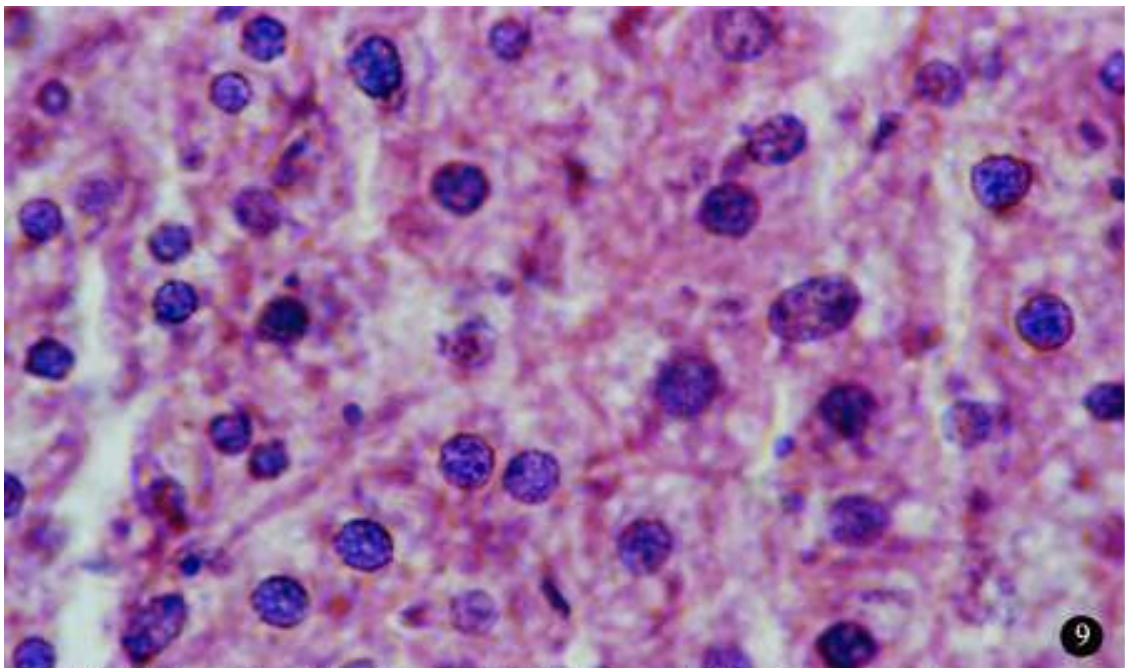
After 7-days of cadmium chloride treatment with prior administration of Aloe vera exhibiting disarrangement of hepatocytes and nuclear pycnosis. x 400



After 7-days of gamma rays (5.0Gy) with prior administration of Aloe vera illustrating widespread cytoplasmic degranulation and vacuolation. A few binucleated cells and many enucleated hepatocytes are seen.x400



After 7-days of combined treatment of Cadmium chloride+Gamma rays + Aloe vera displaying a disorganized hepatic architecture and enucleated hepatocytes. x400



After 28-days of combined treatment of Cadmium chloride+Gamma rays+Aloe vera exhibiting a completely arranged hepatic architecture. x 400

Acknowledgements

Authors gratefully acknowledge the necessary facilities provided by the Head Department of Zoology and the Principal, Govt. Dungar College, Bikaner (India). We also acknowledge the financial support provided by the Department of Science and Technology, Jaipur (India).

References

1. Desjardin, A.U. (1924) : Reaction of abdominal tumours to radiation. J.A.M.A., 83 : 134.
2. Casarett, G.W. (1964) : Pathology of single intravenous doses of polonium. Radiat. Res. (Suppl.), 5 : 246.
3. Bergonie, J. and Tribondeau, L. (1906) : Interpretation de quelques resultates de la radiotherapie at essai de fixation d'ume technique retionelle. Compt. Rene. Acad. Sci. Paris, 143: 983.
4. UNCEAR Report (1982): Ionizing radiation: Sources and biological effects. Annex. L, Biological effects of radiation in combination with other physical, chemical or biological agents. (NY: UN) P 727.
5. Friberg, L., Piscator, M., Nordberg, G.F. and Kjellstrom, T. (1974) : Cadmium in the environment II edition, CRC.
6. Cherian, M.G., Goyer, R. A. and Viberg, L.S. (1978) : Gastrointestinal absorption and organ distribution of oral cadmium chloride and cadmium-metallotionein in mice. Toxicol. Environ. Health, 4 : 861.
7. Kello, D., Sugawara, N., Voner, C. and Foulkes, E.C. (1979) : On the role of metallothionein in cadmium absorption by rat jejunum *in situ*. Toxicology, 14 : 199.
8. Chertok, R.J., Sasser, L.B. Callaham, M.F. and Jorboe, G.E. (1981) : Influences of cadmium on the intestine uptake and absorption of calcium in the rat. J.Nutr., 111 : 631.
9. Foulkes, E.C. and McMullen, D.M. (1986) : Endogenous metallothionein as determinant of intestinal cadmium absorption : A re-evaluation. Toxicology, 38 : 285.
10. Sugawara, N. and Sugawara, C. (1975) : Effect of cadmium *in vivo* and *in vitro* on intestinal brush border - ATPase and ATPase. Bull. Environ. Contam-toxicol., 14 : 653-656.
11. Sorensen, J. A., Neilsen, J.B. and Andersen, O. (1993) : Identification of the gastrointestinal absorption site for cadmium chloride *in vivo*. Pharmacol. Toxicol., 73 : 169.
12. Gunn, S.A. Gould, T.C. and Anderson, W.A.D. (1963) : The selective injurious response of testicular and epididymal blood vessels to cadmium and its prevention by zinc. Am. J. Pathol., 42 : 685.
13. Friberg, L., Piscator, M., Nordberg, G.F. and Kjellstrom, T. (1974) : Cadmium in the environment II edition, CRC.
14. IRPTC (1987) : IRPTC legal file 1986, Geneva international register of potentially toxic chemicals, United Nations Environment Programs, Vol. - I.