

**ANTIFERTILITY EFFECT OF LEAF EXTRACT OF NEEM
(*AZADIRACHTA INDICA*) ON THE MALE WILD INDIAN HOUSE
RAT (*RATTUS RATTUS*)**

Kalyan Brata Santra^{1*}, Chanchal Kumar Manna¹

¹Endocrinology Laboratory, Department of Zoology,
University of Kalyani, Kalyani-741235, West Bengal, India

Present Address:

*** Department of Zoology, Daulatpur High School (H.S.), Daulatpur-733146, Dakshin
Dinajpur, West Bengal, India
kalyan_117@rediffmail.com**

Summary

The present study was conducted to carry out phytochemical, contraceptive efficacy on some indicators for anti-fertility activities of crude leaf extract of neem (*Azadirachta indica*). Effect of oral administration of aqueous leaf extract of neem (200 mg/kg body weight/day, for 30 days) on the male reproductive organs of the wild Indian house rat (*Rattus rattus*) was investigated and its activity was noticed at 35, 40 and 45 days of post treated animals. The treatment had no severe effect on body weight and the reproductive organs weight of rats. In treated rat, testes showed affected seminiferous tubules with intraepithelial vacuolation, loosening of germinal epithelium, occurrence of giant cells, mixing of germ cell types in stages of spermatogenesis and degenerated appearance of germ cells. The treatment also had adverse effects on, morphology, and number of spermatozoa in the cauda epididymidis. The histochemical distribution of different components within the testicular tissue of 35-45days of post treated revealed that the sudanophilic lipid granules was found with higher intensities in the seminiferous tubules. The intensities of acid and alkaline phosphatases were decreased. But there was no remarkable change of Δ^5 -3 β HSDH and 17 β -HSDH within the seminiferous tubules. The concentration of some biochemical components such as the cholesterol and ascorbic acid within the testicular tissues has been increased than the control value. The concentration of acid phosphatase and the alkaline phosphatase were depressed. At 45 days of post treatment, the alterations induced in the reproductive organs recovered to control levels. The results suggested that treatment of neem (*Azadirachta indica*) leaf extract caused reversible alterations in the male reproductive organs of wild Indian house rat, *Rattus rattus*. It also be suggested that the aqueous extracts of neem leaf may be included as a controlling agent in the control of fertility of the rodent pests.

Key words: *Azadirachta indica* , leaf extract, testis, spermatozoa, fertility, rodent pest

Introduction

Among the vertebrate pests, rodents are the most destructive to the agricultural produce in India. These rodents cause damage to the standing crops due to their burrowing, cutting and hoarding activities, to food in storage, in poultry farms and to other commodities (1, 2, 3). In addition to these damages, they are also responsible for transmitting various types of dreaded diseases (4). Naturally on an emergency basis the rodent population should be controlled in a judicious way. Many synthetic chemicals compounds, physical agents, plant extracts have been used to control them. Use of aqueous leaf extract of neem (*Azadirachta indica*) is one of the methods to control the rodent pest as an integrated pest management programme.

The use of neem (*Azadirachta indica*) leaf and seed extracts as contraceptives is not a new idea; these use as a spermicide has been underway since the 1960s. The injection of neem oil into the vas deferens has been successfully tested as an alternative to surgical vasectomy (5). Various forms of neem have been studied as potential reversible male contraceptives (6). Male mice fed water crushed with fresh neem leaves impregnated fewer female mice and had smaller average litter sizes (7). The antifertility effects of neem oil were observed by Lal *et al.* (8). The contraceptive effect of these two forms of neem comes from a reduction in the motility of the sperm. However, neem bark extract and neem seed oil caused arrest of spermatogenesis within 2 months, with a decrease in the number of Leydig cells (9). Contraceptive tablets made from neem extract are currently being used in India.

Considering all aspects and especially to control their fertility the present study has been undertaken to pin point the site of action of aqueous leaf extract of neem (*Azadirachta indica*) on the spermatogenic cells within the testis at various periods of exposure in a wild murid rodent, the wild Indian house rat (*Rattus rattus*).

Material and methods

Experimental animals

In the present study adult male wild Indian house rat (*Rattus rattus*) weighing 100-120g were taken. Before starting of the experiment, all the animals were collected from the surrounding fields of the Kalyani University and were maintained in the usual laboratory conditions (light 12h : dark 12h). Animals were fed on pellet and tap water *ad libitum*.

Plant collection and extract preparation

The leaves of neem (*Azadirachta indica*) were collected from Kalyani University campus. The leaves were dried under shade and ground into coarse powder which was macerated in distilled water for 48 hrs. and filtered with filter paper. Evaporation of the solvent using rotary evaporator gave brownish dark sticky residue. A weighed amount of the concentrated extract was then dissolved in distilled water to get the desired concentration for all experiments.

Effect of the extract on the weights of the body and other organs

A total of twenty four animals were randomly divided into four groups, namely, A, B, C and D. Group A served as the control and the groups B, C and D as the treated groups. All the treated groups received 200 mg/kg body weight/day, for 30 days oral administration of aqueous leaf extract of neem (*Azadirachta indica*) and the other group (control) received an equal volume of vehicle. On the 35th, 40th and 45th day of post treatment the body weights of all rats were recorded, and the animals were sacrificed by cervical dislocation. At necropsy, the various organs of interest (testes, epididymes, vasdeferens, seminal vesicle, coagulating , prostate gland and adrenal) were quickly taken out, weighed on a torsion balance and processed for histological and spermatokinetic studies.

Tissue preparation for histological observations

For histological work, testis were fixed in Bouin's fluid and processed for routine microtomy. 6 µm thick paraffin sections were made, stained with Haematoxylin-Erythrosin and Fast Green sequence. From the well-stained sections of testes of various groups, observations were made and photomicrographs taken. Well stained sections were mainly used for the cytometric measurements.

For the quantitative estimation of the germ cell population, well stained tubular sections of the testis of six animals were counted to give the percentage of germ cell population at the magnification of 1000 x (oil immersion objective 100x and ocular 10x). 200 different seminiferous tubules were randomly selected and counted from each rat.

For the measurement of the seminiferous tubular area randomly sixty fields from each rat were traced with the camera lucida unit and their areas were measured with the help of an Allbritt disc planimeter with Zero setting device. To draw the areas of this component stained sections were magnified with the help of light microscope low power (10x10) magnification.

Tissue preparation for histochemical observations

For the cytochemical localization of lipids (10), Δ^5 -3 β -hydroxysteroid dehydrogenase (11, 12), 17 β - hydroxysteroid dehydrogenase (13, 12), alkaline phosphatase (14) and acid phosphatase (15) within the testis of control and various experimental groups, different methods were followed.

At the end of the cytochemical procedures, sections were mounted in glycerine jelly and observations were made under the light microscope. After thorough processing, the reactions within the testis of the control and experimental animals were carefully studied and their intensities were recorded properly. The necessary photomicrographs were taken from the well-stained sections.

Tissue preparation for biochemical parameters

For the quantitative estimation of various biochemical components eg. total cholesterol (16), ascorbic acid (17), acid and alkaline phosphatases (18) in the testis of control and various experimental animals at least six treated rats were used from each group. At autopsy, the testis was quickly taken out, weighed in a torsion balance, homogenised in different required media for the extraction of cholesterol, ascorbic acid, acid and alkaline phosphatase. After homogenisation they were centrifuged and the supernatant were taken to estimate the mention components.

All the measurements were made at various wavelengths with the help of a spectrophotometer (Spectronic 20 Genesys). After thorough processing for each biochemical component, the estimations were made and the data were recorded, calculated and analysed statistically.

Assessment of sperm count

The cauda epididymis was removed within two minutes of autopsy and immediately placed in 5ml phosphate buffered saline at 37°C. It was then finely minced with scissors and left for 20 min. to ensure an even distribution of sperm throughout the buffer solution. A drop of this suspension was placed in a Neubauer chamber of the haemocytometer and the number of sperm heads were counted (19, 20).

Assessment of abnormal forms of sperm

The sperm suspension (vide above) were filtered to exclude large tissue fragments. Sperms were prepared, fixed and stained with Giemsa stain. At least 1000 spermatozoa per animal were assessed at 1000x magnification with bright field illumination for morphological abnormalities (19).

Statistical analysis

All data were expressed as the mean \pm S.E.M, and the level of significance was determined by student's t-test (21).

Results

Gravimetry

The insignificant changes in the weight of body, epididymis, seminal vesicles, coagulating gland, vasdeferens, ventral prostate, were noticed in the 35 days groups. In the 40th and 45th days of post treated groups, the weight of the body, testis, epididymis, coagulating gland, vasdeferens, seminal vesicle and ventral prostate were increased but not significant statistically.

Histological observations

Histological sections of the control testis showed a large number of seminiferous tubules at various stages of the seminiferous epithelial cycle (Fig. 1). One or two layers of spermatogonial cells, primary and secondary spermatocytes, cluster of spermatid and spermatozoa were found. Spermatozoa were attached to the apical region of the Sertoli cells.

In 35 days post treated rats

Seminiferous tubular area was decreased. The percentage of spermatogonia and spermatid were increased, secondary spermatocyte and spermatozoa were decreased. The testis exhibited severe necrotic damage in the 35 days of post treated group. Leydig cells populations were decreased but there was no significant change in the Sertoli cells nuclear diameter (Table 2).

In 40 days post treated rats

The damaged structures noticed in the seminiferous tubules of rats (Fig. 2). They also caused a marked decrease in the area of the seminiferous tubules of treated groups (Table 2). The percentage of different germ cells population was found to change considerably. The percentages of spermatogonia and spermatocytes were gradually increased (Table 1). The spermatozoa population has been decreased than the control value. No significant change was noticed in the Sertoli cell nuclear diameter.

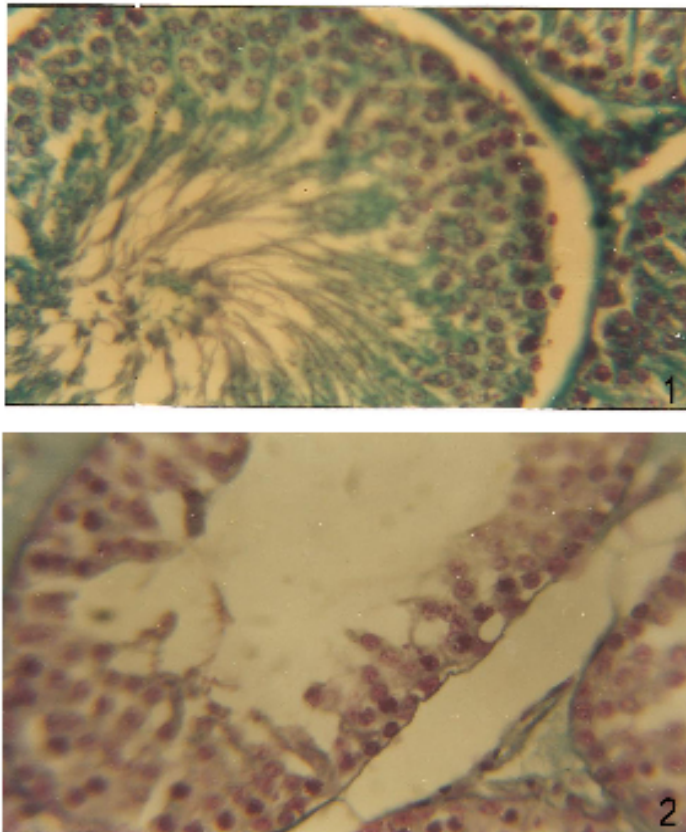


Fig. 1. T. s. of the testes in control rats with normal seminiferous tubules and spermatogenesis (450X).

Fig. 2. Section of testis of 40 days leaf extract of *Azadirachta indica* post treated rat showing few necrotic spermatogonia, early and late primary spermatocytes and sperm debris (450X).

In 45 days post treated rats

Seminiferous tubular area was increased slightly. The intertubular septa were still found to be thickened. The percentage of different germ cells population except spermatozoa were found to be increased (Table 1). The typical orientation of spermatids and spermatozoa was still absent.

Table 1. Effect of aqueous leaf extract of *Azadirachta indica* (200mg/kg body weight/day, for 30 days) on percentage of different germ cell types of the male wild Indian house rat (*Rattus rattus*)

Groups	Spermatogonia (%)	Primary Spermatocytes (%)	Secondary Spermatocytes (%)	Spermatid (%)	Spermatozoa (%)	Sertoli cell (%)
Control (6)**	7.10 ± 1.22*	13.91 ± 0.60	25.92 ± 4.16	18.38 ± 2.72	32.10 ± 1.85	2.58 ± 0.25
35 days (6)	9.62 ± 0.39 ^e	13.98 ± 1.15	19.71 ± 2.48	21.85 ± 2.71	31.99 ± 1.15	2.84 ± 0.35
40 days (6)	19.45 ± 1.44 ^a	16.29 ± 0.28 ^b	26.13 ± 0.49	19.26 ± 0.43	18.26 ± 0.98 ^a	2.61 ± 0.06
45 days (6)	8.17 ± 0.62	15.43 ± 1.00	27.91 ± 3.13	18.90 ± 2.12	27.15 ± 1.18 ^d	2.44 ± 0.20

*Mean ± Standard error; **Number of Animals; ^aP<0.001; ^bP<0.01; ^dP<0.05; ^eP<0.10

Table 2. Effect of aqueous leaf extract of *Azadirachta indica* (200mg/kg body weight/day, for 30 days) on the seminiferous tubular area and Sertoli cells nuclear diameter of the male wild Indian house rat (*Rattus rattus*)

Groups	Seminiferous tubular area (cm ²)	Sertoli cell nuclear diameter (µm)
Control (6)**	23.78 ± 0.63 *	2.55 ± 0.11
35 days (6)	20.12 ± 0.32 ^a	2.41 ± 0.02
40 days (6)	19.38 ± 0.26 ^a	2.52 ± 0.04
45 days (6)	22.62 ± 0.33	2.53 ± 0.03

*Mean ± Standard error; **Number of Animals; ^aP<0.001

Sperm count and assessment of sperm abnormality

Table (Table 3) presents the effect of neem leaf extracts on sperm count and sperm abnormality. Sperm number/mg cauda epididymis was decreased upto 45 days of post treatment. But maximum decrease was noticed at 40 days post treated animals. Gradual increase of sperm abnormality was noticed from 35 to 40 days of post treatment groups. In most of the cases separated head and tail and abnormal shape of head were noticed.

Histochemical components

The seminiferous tubules of control group contains less amount of sudanophilic lipids. The intensities of Δ^5 -3 β -hydroxysteroid dehydrogenase, 17 β -hydroxysteroid dehydrogenase, alkaline phosphatase and acid phosphatase were quite higher.

Table 3. Effect of aqueous leaf extract of *Azadirachta indica* (200mg/kg body weight/day, for 30 days) on sperm count and sperm abnormality of the male wild Indian house rat (*Rattus rattus*)

Groups	Sperm count / mg Cauda epididymis X 10 ⁴	% of Sperm abnormality
Control (6)**	34.63 ± 0.56*	1.55 ± 0.26
35 days (6)	33.74 ± 0.37	2.08 ± 0.23
40 days (6)	31.52 ± 0.78 ^b	2.78 ± 0.24 ^b
45 days (6)	32.42 ± 0.94	1.32 ± 0.06

*Mean ± Standard error; **Number of Animals; ^bP<0.01

In 35days post treated rats

The histochemical distribution of different components within the testicular tissue of 35days post treated rats are presented in the table (Table 4). The sudanophilic lipid granules were found with higher intensities in the seminiferous tubules. The intensities of acid and alkaline phosphatases were also decreased. But no remarkable changes of Δ^5 -3 β HSDH and 17 β -HSDH within the seminiferous tubules were found.

In 40 days post treated rats

Acid and alkaline phosphatases were depressed in the treated rats. But the sudanophilic lipid granules were regained towards the normal level.

In 45 days post treated rats

The activities of Acid and alkaline phosphatases were in depressed condition but sudanophilic lipids, Δ^5 -3 β -HSDH and 17 β HSDH were near towards the control level.

Table 4. Effect of aqueous leaf extract of *Azadirachta indica* (200mg/kg body weight/day, for 30 days) on some histochemical components within the testis of the male wild Indian house rat (*Rattus rattus*)

Methods	Regions	Control	35 days	40 days	45 days
Sudan III & IV	i) Basement membr	++	++	++	++
	ii) Seminiferous tubu	+	++	++	+
	iii) Interstitium	++	++	++	++
Acid phosphatase	i) Basement membr	++	±	±	±
	ii) Seminiferous tubu	±	-	-	-
	iii) Interstitium	++	±	-	±
Alkaline phosphatase	i) Basement membr	+	+	+	+
	ii) Seminiferous tubu	+	±	±	±
	iii) Interstitium	+	-	-	-
17β-hydroxy steroid dehydrogenase	i) Basement membr	++	++	++	++
	ii) Seminiferous tubu	++	+	++	++
	iii) Interstitium	++	++	+	++
Δ ⁵ -3β- hydroxy steroid dehydrogenase	i) Basement membr	+++	++	++	+++
	ii) Seminiferous tubu	+	+	+	+
	iii) Interstitium	+++	++	++	++

Intensities of reactions : + : Positive ; - : Negative ; ++ : Moderate ; +++ : Highly positive or intensified; ± : Not significant

Biochemical components

Testicular extracts of control rats contain very less concentration of ascorbic acid and cholesterol. The concentrations of acid and alkaline phosphatases were very high (Table 5).

In 35 days post treated rats

The different biochemical components in the testicular extract of 35 days post-irradiated group are given in the table (Table 5). The concentration of cholesterol and ascorbic acid has been increased than the control value. Whereas the concentrations of acid and alkaline phosphatase were quite lower than the control value.

In 40 days post treated rats

The concentration of cholesterol and ascorbic acid in the treated groups were high. But the concentration of alkaline phosphatase and alkaline phosphatase have been decreased.

In 45 days post treated rats

The concentration of ascorbic acid was nearer to the normal value. But the concentration of cholesterol was quite higher than the normal value. The activities of alkaline phosphatase and acid phosphatase have been decreased in the 45 days of post treated rats in comparison to the control animals (Table 5).

Table 5. Effect of aqueous leaf extract of *Azadirachta indica* (200mg/kg body weight/day, for 30 days) on some biochemical components of the testes of the male wild Indian house rat (*Rattus rattus*)

Groups	(mmol/100mg fresh testicular tissue)		(mg/100mg fresh testicular tissue)	
	Acid phosphatase	Alkaline phosphatase	Ascorbic acid	Cholesterol
Control (6)**	0.694 ± 0.054*	0.312 ± 0.013	0.018 ± 0.009	0.529 ± 0.02
35 days (6)	0.669 ± 0.014	0.289 ± 0.024	0.022 ± 0.001	0.674 ± 0.03 _b
40 days (6)	0.595 ± 0.047	0.265 ± 0.026	0.025 ± 0.002	0.649 ± 0.04 _c
45 days (6)	0.608 ± 0.034	0.252 ± 0.026	0.018 ± 0.001	0.595 ± 0.05

*Mean ± Standard error; ** Number of Animals: ^bP<0.01; ^cP<0.02

Discussion

In the present study oral administration of aqueous leaf extract of neem (*Azadirachta indica*) (200 mg/kg body weight/day, for 30 days) on the male reproductive organs of the wild Indian house rat (*Rattus rattus*) was investigated and its activity was noticed at 35, 40 and 45 days of post treated animals.

In this study histopathological observations showed that leaf extract of neem (*Azadirachta indica*) affected the process of spermatogenesis and disrupted the production of sperm. The seminiferous tubules showed only spermatogonia, spermatocytes, Sertoli cells, few spermatids and very small amount of deformed spermatozoa at 35 and 40 days of post treatment. This might have been the cause of the delay in reproduction observed in the experimental groups. The reduction in the number of round spermatids was depressed at 40days when compared to the control ratio of spermatids. There is a close relationship between spermatid losses and the ultimate decline in sperm numbers (22). At 45 days after treatment, there was evidence of regeneration of spermatozoa and resting spermatocytes (pre-spermatocytes) were present. The damaged structures noticed in the seminiferous tubules of rats at 35and 40 days of post treated groups. They also caused a marked decrease in the area of the seminiferous tubules of treated groups. The No significant changes were noticed in the Sertoli cell nuclear diameter and Leydig cells population. Seminiferous tubular area was increased slightly at 45 days of post treatment.

Though typical orientation of spermatids and spermatozoa was still absent. Sperm number/mg cauda epididymis was decreased upto 45 days of post treatment. But maximum decrease was noticed at 40 days post treated animals. Gradual increase of sperm abnormality was noticed from 35 to 40 days of post treatment groups. In most of the cases separated head and tail and abnormal shape of head were noticed.

Mishra and Singh (23) showed that oral administration 200 mg/kg body weight/day, for 28 days of aqueous leaf extract of neem (*Azadirachta indica*) on the male reproductive organs of the Parkes (P) strain mice had no effect on body weight and the reproductive organs weight. In severe cases, the tubules were lined with Sertoli cells only, Sertoli cells and rare germ cells, or with Sertoli cells and several germ cells but without cellular association patterns (23). Leaf extract of neem (*Azadirachta indica*) had adverse effects on motility, morphology, and number of spermatozoa in the cauda epididymidis. Sander-Cramer (24) and Garge *et al.* (25) showed that purified neem extract had potent spermicidal activity. Neem extract also reduced sperm counts and motility and increased the number of abnormal sperm (26). He also reported reductions in weight, epithelial cell height and nuclear diameter of the ventral prostate and seminal vesicles as indirect evidence of the anti-androgenic action of neem extract. Neem extract reduced the sperm count and abnormal sperm morphology.

From the histochemical study, high amount of lipid materials were observed in the treated groups. This lipid accumulation was mainly restricted to the whole tubules, basement membrane and the interstitial cells of the testicular tissue. High amount of lipid droplets within the Sertoli cells of mammals seem to be due to the phagocytosed lipid materials of the degenerating germ cells, which is also pointed out by Lacy (27).

It is also known that the lipid inclusion in the Sertoli cell may be in the control of FSH secretion from the pituitary (28). Serum FSH have been shown to be related to the germinal cell component, particularly spermatogonial numbers (29). Both the lipids and steroid dehydrogenases are usually known to show inverse relationship between them. Higher content of lipids and lower activity levels of the dehydrogenases are characteristic of steroidogenically inactive gonads.

Acid and alkaline phosphatases were found to be decreased within the treated groups of rats (both biochemical and histochemical). The alkaline phosphatase is said to be a histochemical marker for primordial germ cells of various species, including rat (30) and mouse (31). The alkaline and acid phosphatases have been widely studied in many organisms and tissues (32) including certain animal testis or sperm (33, 34). The role of alkaline phosphatase in the development of spermatozoa has been well studied in a number of mammalian species. It is known that this enzyme is required for the synthesis of glycogen, which in turn apparently participates in the metabolic process of spermatogenesis (35). Mann (36) reported an intense activity of acid phosphatase in the seminal plasma of several mammalian species including the human beings. Seminal and prostatic acid phosphatase has been associated with the nutrition of spermatozoa (37, 38) and with their fertilizing ability (39).

It is also known from the present investigation that ascorbic acid from the testicular tissues has been increased due to oral administration of neem leaf extract. Role of ascorbic acid in the process of steroidogenesis is well known (40). In mammals, ascorbic acid has been found to exert an inhibitory role on steroidogenesis (40). Again as ascorbic acid is a known catalyst for both lipid peroxidation and alteration of unsaturated fatty acid composition (41), so the involvement of ascorbic acid in the process of steroidogenesis in the testis of the rats of control and treated groups may be taken into consideration. Adverse effects of leaf extract of neem on the level of fructose in the seminal vesicle and sialic acid in the duct was noticed in mice by Mishra and Singh (23).

It has been suggested (42) that 17 β -ol-dehydrogenase (oxidase) is located within both the tubules and the interstitial elements and is diminished slightly during the oral administration of neem leaf extract. This phenomenon is directly related to the destructive changes associated with the depopulation of the seminiferous tubules.

In this study with wild rats, it can be concluded that aqueous crude leaf extract of neem (*Azadirachta indica*) has effective contraceptive activity for the control of rodent pests and reasonable safety at anti-fertility doses used, however, the study has a limitation that it was done on crude extract that contains many anti-fertility components responsible for observed effects was not done. Further study on the possible mechanism as well investigation on the fractionated isolates should be investigated.

References

1. Chopra G, Dhindsa JS. Rodent pest management in poultry farms. Poul. Adv 1987 ; 20 (3) : 49-60.

2. Chopra G, Dhindsa JS. Positivity of opinion survey of rodent control in poultry farms. *Ind. Poult. Rev.* 1988 ; 20 (1) : 31-39.
3. Prakash I, Ghosh PK. *Rodents in Indian Agriculture*. Vol. I. Scientific Publishers, Jodhpur 1992; 1-685.
4. WHO. Ecology and control of rodents of public health importance. WHO Technical Report. Series No. 553 1974 : 1-2.
5. Upadhyay SN, Dhawan S, Talwar GP. Antifertility effects of neem (*Azadirachta indica*) oil in male rats by single intra-vas administration: an alternate approach to vasectomy." *Journal of Andrology* 1993;14(4): 275-81.
6. Jensen JT. Male contraception. *Current Womens Health Reports* 2002; 2(5): 338-45.
7. Deshpande VY, Mendulkar KN, Sadre NL. Male antifertility activity of *Azadirachta indica* in mice. *Journal of Postgraduate Medicine* 1980; 26: 167-70.
8. Lal R, Sankarnarv A, Mathur VS, Sharma PL. Antifertility effect of neem oil in female albino rats by intra vaginal and oral routes. *Indian J. Med. Res.* 1986; 83: 89-92.
9. Randhawa NS, Parmar BS. *Neem*. New Age International. New Delhi, India 1996.
10. Kay WW, Whitehead R. Sudan III and IV methods for neutral fats. *Histochemistry-Theoretical and Applied*. 2nd ed. Pearse . AGE ed. 1941; 853-854.
11. Wattenberg LW. Microscopic histochemical demonstration of steroid 3 β -ol-dehydrogenase in tissue sections . *J. Histochem. Cytochem.* 1958 ; 6 : 225-232.
12. Bilaspuri GS, Guraya SS. Histochemical studies on steroid dehydrogenases in the testis of the goat (*Capra hircus*). *J. Endocrinol.* 1984 ; 101 : 359-363.
13. Pearson B, Grose F. Histochemical demonstration of 17 β -hydroxysteroid dehydrogenase by use of a tetrazolium salt. *Proc. Soc. Exptl. Biol. Med.* 1959 ; 100 : 636-638.
14. Butcher RG, Chayan J. Quantitative studies on the alkaline phosphatase reaction . *J. Roy. Micros. Soc.* 1966 ; 85 : 111-117.
15. Bitensky L. Modifications of the Gomori acid phosphatase technique for controlled temperature frozen sections. *Quart. J. Micros. Sci.* 1963 ; 104 : 193-196.
16. Zarrow MX, Yochim JM, Mc Carthy JT. *Experimental endocrinology: A source book of basic techniques*. Academic Press, New York 1964.
17. Nino HV, Prasad AS. Ascorbic acid (Vitamin C) . In : *Vitamins and trace elements*. Gradwohl's Clinical Laboratory Methods and Diagnosis. Vol.1. Sonnenwirth AC, Jarett L. ed. The C. V. Mosby Comp., St. Louis, Toronto, London 1980 ; 370-372.
18. Walter K, Schutt C. Acid and alkaline phosphatase in serum (Two point method). In : *Methods of Enzymatic Analysis Vol. 2*. Bergmeyer, HU ed. Academic Press, New York, Sanfrancisco, London.1974 ; 856-860.
19. Barratt CLR, Davis AG, Bansal MR, Williams ME. The effects of lead on the male rat reproductive system. *Andrologia* 1989 ; 21 (2) : 161-166.
20. Didolkar AK, Keizer-Zucker A, Sundaram K, Bardin CW, Agback H, Johansson DB. Effect of sulfasalazine and its analogs on fertility in male rats. *Contraception* 1988 ; 37 (5) : 539-548.
21. Fischer RA. *Statistical methods for research workers*. Oliver Boyd. London 1963 .
22. Pogany GC. Effects of X- irradiation on the kinetics of abnormal sperm production and sperm loss in the mouse. *J. Repord. Fert.* 1987 ; 80 :1-12.
23. Mishra RK, Singh SK. Effect of aqueous leaf extract of *Azadirachta indica* on the reproductive organs in male mice. *Indian journal of experimental biology* 2005; 43(11): 1093-1103.

24. Sander FV, Cramer SD. A practical method of testing the spermicidal action of chemical contraceptives. *Human Fert.* 1941; 6: 134.
25. Garge S, Doncel G, Chabara S, Upadhyay SN, Talwar GP. Synergistic spermicidal activity of neem seed extract, reetha saponins and quinine hydrochloride. *Contraception* 1994;50: 185-190.
26. Shaikh PD. Studies on the antifertility effect of *Azadirachta indica* leaves on the testis of albino rats. M. Phil. Dissertation, Karnataka University, India 1990.
27. Lacy D. Light and electron microscopy and its use in the study of factors influencing spermatogenesis in the rat. *J. Roy. Microsc. Soc.* 1960 ;79 : 209-225.
28. Kerr JB, de Kretser DM. Cyclic variations in Sertoli cell lipid content throughout the spermatogenic cycle in the rat. *J. Reprod. Fert.* 1975 ; 43 : 1-8.
29. de Kretser DM, Burger HG, Hudson B. The relationship between germinal cells and serum FSH levels in males with infertility. *J. Clin. Endocrinol. Metab.* 1974 ; 38 : 793-797.
30. Mc Alpine RJ. Alkaline glycerophosphatase in the developing adrenals, gonads and reproductive tract of the white rat. *Anat. Rec.* 1955 ; 121 : 407-408.
31. Mintz B. Embryological development of primordial germ cells in the mouse : influence of a new mutation . *W. J. Embryol. Exp. Morphol.* 1957 ; 5 : 396-403.
32. Mc Comb RB, Bowers GH Jr, Posen S. Alkaline phosphatase. Plenum Publication . New York 1979 .
33. Turner C, Mc Laughlin J, Smith BR. Changes in lipase and phosphatase activities of rat spermatozoa in transit from caput to cauda epididymis. *J. Reprod. Fert.* 1975 ; 45 : 1-8.
34. Chang CH, Angellis D, Fishman WH. Presence of the rare D-variant, heat stable , placental type alkaline phosphatase in normal human testes . *Cancer Res.* 1980 ; 40 : 1506-1510.
35. Sohval AR. The anatomy and endocrine physiology of the male reproductive system. In : *The Endocrinology of reproduction.* Velardo JT ed . Oxford University Press, New York 1958 ;243-312.
36. Mann T. *The biochemistry of semen and of the male reproductive tract.* Methuen and Co. Ltd. London 1964 .
37. Allison AC, Hartree EF. Lysosomal enzymes in the acrosome and their possible role in fertilization. *J. Reprod . fert.* 1970 ; 21 : 505-515.
38. Serrano JA, Shannon WA Jr, Sternberger NJ, Wasserkrug HL, Serrano AA, Seligman AM. The cytochemical demonstration of prostate acid phosphatase using a new substrate, phosphorylcholine . *J. Histochem.Cytochem.* 1976 ; 24 : 1046-1056.
39. Singer R, Barnet M, Allaluf U, Schwartzman S, Sagiv M, Landau B, Segenreich E, Servadio C. Some properties of acid and alkaline phosphatase in seminal fluid and isolated sperm. *Arch. Androl.* 1980 ; 5 : 195-199.
40. Kitabchi AE. Ascorbic acid in steroidogenesis. *Nature* 1967 ; 215 : 1385-1386.
41. Shimizu K. Effects of ascorbic acid on the side chain cleavage of cholesterol. *Biochem. Biophys. Acta.* 1970 ; 210 : 333-340.
42. Ellis LC, Berliner DL. Alterations in testicular androgen biosynthesis as related changes in spermatogenesis induced by ionizing radiations. In : *The Gonads.* Mc Kerns KW ed. Appleton, New York 1969 ; 739-783.