

GASTROPROTECTIVE EFFECT OF ACANTHOPANAX TRIFOLIATUS ON EXPERIMENTALLY INDUCED ACUTE ULCER IN RATS

Roslida AH^{1*}, Siti Nurusaadah H¹ and Fezah O¹

¹*Department of Biomedical Sciences, Faculty of Medicine & Health Sciences, University Putra Malaysia , 43400 Serdang, Selangor, Malaysia.*

Summary

This study is aimed to evaluate anti-ulcerogenic effect of ethanolic extract of *Acanthopanax trifoliatum* leaves (EAT) in acute ulcer induced by absolute ethanol and NSAID (diclofenac) in male Sprague-Dawley (SD) rats and to determine the possible involvement of either sulfhydryl group or nitric oxide group in its pathway. The result of the preliminary study showed that EAT did not give any ulcerogenic effect in the rat's stomach. For the gastroprotective study, EAT was shown to have substantial gastroprotective effect on the gastric mucosa of SD rats induced by absolute ethanol at dose 300 mg/kg with a tendency for the activity to be comparable to the standard drug, lansoprazole. Whereas for ulcer induced by NSAID (diclofenac), the extract does not seem to have a significant gastroprotective activity at the dosages used. Investigation of the possible mechanism behind the anti-ulcerogenic activity of the EAT was done using L-NAME (a NO synthase inhibitor) and NEM (a sulfhydryl blocker) in ethanol-induced ulcer models pre-treated with EAT at higher dose (500mg/kg). The previous administration of L-NAME did not reduce the anti-ulcerogenic activity of EAT in ethanol induced ulcer model, suggesting that the pharmacological mechanism has no relationship with NO. On the other hand, pre-treatment with NEM reduced the anti-ulcerogenic activity of EAT on ethanol induced-ulcer model. This result suggests that EAT has active substances that increase the mucosal non-protein sulfhydryl groups which contribute to the extract's gastroprotective effect .

Key words: Gastroprotective , *Acanthopanax trifoliatum*, ethanol-induced ulcer, NSAIDs, endogenous sulphhydryls

Corresponding author: Dr Roslida AH,
Department of Biomedical Sciences,
Faculty of Medicine and Health Sciences
Universiti Putra Malaysia, 43400 Serdang, Selangor, Malaysia
E-mail: roslida@medic.upm.edu.my

Introduction

In Chinese medicine, disease prevention, intervention, meditation, and nursing care are the main focus of its treatment and considered to be equally important. The Chinese populations have been utilizing Chinese medicine aiming at maintaining and strengthening health so as to nourish quality of life in daily activities. However, many of the applications is still lacking in proof by means of scientific method.

Acanthopanax trifoliatum is known in Chinese traditional medicine for its ginseng-like activity and has been utilized as a folk-medicine for bruise, neuralgia, impotence, and gout in China, Taiwan, and the Philippines (1-2). The plant is also used to treat leprosy; the roots are used to heal ulcers and to cure ring-worm infection. A decoction of the leaves is drunk to treat tuberculosis and to improve general weakness. In Cambodia, Laos, and Vietnam, an infusion of the bark is used to correct nervous affections and as a stimulant as well as a tonic and believed to ameliorate the memory (3-4). It has been proven to have a rather good curative effect on treating common cold, jaundice, gastric pain, diarrhoea and ulcer (5). In Malaysia, this plant can also be used as an ingredient in 'lei cha', a traditional Hakka Chinese herbal tea which is believed to have powerful tonic effects.

Phytochemical studies on the stem, bark and the leaves of *Acanthopanax trifoliatum* have revealed a high content of diterpenoids such as continentalic acid (6-7), triterpenoid carboxylic acids (8-12), phenylpropanoid glycosides (13-15) and other compounds such as essential oils, lipids, steroids and alkanes (18-19)

Thus far, there have been only few pharmacological studies on *Acanthopanax trifoliatum* in the literature. It was reported to show evidence for anti-oxidative (20-21), anti-mutagenic (22), anti-nociceptive (5) and anti-tumour (23) effects when tested on the leaf extract. So far, there is no study on its anti-ulcerogenic effect been reported on this plant yet. It is widely known that ulcer is a kind of inflammation and inflammation is always accompanied by ulcer. This plant was proven to have anti-inflammatory activity; hence it is justifiable to screen this plant for anti-ulcerogenic properties., as plant with both activities are of particular therapeutic importance, as it can reduce risks of ulceration caused by NSAIDs treatment (24).

Methods

Preparation of Plant Extract

The leaves were collected from Bangi, Selangor, Malaysia . A voucher specimen was deposited at the Herbarium of Forest Research Institute in Kepong, Selangor, Malaysia.

The leaves were separated from the stem, washed, air-dried, and then oven-dried at 40°C. The dehydrated leaves were grinded into powdered form and soaked in 90% ethanol for 2 days. The extracted solvent was then filtered and was concentrated by using rotary evaporator until the solvent was completely removed and crude extract was obtained.. The extract was then dissolved with 1% Carboxymethylcellulose (CMC) and was prepared into desired dose concentrations for pharmacological testing.

Animals and Experimental Design

Healthy male *Sprague dawley* rats, weighing 200-300 g were obtained from the Animal House, Faculty of Medicine and Health Sciences, Universiti Putra Malaysia. The animals were kept in metal cages at room temperature under standard environmental condition and were fasted 24 hours before the experiment but were allowed free access of water. All the procedures were conducted in accordance with the guide line for Animal Ethic. The use of animals in this project was approved by the Animal Care and Use Committee (ACUC); Approval No. UPM/FPSK/PADS/BR-UUH/00333.

Ruling out ulcerogenic properties

A preliminary study was conducted to determine whether EAT alone can cause ulceration. A group of male Sprague-Dawley (SD) rats (n=6) was fasted for 24 hours prior to administration of a single dose of EAT (300 mg/kg) orally. The rats were then sacrificed at 3 and 6 hours later. The stomach was immediately removed, opened along the greater curvature, rinsed with normal saline, and examined for any gastric lesion.

Absolute ethanol-induced ulcer

This experiment was performed according to an established procedure (25) with some modifications. Male SD rats were fasted for 24 hours and divided into five groups. They were pre-treated orally with 1% CMC (vehicle), EAT (30, 100 and 300 mg/kg respectively) or lansoprazole (30 mg/kg) 30 minutes after treatment, all rats received 1 ml of absolute ethanol orally to induce gastric ulcer. The animals were sacrificed 1 hour later and their stomachs were immediately removed to determine the lesion damage.

Non-steroidal anti-inflammatory drug (NSAID)-induced ulcer

The experiment was performed according to the method of Hayden *et al.* (26) with some modifications. In this model, gastric ulcer was induced by using diclofenac, administered to male SD rats after 24 hours of fasting. 1% CMC, EAT (30, 100 and 300 mg/kg), or ranitidine (100 mg/kg) were administered orally 30 min before the induction of ulcer by oral diclofenac (150 mg/kg). The animals were sacrificed 6 hours after treatment with the inducer. The stomachs were immediately removed and examined for gastric damage.

Ethanol-induced gastric mucosal lesion in L-NAME-pre-treated rats

This method was performed as described by Arrieta *et al.* (27) with some modification. The rats were fasted for 24 hours prior to treatment with L-NAME (70 mg/kg) or normal saline intra-peritoneally. 30 min later, the animals received an oral dose of the vehicle (1% CMC), EAT (500 mg/kg) or carbenoxolone (100 mg/kg). After 30 minutes, gastric ulcer was induced with 1ml of absolute ethanol in all groups. Animals were sacrificed 1 hour after the administration of ethanol and immediately afterwards, the stomachs were removed to determine the gastric damage.

Ethanol-induced gastric lesions in NEM-pre-treated rats

Priorly, the rats were fasted for 24 hours. Based on method by Matsuda *et al.* (28), the rats were then treated subcutaneously with NEM (*N*-ethylmaleimide, 10 mg/kg) or saline. Thirty minutes later, the different groups received an oral dose of the vehicle (10 ml/kg), carbenoxolone (100 mg/kg) and EAT (500 mg/kg). After 30 minutes, all groups were orally treated with 1ml of absolute ethanol for gastric-ulcer induction. The animals were

sacrificed 1 hour after the administration of ethanol and their stomachs were immediately excised for gastric damage determination.

Ulcer scoring and measurement of total area of lesion

Immediately after the animals were sacrificed, each stomach was cut open at the greater curvature and the content was washed out carefully with normal saline. The flesh was spread out flat inside-up on a dry Petri dish. The mucosal surface was observed carefully and scored for the degree of ulceration using modified scoring method by Martin *et al* (29)

Statistical analysis

Data was expressed as mean \pm S.E.M. The results of the experiments were expressed as changes of percentage from control values. Differences between groups were assessed by means of analysis of variance (ANOVA), followed by Least Significant Difference (LSD) test for post-hoc comparison of group means. For all tests, effects with probability of $p < 0.05$ were considered significant.

Results

Ruling-out ulcerogenicity

The stomachs of rats pre-treated with the highest dosage used ie EAT 300 mg/kg were observed to be completely normal. No rats showed abnormal behaviour nor died in this experiment. This shows that EAT is not toxic to rats at this dose. No ulcer or any kind of lesion was seen on all stomach at both 3 hours and 6 hours duration of experimental period. Thus, EAT is concluded to be non-ulcerogenic to stomach of rats. With this, the investigation of gastroprotective properties of *Acanthopanax trifoliatum* was continued.

Absolute ethanol-induced ulcer

Negative control group which was pre-treated with the vehicle scored 4.83 ± 0.167 of gastric lesion. The stomach of rats in the EAT-pre-treated groups resulted in mean scores of 3.83 ± 0.543 , 4.20 ± 0.583 , and 3.33 ± 0.494 for doses of 30, 100, and 300 mg/kg respectively. During the dissection, there was some mucin observed together with the extract in the stomach of rats pre-treated with EAT, whilst the standard drug, lansoprazole (30 mg/kg) scored 3.50 ± 0.500 . However, there was no significant difference in scores shown between the groups. Even though there was no significant difference between scores of dose 300 mg/kg and the positive control group, there was tendency for the treatment to be comparable to the standard drug. The inhibition percentage of EAT 300 mg/kg (31%) was shown to be slightly better than the standard drug, lansoprazole (28%) of dose 30 mg/kg. Therefore, much higher dose ie 500 mg/kg was used for the next experiment in determining the possible involvement of either sulfhydryl and/or nitric oxide group in its pathway.

NSAID (diclofenac) - induced ulcer

The data was analyzed with ANOVA and showed significant difference between the groups. Mean ulcer score of the negative control group was 3.17 ± 0.543 . Pre-treatment with EAT 30 mg/kg cause the mean ulcer score to reduce to 2.67 ± 0.558 with 16% inhibition from the negative control. Whereas EAT 100 mg/kg and 300 mg/kg showed similar reduction of mean ulcer score to 2.50 ± 0.563 with 21% inhibition. However, these reductions of pre-treatment with the three doses of EAT groups were not statistically significant. On the other hand, the standard drug, ranitidine 100 mg/kg showed significant gastroprotection of NSAID-induced gastric lesion where the mean ulcer score was reduced to 0.50 ± 0.224 ($p < 0.005$) with 84% inhibition. This shows, EAT did not show a significant gastroprotective effect on NSAID-induced ulcer at these doses. Yet, it may show significant protection at much higher dosage.

Table 1. Effects of ethanol extract of *Acanthopanax trifoliatum* (EAT) on ethanol-induced and NSAID-induced gastric lesions in rats.

Inducer	Pre-treatment	Dose (mg/kg)	N	Ulcer Score	Inhibition (%)
Absolute ethanol	1% CMC	-	6	4.83 ± 0.167	-
	EAT	30	6	3.83 ± 0.543	21
		100	5	4.20 ± 0.583	13
		300	6	3.33 ± 0.494	31
		Lansoprazole	30	6	3.50 ± 0.500
Diclofenac (150 mg/kg)	CMC 1%	-	6	3.17 ± 0.543	-
	EAT	30	6	2.67 ± 0.558	16
		100	6	2.50 ± 0.563	21
		300	6	2.50 ± 0.563	21
		Ranitidine	100	6	$0.50 \pm 0.224^*$

Results are presented as Mean \pm S.E.M. * $P < 0.005$ represents significant difference from the control group using LSD test. Percentages of inhibition were calculated from comparison with the control group. $P < 0.05$ is considered statistically significant by using ANOVA when compared with positive control .

Ethanol-induced gastric mucosal lesion in L-NAME-pre-treated rats

As shown in Table 2, Analysis with ANOVA shows significant difference between the scores. EAT treatment with L-NAME produced a reduction (30%) when compared to L-NAME-pre-treated control value of 5.00 ± 0.000 . This result is very similar to the protective activity observed by pre-treatment of EAT with saline as compared with the control (30%). This shows that pre-treatment of L-NAME did not alter EAT-induced protection, thus excluding role of NOs in mediating protective effect of EAT.

Ethanol-induced gastric mucosal lesion in NEM-pre-treated rats

ANOVA revealed significant difference in between the groups. The result shows increased gastric lesions in control group of pre-treatment with NEM (5.00 ± 0.365) compared to control with saline pre-treatment (2.83 ± 0.703). On the contrary, EAT treatment with saline showed significantly better inhibition (29%) than with NEM (20%). Thus, this significant attenuation ($p < 0.005$) shows that there is possible participation of SHs in gastroprotection effect of *Acanthopanax trifoliatum*

Table 2: Pathway investigation study

Blocker	Pre-treatment	Ulcer Score	Inhibition (%)
NO pathway			
Saline (i.p.)	1% CMC	3.33 ± 0.494	-
	EAT 500	2.00 ± 0.447	30
	Carbenoxolone	3.17 ± 0.401	5
L-NAME (i.p.)	1% CMC	$5.00 \pm 0.000^{**}$	-
	EAT 500	$3.50 \pm 0.619^*$	30
	Carbenoxolone	3.50 ± 0.563	30
SH pathway			
Saline (s.c.)	1% CMC	2.83 ± 0.703	-
	EAT 500	2.00 ± 0.258	29
	Carbenoxolone	2.67 ± 0.333	6
NEM (s.c.)	1% CMC	$5.00 \pm 0.365^{***}$	-
	EAT 500	$4.00 \pm 0.516^{***}$	20
	Carbenoxolone	3.50 ± 0.428	30

Results are presented as mean \pm S.E.M. * $P < 0.05$, ** $P < 0.01$, *** $P < 0.005$ indicates significant difference from saline pretreated group by using LSD Test. Percentages of inhibition were calculated from comparison with the control group by using ANOVA. $P < 0.005$ is considered statistically significant

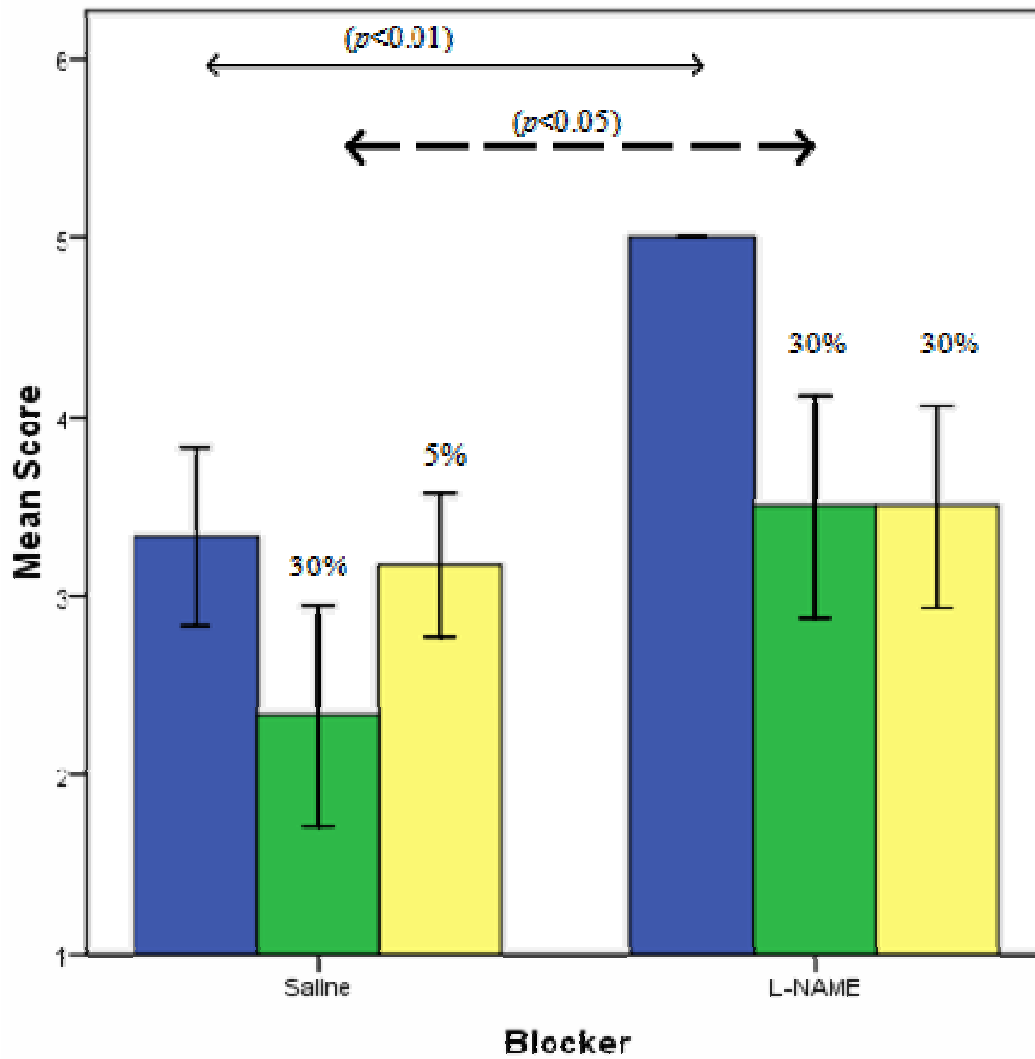


Figure 1 : Effects of ethanol extract of *Acanthopanax trifoliatum* (EAT) on gastric lesions induced by ethanol in rats pre-treated with L-NAME (an inhibitor of NO synthase).

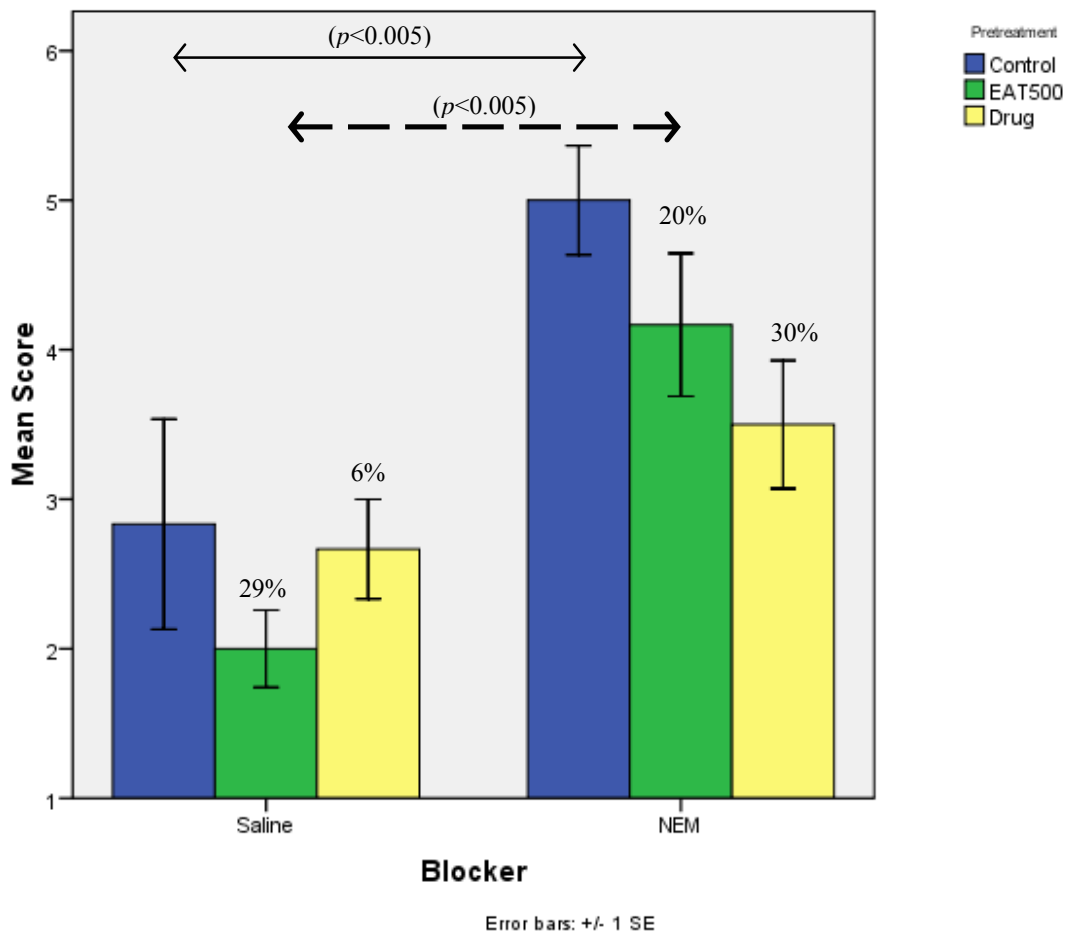


Fig 2 . Effects of ethanol extract of *Acanthopanax trifoliatum* (EAT) on gastric lesions induced by ethanol in rats pre-treated with NEM (a blocker of SHs). Results are presented as Mean \pm S.E.M. * $p < 0.005$ is considered statistically significant by using ANOVA

Discussion

As shown in the result of the preliminary study, there is no lesion seen at 3 and 6 hours in rats pre-treated with high dose of EAT (300 mg/kg). Hence, this result indicates strongly that EAT has no ulcerogenicity effect on stomach of rats. With this assumption, the study was continued to investigate the hypothesis that EAT can protect the stomach from ulceration especially on acute lesion.

In determining the gastroprotective activity of *Acanthopanax trifoliatum*, the control group was orally administered with absolute ethanol resulting in gastric lesions which most of the cases in this study was seen as haemorrhagic bands. Ethanol is one of the ulcerogenic agents that induces intense damage in gastric mucosa by promoting disturbances of mucosal microcirculation, ischemia and appearance of free radicals, endothelin release, degranulation of mast cells, inhibition of prostaglandins and decrease of gastric mucus production (30). Ohya and Guth (31) discovered that absolute ethanol causes rapid cessation of gastric mucosal flow which could be an important pathogenetic factor in the induction of tissue injury. In another study (32), histologic necrosis was seen in the mucosa when exposed to absolute ethanol. With cessation of blood flow and loss of delivery of needed oxygen and nutrients, the tissue would be more susceptible to ethanol injury.

In the ethanol induced ulcer model, used to screen drugs for cytoprotection (33), EAT seems to exhibit gastroprotective effects in a dose dependent manner as the two lower doses of EAT (30 and 100 mg/kg) did not show significant protective effects, but using a higher dose (300 mg/kg) have resulted in a higher inhibition percentage and a tendency to be of comparable effect with the standard drug, lansoprazole (Table 1). Based on this assumption, a higher dose (500 mg/kg) was used for the investigation of gastroprotective pathway study.

The gastrointestinal irritant properties of nonsteroidal anti-inflammatory drugs (NSAIDs) such as indomethacin or piroxicam are the major impediment to their use as anti-inflammatory drugs (34). Gastric ulcers associated with the use of nonsteroidal anti-inflammatory drugs (NSAIDs) remain a major problem in the clinical field (35).

Diclofenac sodium is a potent analgesic, non-steroidal anti-inflammatory drug (NSAID) used in painful diseases of rheumatic and non-rheumatic origin (36). Synthetic NSAIDs like diclofenac cause mucosal damage by interfering with prostaglandin (PG) synthesis, increasing acid secretion and back diffusion of H⁺ ions and thus leading to breaking up of mucosal barrier (37) The continuous generation of prostaglandins by cyclooxygenase isoenzymes in the gastric mucosa helps to maintain an adequate mucosal blood flow and also stimulates the generation of mucus (38). NSAIDs inhibit cyclooxygenase and thereby reduce the intrinsic ability of the mucosa to resist injury induced by endogenous and exogenous aggressors (39).

The use of diclofenac for inducing ulcer in the present study showed decent gastric lesion on the stomach rats. However, the ulcer lesion was not as prominent or severe as of ethanol-induced damage (Table 1). Pre-treatment of EAT shows some inhibition compared to the control group which was treated with vehicle only, but there was no significant difference between the groups. On the other hand, the standard drug, ranitidine exhibited significant protective activity and resulted in 84% inhibition when compared with the negative control group. The gastroprotective activity of EAT only occurs in ethanol-induced but not in NSAID-induced gastric lesion might be explained by the disability of EAT in protecting the gastric mucosa at the dosage used.

It is well known that NO is involved in the modulation of gastric mucosal integrity and is important in the regulation of acid and alkaline secretion, mucus secretion and gastric mucosal blood flow (40). It has been suggested that NO augments the release of mucus in stomach (41). On the other hand, it was reported that inhibition of NO by nitric oxide synthase (NOS) inhibitors decreased acid secretion in mice and dogs (42-43). The NO pathway is thought to be involved in promotion of gastric acid secretion through ECL (enterochromaffin-like) cells (44).

In order to investigate the role of endogenous NO in cytoprotection, we used the NO synthase inhibitor (L-NAME) to assess the gastroprotective effect of EAT on ethanol-induced gastric hemorrhagic lesion (Table 2, Figure 1). Pretreatment with L-NAME did not alter the cytoprotection induced by EAT. Oral administration of EAT to animals pretreated with L-NAME gave the similar inhibition (30%) when compared to EAT pretreated with saline. Therefore, it can be deduced that pre-treatment of L-NAME did not alter EAT-induced gastro-protection, thus excluding the role of endogenous NO in mediating cytoprotective effect of EAT.

Ethanol-induced gastric mucosal damage has also been associated with a significant depletion of non-protein sulphhydryl (NP-SH) concentrations in the gastric mucosa (45). The synthesis of mucus that strengthens the mucosa barrier against harmful agents also has an important function in gastric protection (46). Accordingly, the literature reports that endogenous non-protein sulphhydryl (NP-SH) compounds are key compounds in the mucosal protection against ethanol-induced gastric injury (47). Usually the growth in damage is accompanied by decrease of the concentration of mucosal NP-SH compounds, because the SH-groups bind the free radicals formed due to the action of noxious agents (46).

For this reason, we investigated the possible involvement of endogenous NP-SHs in the gastroprotective effect of EAT by pretreating animals with NEM (a SH-blocker) in gastric lesion induced by ethanol (Table 2; Figure 2). Pretreatment of animals with NEM markedly increases the gastric lesions when compared to control groups (Table 2). The gastroprotective effect of EAT observed by pretreatment with saline (29%) was significantly reduced ($P < 0.005$) when compared with the protection activity by pretreatment with NEM (20%), thus indicating a possible participation of the endogenous SHs in the gastroprotective effect of EAT. This might be due to the anti-oxidative compounds in the extract (20-21). NP-SHs compounds may be involved in scavenging oxygen-derived free radicals and controlling the production and nature of mucus (48-49).

The sulphhydryl compounds bind to free radicals that are formed following tissue injury by noxious agents. These agents may also protect mucus, since mucus subunits are joined by disulfide bridges that, if reduced, render mucus water-soluble (50). Therefore the anti-oxidative compounds present in EAT can prevent the loss of gastric mucus and NP-SH, since they are able to remove free radicals formed due to ethanol-induced mucosal ulcer.

In conclusion, ethanolic extract from *Acanthopanax trifoliatum* was shown to have substantial gastroprotective effect on the gastric mucosa of rats induced by absolute ethanol at dose 300 mg/kg. Therefore, at much higher dosage (500 mg/kg), another study was done to determine the possible role of either NO or SH group in its gastroprotective effect. From the data obtained, the gastroprotective effect of *Acanthopanax trifoliatum* in ethanol-induced ulcer model was found to be mediated not by the nitric oxide pathway, but the involvement of endogenous sulphhydryls that increase the defence mechanism of the gastric mucosa against aggressive factors in the stomach. This might be due to the similar anti-oxidative compounds reported in the leaves of the plant priorly. Therefore, further study on the phytochemical constituents of the extract should be conducted in order to confirm the exact mechanism underlying the effects of EAT.

Acknowledgement

The authors wish to thank the Faculty of Medicine and Health Sciences, Universiti Putra Malaysia for the facilities and funding provided for the study.

References

1. Perry LM, Metzger J. Medicinal plants of East and Southeast Asia: attributed properties and uses. (MIT Press, Cambridge, MA. 1980) pp. 40
2. Loi DT. Glossary of Vietnamese Medical Plants. (Science and Technics, Hanoi) pp 392
3. Agence de Coop´eration Culturelle et Technique, 1990a. Les plantes m´edicinales au Vietnam: m´edecine traditionnelle et pharmacop´ee, Livre 1. Agence de Coop´eration Culturelle et Technique, Paris
4. Wiart C. Ethnopharmacology of Medicinal Plant: Asia and The Pacific. (Humana Press, Totowa, NJ.2006) pp 117.
5. Sainan S, Sulaiman MR, Somchit MN, Hidayat MT, Zakaria ZA. Evaluation of antinociceptive activities of *Acanthopanax trifoliatum* in mice. (Proceedings of the 20th . Scientific Meeting of The Malaysian Society of Pharmacology and Physiology 2005) pp. 26.
6. Phan VK, Cai XF, Chau VM, Lee JJ, Kim YH, Kaurane-Type Diterpene Glycoside from the Stem Bark of *Acanthopanax trifoliatum*. *Planta Medica* 2004; 70: 282–284.
7. Nguyen TP, Kyung AL, Su JJ, Cai XF, Jung KC, Kim YH, Kang JS. Capillary electrophoretic method for the determination of the diterpenoid isomers in *Acanthopanax* species. *Journal of Pharmaceutical and Biomedical Analysis* 2006; 40:56-61.

8. Ty PD, Lischewski M, Phiet HV, Preiss A, Nguyen PV, Adam, G. 3 α ,11 α -Dihydroxy-23-oxo-lup-20(29)-en-28-oic acid from *Acanthopanax trifoliatum*. *Phytochemistry* 1985; 24:867-869.
9. Ty PD, Lischewski M, Phiet HV, Preiss A, Sung TV, Schmidt J, Adam G. Two triterpenoid carboxylic acids from *Acanthopanax trifoliatum*. *Phytochemistry* 1984; 23:2889-2891.
10. Kutschabsky L, Pfeiffer D, Lischewski M, Ty PD, Adam G. Molecular and crystal structure of a new 24-nor-triterpenoid carboxylic acid from *Acanthopanax trifoliatum*. *Croatica Chemica Acta* 1985; 58: 427-434.
11. Lischewski M, Kutschabsky L. Two 24-nortriterpenoid Carboxylic acids from *Acanthopanax trifoliatum*. *Phytochemistry* 1985; 24:2355-2357.
12. Kiem PV, Cai ZF, Minh CV, Lee JJ, Kim YH. Lupane-triterpene Carboxylic Acids from the Leaves of *Acanthopanax trifoliatum*. *Chem. Pharm. Bull.* 2003; 51:1432-1435
13. Yook CS, Kim IH, Hahn DR, Nohara T, Chang SY. A lupane-triterpene glycoside from leaves of two *Acanthopanax*. *Phytochemistry* 1998; 49: 839-843.
14. Yook CS, Chang SY, Lai JH, Ko SK, Jeong JH, Nohara T. Lupane-Glycoside of *Acanthopanax trifoliatum* forma *tristigmatis* Leaves. *Arch Pharm Res* 1999; 22:629-632.
15. Phan VK, Chau VM, Nguyen TD, Cai XF, Lee JJ, Kim YH. Two new phenylpropanoid glycosides from the stem bark of *Acanthopanax trifoliatum*. *Arch. Pharm. Res.* 2003; 26: 1014–1017.
16. Chen FC., Lin YM, Lin S. Constituents of Three-leaved *Acanthopanax*. *Phytochemistry* 1972; 11:1496-1497.
17. Chen FC, Lin YM, Yu PL. Constituents of *Acanthopanax trifoliatum*. *Phytochemistry* 1973; 12: 467-468.
18. Muselli A, Hoi TM, Cu LD, Moi LD, Bessiere JM, Bighelli A, Casanova J. Composition of the essential oil of *Acanthopanax trifoliatum* (L.) Merr. (Araliaceae) from Vietnam. *Flavour and Fragrance Journal* 1999; 14(1):41-44.
19. Du J, Gao L. Chemical constituents of the leaves of *Acanthopanax trifoliatum* (Linn) Merr. *China Journal of Chinese Materia Medica* 1992; 17:356-357
20. Sithisarn P, Jarikasem S. Antioxidant Activity of *Acanthopanax trifoliatum*. *Med Principles & Practice* 2009; 18: 393-398
21. Praphasawat R, Klungsupya P, Ezure Y, Suwanagul A, Theangtrong N, Himakhoun L, Arunpaiojana V. *Phytochemistry and antioxidant activities of the leaf extracts of Acanthopanax trifoliatum* The Thai Journal of Pharmaceutical Sciences 2005 ; 2: 13-16
22. Meng Z, Sakai Y, Ose Y, Sato T, Nagase H, Kito H, Matsuda H, Sato M, Mizuno M. Anti-mutagenic activity of medicinal plants in traditional Chinese medicines. *Mutation Research/Environmental Mutagenesis and Related Subjects* 1988; 30(5): 378-379
23. Chen C H. Study of Anti-Tumor Effect of *Acanthopanax trifoliatum*; Understand of Knowledge and Attitude of Chinese Herb between Nurses and Society in Eastern Taiwan. Ph.D Thesis 2006. Graduate Institute of Medical Sciences, Tzu Chi University, Taiwan.

24. Borrelli F, Izzo AA. The plant kingdom as a source of anti-ulcer remedies. *Phytotherapy Research* 2000; 14:581–591
25. Morimoto Y, Shimohara K, Oshima S, Sukamoto T. Effects of the new anti-ulcer agent KB-5492 on experimental gastric mucosal lesions and gastric mucosal defensive factors, as compared to those of terpenone and cimetidine. *Japanese Journal of Pharmacology* 1991; 57:595–605.
26. Hayden LJ, Thomas G, West GB. Inhibitors of gastric lesions in the rat. *Journal of Pharmacology* 1978; 30:244–246.
27. Arrieta J, Benitez J, Flores E, Castillo C, Navarrete A. Purification of gastroprotective triterpenoids from stem bark of *Amphipterygium adstringens*; roles of prostaglandins, sulphidryls, nitric oxide and capsaicin neurons. *Planta Medica* 2003; 69:905–909.
28. Matsuda H, Li Y, Yoshikawa M. Roles of capsaicin sensitive sensory nerves, endogenous nitric oxide, sulphidryls, and prostaglandins in gastroprotection by mormodin Ic, an oleanolic acid oligoglycoside, on ethanol-induced gastric mucosal lesion in rats. *Life Sciences* 1999; 65:27–32.
29. Martin MJ, Marhuenda E, Perez-Guerrero C, Franco JM. Antiulcer Effect of Naringin on Gastric Lesions Induced by Ethanol in Rats. *Pharmacology* 1994; 49:144-150
30. Abdel-Salam OM, Czimmer J, Debreceni A, Szolcsányi J, Mózsik G. Gastric mucosal integrity: gastric mucosal blood flow and microcirculation. *Journal of Physiology (Paris)* 2001; 95:105–127.
31. Ohya Y, Guth PH. Ethanol-Induced Gastric Mucosal Blood Flow and Vascular Permeability Changes in the Rat. *Digestive Diseases and Sciences* 1988; 33(7): 883-888.
32. Bou-Abboud CF, Morishita T, Paulsen G, Guth PH. Microcirculatory stasis precedes tissue necrosis in ethanol-induced gastric mucosal injury. *Gastroenterology* 1986; 90:1352.
33. Robert A. Cytoprotection by prostaglandins. *Gastroenterology* 1979; 77: 761–767.
34. Chiba T, Sato K, Kudara N, Shinozaki H, Ikeda K, Sato K, Endo M, Orii S, Suzuki K. Upper gastrointestinal disorders induced by non-steroidal anti-inflammatory drugs. *Inflammopharmacology* 2008; 16:16–20.
35. Hawkey CJ, Langman MJ. Non-steroidal anti-inflammatory drugs: overall risks and management. Complementary roles for COX-2 inhibitors and proton pump inhibitors. *Gut* 2003; 52:600–608.
36. Moser P, Sallmann A, Wiesenberg I. Synthesis and quantitative structure-activity relationships of diclofenac analogues. *J. Med. Chem.* 1990; 33:2358–2368.
37. Vane JR. Inhibition of prostaglandin synthesis as a mechanism of action for aspirin like drugs. *Nature New Biol.* 1971; 231: 232–238.
38. Ishihara K, Kuwata H, Ohara, S., et al., 1988. Changes of rat gastric mucus glycoproteins in cytoprotection: influences of prostaglandin derivatives. *Digestion* 39:162–171
39. Heeba GH, Hassan MKA, Amin R. Gastroprotective effect of simvastatin against indomethacin-induced gastric ulcer in rats: Role of nitric oxide and prostaglandins. *European Journal of Pharmacology* 2009; 607:188–193.

40. Chandranath SI, Bastaki SM, Singh J. A comparative study on the activity of lansoprazole, omeprazole and PD-136450 on acidified ethanol- and indomethacin-induced gastric lesions in the rat. *Clinical Experimental Pharmacology and Physiology* 2002; **29**:173–180.
41. Brown JF, Hanson PJ, Whittle BJ. Nitric oxide donors increase mucus gel thickness in rat stomach. *European Journal of Pharmacology* 1992; 223:103 -104.
42. Hasebe K, Horie S, Yano S, Watanabe K. Inhibitory effect of Nw- nitro-L-arginine on gastric secretion induced by secretagogues and vagal stimulation in the isolated stomach. *Eur J Pharmacol* 1998; 350: 229 -236.
43. Bilski J, Konturek SJ, Cieszkowski M, Pawlik WW. Endogenous nitric oxide in the regulation of gastric acid secretion, gastrin release and blood flow. *Biomed Res.* 1994; 15(2): 63–67.
44. Hasebe K, Horie S, Komasa M, Yano S, Watanabe K. Stimulatory effects of nitric oxide donors on gastric acid secretion in isolated mouse stomach. *European Journal of Pharmacology* 2001; 420: 159–164.
45. Rogers C, Brown BS, Szabo S. Gastric mucosal protection by new awl sulphhydryl drugs. *Dig Dis Sci.* 1988; **33**:324-329.
46. Andreo MA, Ballesteros KVR, Hiruma-Lima CA, daRocha LRM, Souza Brito ARM, Vilegas W. Effect of *Mouriri pusa* extracts on experimentally induced gastric lesion in rodents: Role of endogenous sulphhydryls compounds and nitric oxide in gastroprotection. *Journal of Ethnopharmacology* 2006; 107:431-441.
47. Szabo S, Vattay P. Experimental gastric and duodenal ulcers. *Advances in pathogenesis. Gastroenterology Clinical North America* 1990; 19:67-85.
48. Allen A, Cunliffe WJ, Pearson JP, Sellers LA, Ward R. Studies on gastrointestinal mucus. *Scandinavian Journal of Gastroenterology* 1984; 93:S101-S113.
49. Salim AS. Sulphydryl- containing agents: new approach to the problem of refractory peptic ulceration. *Pharmacology* 1993; 46:281-288.
50. Avila JR, de la Lastra CA, Martin MJ, Motilva V, Luque I, Delgado D, Esteban J, Herrerias J. Role of endogenous sulphhydryls and neutrophil infiltration in the pathogenesis of gastric mucosal injury induced by piroxicam in rats. *Inflammation Research* 1996; **45**:83–88