

Hepatoprotective Activity of Fruit Extract of *Sesbania Grandiflora*, Pers.

Prafulla R. Tathe^{1*}, Bheemachari¹, Vaibhav Uplanchiwar², Anuj Modi², Avinash Gahane²,
Sunil K. Jain², Rahul Jain²

1. Department of Pharmacology, N.E.T. Pharmacy College, Raichur, K.A. (India)
2. Department of Pharmacology, ADINA Institute of Pharmaceutical Sciences, Sagar, M.P. (India)

Summary

Sesbania grandiflora, Pers (Fabaceae), commonly known as Hadaga. Fruits are widely used in the treatment of jaundice, colic, poisoning, sinus and tambours growths. In the present study fruits of *Sesbania grandiflora*, Pers was investigated for *in-vivo* hepatoprotective effects using ethanol as toxicant and silymarin as standard drug in Wister albino rats. Different groups of rats were treated with ethanol (3.76gm/kg p.o., BD), silymarin (100mg/kg p.o., BD) and different dose level of petroleum ether extract for 25 days. The effects of treated groups on wet liver weight, wet liver volume, serum transaminase (SGOT, SGPT), alkaline phosphatase (ALP), bilirubin (Direct and Total), Total albumin and total protein were measured. *Sesbania grandiflora* shows significant ($p < 0.01$) hepatoprotective effect at a dose of 400mg/kg, p.o. compared to that of toxicant group. Histopathological studies also reveal the normal hepatocytes with normal lobular architecture compared to that of toxicant group.

Keywords: *Sesbania grandiflora*, Hepatoprotective activity; Ethanol; Rats.

Corresponding Address

Mr. Prafulla R. Tathe
Department of Pharmacology,
N.E.T. Pharmacy College, Raichur,
Karnataka. India, 584103
E Mail: pr_tathe@yahoo.co.in
Contact No. (+91)9423063055

Introduction

Liver, the key organ of metabolism and excretion is constantly endowed with the task of detoxification of xenobiotics, environmental pollutants and chemotherapeutic agents. Thus, disorders associated with this organ are numerous and varied. While a curative agent has not yet been found in modern medicine. The current usage of corticosteroid and immunosuppressive agents only brought about symptomatic relief^[1]. Furthermore, their usage is associated with risk of relapses and dangerous side effects. On the other hand, Ayurveda, and indigenous system of medicine in India, has a long tradition of treating liver disorders with plant drugs (1).

Sesbania grandiflora, Pers (Fabaceae) which is commonly known as Hadga. According to ethnomedical information the plant used for treating various ailments sinus and tambours growths. Fruits are used to treat hepatitis. Leaves are useful in gonorrhoea in the male and leucorrhoea in female. Bark is useful as infusion in the first stages of small pox and other eruptive fevers. Root is given with honey in catarrh. Juice of leaves and flowers is popular remedy for nasal catarrh and headache when it is sniffed up the nostrils. Juice of the flowers is squeezed into the eyes to relieve the dimness of vision. Juice of flower is ideal as expectorant. Therefore, to justify the traditional claims, we have assessed the hepatoprotective effect of *Sesbania grandiflora* fruits using ethanol intoxicated rats (2, 3).

Materials and Methods

Drugs and chemicals

Silymarin was obtained from Micro labs, Bangalore. The kits for all biochemical estimations were purchased from Erba Diagnostics Mannheim GmbH Germany. The other chemicals used were of analytical grade.

Plant material collection and extraction

The plant specimens were collected from local area of Jalana dist. Maharashtra, India, during the month of January 2008. It was authenticated by Dr. Veda Vyas, H.O.D, Dept. of botany, L.V.D College of Biosciences, Raichur (K.A.). A voucher specimen no. NET/2008/14 has been deposited at N.E.T Pharmacy College, Raichur. Shed dried powder of fruit of *Sesbania grandiflora* was exhaustively extracted with petroleum ether. The extracted were collected, concentrated by under vaccum and semisolid mass were obtained. The suspensions were used to assess hepatoprotective activity.

Qualitative phytochemical screening

Freshly prepared petroleum ether extracts of *Sesbania grandiflora* fruits were tested for the presence of phytochemical constituents by using reported methods(4, 5, 6).

Animals

Albino rats (Wistar strain) and mice of either sex weighing between 150-200 g and 20-30 g respectively were procured from the Central Animal House of N.E.T Pharmacy College, Raichur, Karnataka. The animals were acclimatized for seven days under laboratory conditions. The animals were fed with commercially available rat pelleted diet (Amrut laboratories Pranava Agro Industries Ltd. Sangli). Water was allowed *ad libitum*. The study protocols were duly approved by the Institutional Animal Ethics Committee (IAEC No. 576/2002/bc/IAEC/CPCSEA) of N.E.T Pharmacy College, Raichur.

Acute toxicity studies

The acute toxicity of petroleum ether extracts of fruit of *Sesbania grandiflora* was determined by using albino mice (20-30g) as per OECD guideline no 425(7). The animals were fasted for 4 hrs prior to the experiment. Animals were administered with petroleum ether extract of fruit of *Sesbania grandiflora* up to 2 gm/kg body weight and observed for its mortality. No mortality or morbidity was observed. Thus 1/5th, 1/10th, 1/20th of maximum dose (400mg/kg, 200mg/kg and 100mg/kg) tested was selected for the present study.

Hepatoprotective activity**Alcohol induced-hepatotoxicity**

Albino rats of either sex weighing between 150-200 g were selected and divided into six groups of six animals in each. The animals were fasted 24 hours prior to experiment. Group A was maintained as normal control, which was given with distilled water only. Group B received ethanol (3.76 gm/kg, twice daily, p.o) and animals in Group C were treated with Silymarin (100 mg/kg, p.o) which served as standard. Animals in Groups D, E and F were treated with three different doses petroleum ether extracts of *Sesbania grandiflora* fruits(100mg/kg, 200mg/kg and 400mg/kg p.o., BD) respectively. Group B, C, D, E and F were intoxicated with ethanol for 25 days. On the 25th day, 3 hrs after last dose of ethanol, the animals were anaesthetized with ether. Blood was withdrawn through retro orbital plexus and biochemical parameters like ALT, AST, ALP, direct bilirubin, total bilirubin, total proteins and albumin and physical parameters like wet liver weight and volume were estimated by standard procedure. The animals were sacrificed by overdose of ether and autopsied. Livers from all animals were removed, washed with saline, weighed and stored in 10% formalin. Histopathological studies were carried out by a modified method of Luna (9). The statistical analysis was carried out using one-way ANOVA followed by Dunnett's multiple comparisons for the data which are normally distributed(8, 9, 10).

Results: Table 1: Preliminary phytochemical screening

Constituents of petroleum ether extract of *Sesbania grandiflora* fruits using soxhlet apparatus

Sr. No.	Test	<i>Petroleum ether extract</i>
1	Glycosides	
A	Borntragers test	-
B	Legals test	-
2	Phytosterol	
A	Salkowski test	+
3	Fixed oils and fats	
A	Stain test	+
B	Soap test	+
4	Phenolics and tannins	
A	Ferric chloride test	-
B	Gelatin test	-
C	Lead acetate test	+
D	Alkaline reagent test	+
E	Shinoda test	+

Table 1: Effect of L-35 on wet liver weight, wet liver volume and on different biochemical parameters

Groups	Wet liver weight (gm/100gm)	Wet liver volume (ml/100gm)	Serum Biochemical Parameters						
			SGPT (u/l)	SGOT (u/l)	SALP (u/l)	Direct bilirubin (mg/dl)	Total bilirubin (mg/dl)	Total protein (mg/dl)	Albumin (mg/dl)
Normal control 10 ml/kg p.o	3.50±0.20	3.73±0.11	34.14±4.81	106.86±9.04	102.82±5.86	0.21±0.02	0.12±0.02	9.07±1.26	4.49±0.29
Toxicant (Ethanol 3.76 mg/kg, p.o.)	5.55±0.20	6.23±0.12	123.30±11.88	267.76±18.46	181.24±8.18	1.69±0.16	1.26±0.22	4.02±0.54	2.44±0.23
Silymarin (100mg/kg, p.o) + Ethanol	3.82±0.22**	4.25±0.12**	49.42±10.70**	111.43±4.02**	104.18±4.70**	0.23±0.21**	0.28±0.14**	7.43±0.33**	4.23±0.19**
PE extract (100mg/kg, p.o) + Ethanol	5.18±0.13 ^{ns}	5.82±0.10 ^{ns}	115.05±10.76 ^{ns}	224.96±5.99*	150.81±9.71*	1.21±0.06**	0.82±0.14 ^{ns}	5.85±0.40 ^{ns}	3.07±0.26 ^{ns}
PE extract (200mg/kg, p.o) + Ethanol	4.36±0.11**	4.84±0.08**	99.23 ±0.33 ^{ns}	165.17±5.32**	131.46±6.60**	0.84±0.11**	0.37±0.06**	6.18 ±0.29 ^{ns}	3.52 ±0.42 ^{ns}
PE extract (400mg/kg, p.o) + Ethanol	3.63±0.07**	4.53±0.09**	64.48±8.08**	122.34±6.77**	113.19±5.89**	0.55±0.07**	0.24±0.02**	6.52±0.32**	4.09 ±0.32**

Values are mean ± SEM (n=6) one way ANOVA followed by Dunnett's 't' test. Where, * represents significant at p<0.05, ** represents highly significant at p< 0.01, *** represents very significant at p<0.001 and ns represents non significant compared to control.

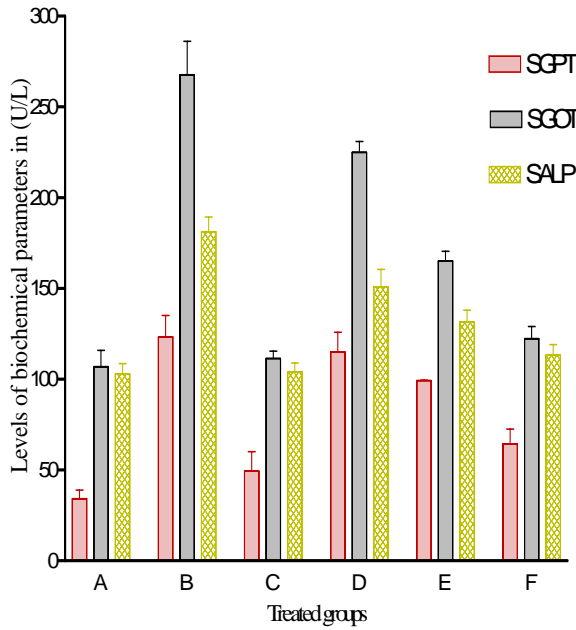


Figure 1. Effect of fruit extract of *Sesbania grandiflora* on SGPT, SGOT and SALP levels in ethanol induced hepatotoxic rats

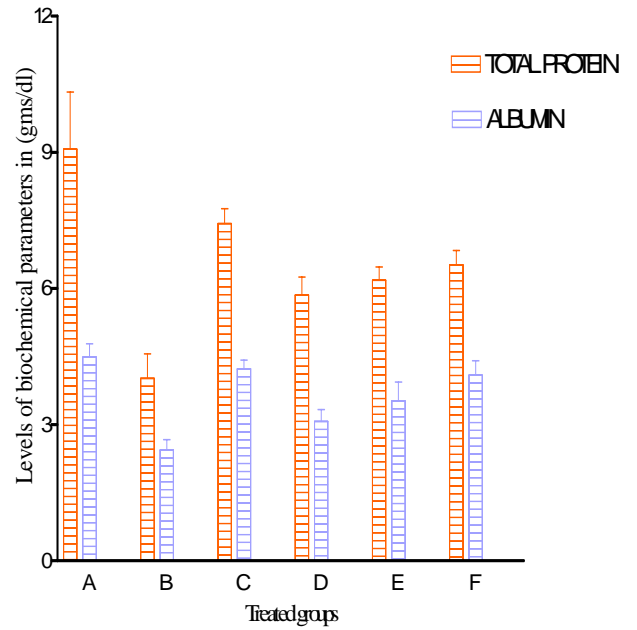


Figure 3. Effect of fruit extract of *Sesbania grandiflora* on Total protein and albumin level in ethanol induced hepatotoxic rats.

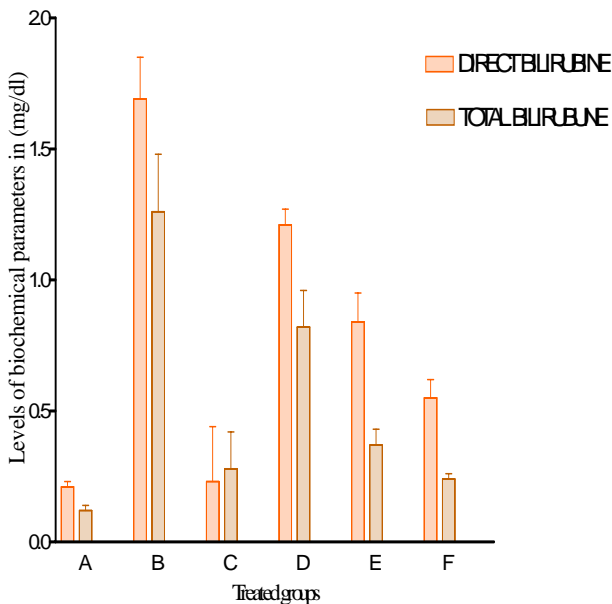


Figure 2. Effect of fruit extract of *Sesbania grandiflora* on direct bilirubin and total bilirubin levels in ethanol induced hepatotoxic rats

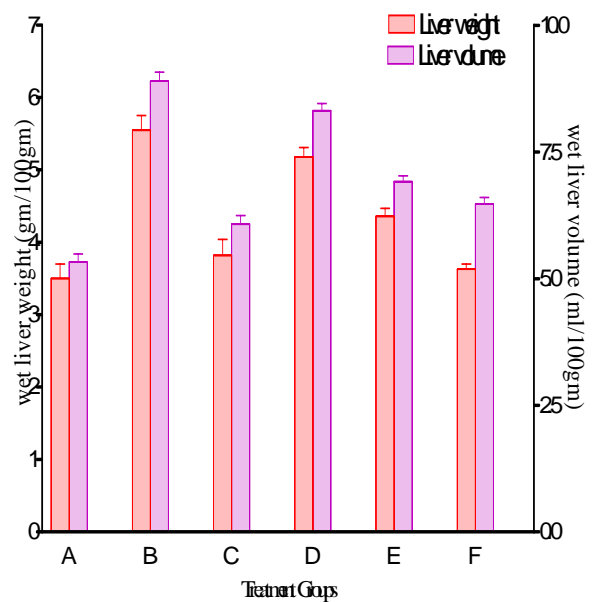


Figure 4. Effect of fruit extract of *Sesbania grandiflora* on wet liver weight and wet liver volume in ethanol induced hepatotoxic rats

Histopathology studies

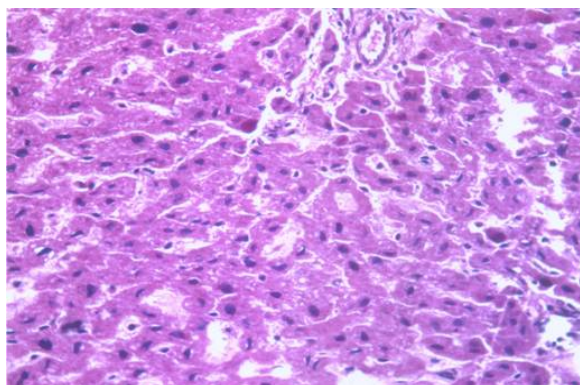


Figure 1. Normal group: The liver sections showed the normal lobular architecture of the liver with hepatocyte arranged in single cords. There is a centrally placed nucleus and occasional binucleate cells, the sinusoidal cells against which kupffer cell nucleus are abutting.

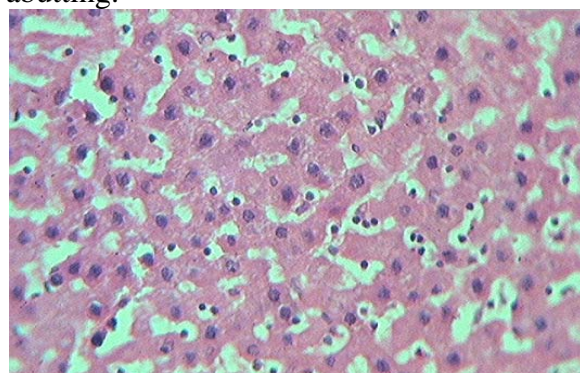


Figure 2. Toxicant group: The liver hepatocytes showed fatty changes and hydropic degeneration with loss of nuclear architecture.

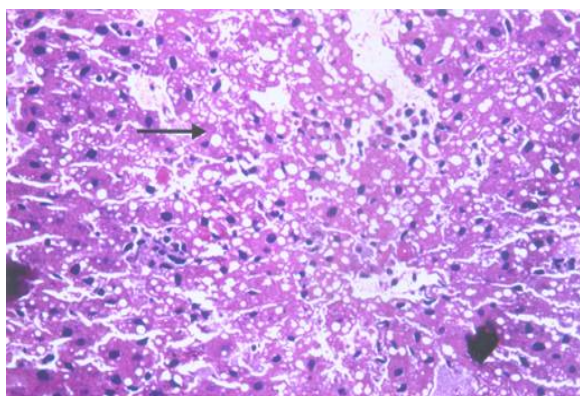


Figure 3. Silymarin + Ethanol treated group: In this group no fatty changes were observed and no hydropic degeneration that indicates prevention of hepatic damage induced by ethanol.

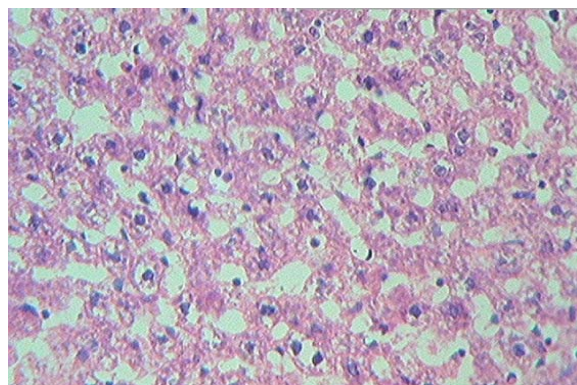


Figure 4. Petroleum ether extract (100mg/kg): The sections from the liver, showed minimal changes in the hydropic degeneration.

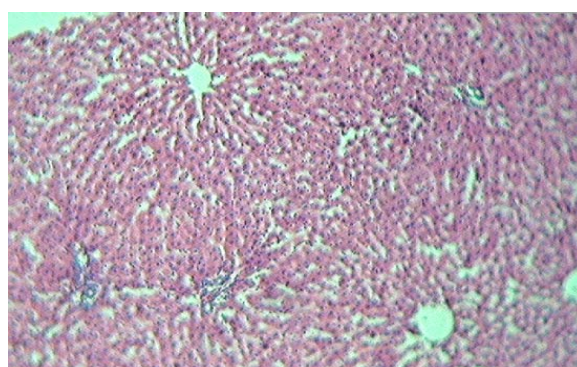


Figure 5. Petroleum ether extract (200mg/kg): The sections from the liver, showed moderate changes in the centrilobular necrosis and hydropic degeneration.

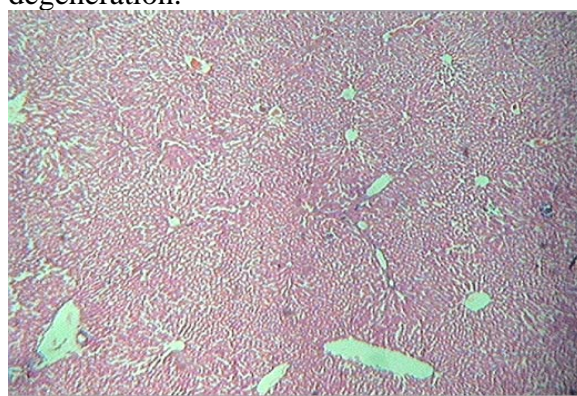


Figure 6. Petroleum ether extract (400mg/kg): The liver sections showed minimal degeneration and fatty change with retention of normal lobular architecture, which confirms hepatoprotective activity.

Discussion

Increased formation of lipoperoxides, conjugated diens and malondialdehyde (MDA) and reduced levels of antioxidants like vitamin E and glutathione in the tissues have been demonstrated in experimental animals administered with ethanol as well as alcoholic human subjects. The increased level of AST, ALT, ALP and bilirubin is conventional indicator of liver injury. Oxidative stress is one major factor in etiology of ethanol injury, mainly by Kupffer cell derived reactive oxygen species (ROS) and ethanol activates Kupffer cells primarily through the action of a substance called endotoxin, which is released by certain gram-negative bacteria present in the intestine, activates Kupffer cell to generates ROS and pro inflammatory cytokines (TNF alpha, IL-1), both of them can lead to liver damage (11).

Water is retained in the cytoplasm of hepatocyte leading to enlargement of liver cells, resulting in increased total liver weight and volume (12). Administration of ethanol for 25 days induces hepatotoxicity, causes cellular enzymes like alanine transaminase, aspartate transaminase, and alkaline phosphatase present in liver cells leak into serum, resulting in increased concentrations^[13]. Treatment with petroleum ether extract of *Sesbania grandiflora* fruits restores biochemical enzymes and brings down to normal as compared to standard. Most significant result $p < 0.001$ was found at a dose of 400mg/kg, body weight. The histopathological studies of petroleum ether extracts of *Sesbania grandiflora* fruits treated group showed minimal degeneration and fatty change with retention of normal lobular architecture, which confirms hepatoprotective activity.

Conclusion

Based on improvement in serum marker enzyme levels, physical parameters, histopathological studies and presence of phytoconstituents it is concluded that petroleum ether extract of *Sesbania grandiflora* fruits possesses significant hepatoprotective activity ($p < 0.001$) at a high dose of 400mg/kg, p.o. and thus supports the traditional application of the same under the light of modern science.

Acknowledgement

The authors wish to express their gratitude to the Prof. R. K. Jain, Principal, AIPS, Sagar (M.P.) and Dr. Veda Vyas, Head, Department of Botany, L.V.D. College, Raichur (K.A.) for their great support throughout work.

References

1. Korourian S, Hakkak R, Martin JJ, Susan R. Shelnutt, Waldron J, Magnus Ingelman-Sundberg, Thomas MB. "Diet and Risk of Ethanol-Induced Hepatotoxicity: Carbohydrate-Fat Relationships in Rats" Toxicological sciences 1999; 47:110 –117.
2. OECD 2001-Gudeline on acute oral toxicity (AOT) Environmental health and safety monograph series on testing and adjustment number 425.
3. Shukla V, Tiwari RK, Agarwal DP. "Hepatoprotective role of Picroliv isolated from *Picrorhiza kurroa* on alcohol-induced liver necrosis" Ad Pharmacol Toxicol, 2001; 2(1): 9-16.
4. Khandelwal KR, Ed. Practical Pharmacognosy Technique and Experiments, 23rd Ed: 2005; 15-29:149-56.

5. Kokate CK. Practical Pharmacognosy, 4th Ed. Vallabh Prakashan, 2005:112-120.
6. Farnsworth NR., Biological and phytochemical screening of plants. J. Pharm. Sci.1966;55: 225-276.
7. Kurma SR, Mishra SH. “Studies on *Curculigo orchooidesgaertn* for Anti-inflammatory and Hepatoprotective Activities”. Indian Drugs 1995; 29(6): 20-25.
8. Vipul G, Nilesh P, Venkat NR, Nandakumar N, Gouda TS, Shalam Md. Hepatoprotective activity of alcoholic and aqueous extract of leaves of *Tylophora indica* in rats. Ind J Pharmacol 2007; 39(1): 43-47.
9. Luna LG. Manual in histology and staining methods. McGraw Hill; New York, 1999.
10. Zhen-Ming Lu, Wen-Yi T, Xi-Liang Z, Hui-Zi Fu, Zong-Hua A. Protective effects of mycelia of *Antrodia camphorata* and *Armillariella tabescens* in submerged culture against ethanol-induced hepatic toxicity in rats. J Ethnopharmacol 2007; 110: 160–164.
11. Pornpen Pramyothin, Patcharavadee Samosorn, Somlak Pongshompoo, Chaiyo Chaichantipyuth. The protective effects of *Phyllanthus emblica* Linn. Extract on ethanol induced rat hepatic injury. J Ethnopharmacol 2006; 107:361–364.
12. Blanco CD, Gentil S. Alterations of glucose metabolism in chronic liver disease. Diab Res Clin Prac 8, 1990:29-36.
13. Deb AC. Fundamentals of biochemistry. 7th ed. New Central Book Agency: Kolkata,