

Nephroprotective and curative Activity of methanolic extract of *Ficus religiosa* L. latex in Albino Rats Using Cisplatin Induced Nephrotoxicity

Yogesh Chand Yadav^{1*}, D.N. Srivastava², Vipin Saini,¹ Sarita Singhal,¹ A.K. Seth³, Sharad kumar,¹ Tejas K. Ghelani¹ Anuj malik¹

¹MJRP College of Health Care & Allied Sciences, M.J.R.P University (Rajasthan)

²B.R. Nahata College of Pharmacy Mandsaur (M.P.)

³Department of Pharmacy Sumandeep Vidyapeeth, Pipariya Vadodara (G.P.)

Corresponding author: Yogesh Chand Yadav*

yogeshycpcology2@gmail.com Phone no. = +919723636234

Summary

The present study was designed to investigate the possible potential nephrocurative, and nephroprotective activity of 200mg/kg methanolic extract of *Ficus religiosa* L. latex was used against cisplatin (5mg/kg, i.p.) induced acute renal failure. The experimental protocol designed as the animals were divided into four groups (n=6) like control, model control, curative and protective groups were received vehicle, cisplatin, cisplatin + extract, and extract + cisplatin respectively. After 6th days, blood collected from retro-orbital sinus of rats and determined urea and creatinine level in serum of each group after then rats were sacrificed for quantitative estimation of various enzymes and ATPases content in kidney tissue. A single dose of cisplatin induced loss in body weight, increase urine excretion, increased urea & creatinine level in serum; it was significantly recovered by 200mg/kg curative and protective groups. The enzyme estimation in kidney tissue it found that increased malondialdehyde, and decreased superoxide dismutase, Catalase and reduced glutathione level; it was significantly monitored by 200mg/kg curative and protective groups. Finally it is concluded that the present study data conformed nephrotoxicity induced by cisplatin due oxidative stress and methanolic extract of *Ficus religiosa* L. latex may have nephroprotective and curative activity.

Keywords: Cisplatin; Nephrotoxicity; urea; creatinine; glutathione; Lipid peroxidation

Introduction

A large number of medicinal plants, natural products and dietary components have been evaluated as potential nephroprotective agents [1]. The *Ficus religiosa* (family-Moraceae) is widely planted in the tropics [2]. The tree is very long lived and one tree near Bombay is reported to be over 3,000 years old [3] The barks of *Ficus religiosa* species contains tannin, saponin gluanol acetate, β sitosterol, leucopelargonidin- 3 - O - β - D -glucopyranoside, leucopelargonidin - 3 - O - α -L - rhamnopyranoside, lupeol, ceryl behenate, lupeol acetate, α -amyrin acetate, leucoanthocyanidin, and leucoanthocyanin [4]. Some reported pharmacological activity of *F. religiosa* like fruit extracts exhibited antitumor activity in the potato disc bioassay [5], Aqueous extract was decreased the fasting blood glucose and exaggerated activity of superoxide dismutase SOD in streptozotocin induced type II diabetic rats [6], anthelmintic activity of the methenolic extract [7].

Aqueous extract showed high antimicrobial activity against selected pathogenic like *B. subtilis* and *P. aeruginosa* [8]. Cisplatin (cis-diamminedichloroplatinumII) (CDDP) is one of most potent anticancer drug. it is produced dose limiting nephrotoxicity and high dose of CDDP produce the impairment of kidney, causes decrease in renal blood flow, glomerular filtration rate and increases urea and creatinine level in blood [9]. The cisplatin induced nephrotoxicity was characterized by signs of injury such as changes in urine volume, body weight, increase the products of lipid peroxidation, and change renal clearance [10]. Kidneys have some antioxidant enzyme like superoxide dismutase (SOD), lipid peroxidase and glutathione (GSH), and Catalase which protect kidney from free radicals like nitric oxide and superoxide etc. The cisplatin is inhibited the activity of antioxidant enzyme in renal tissue like glutathione, SOD, GSH and Catalase depletion and increase thiobarbuturic acid – reactive substance (TBARS) [11]. Thus, the purpose of current study was to investigate whether oral administration of methanolic extract of *Ficus religiosa L.* latex has any protective and curative effect against cisplatin induced nephrotoxicity in albino rats.

Materials and methods

Drug and Reagents

Cisplatin (VHB, Life sciences Inc., India), DTNB (Merck pvt. Ltd., India). Glutathione (Merck pvt. Ltd., India), Thiobarbuturic acid (Loba chemicals pvt.ltd. India).

Plant material

Ficus religiosa L. latex was collected from village Pipariya dist. Vadodara (G.P., India). The plant was identified by Dr. Nagar (Professor of botany), M.S. University Vadodara (Gujarat) And voucher specimen (DPSV/F/01/2010) was submitted in department of Pharmacy, Sumandeep Vidyapeeth, Pipariya Vadodara , G.P. *Ficus religiosa L* latex was extracted using methyl alcohol as a solvent. The extract was dried by rotator evaporator under reduced pressure.

Animals

Adult male wistar rats having weight around 180-210 g were maintained at $25 \pm 2^\circ\text{C}$ and kept in well ventilated animal house under photoperiodic condition in large polypropylene cages were standard food and water *ad libitum*. The experiment was carried out in accordance to the guidelines mentioned in the CPCSEA, and Institutional Animal Ethical Committee approved the experiment protocols (Reg.No.-947/ac/06/CPCSEA).

Experimental design

The acute toxicity study of methanolic extract of *Ficus religiosa L.* latex was not occurred at 2000mg/kg (as per the OECD - 420) on male Wistar rats The dose was selected one tenth ($1/10^{\text{th}}$) and fifth ($1/5^{\text{th}}$) of it, for safe treatment.

Total duration of study was 16 days. The animals were divided into four groups containing six animals in each group. Group I served as control and received normal saline throughout the experiment, Group II (Modal Control) received single dose of cisplatin (5mg/kg i.p.), 1st days, Group III (Protective) received extract (200mg / kg p.o.) for 1st to 10th day and 11th day, single dose (5mg/kg, i.p.) of cisplatin was administered, Group IV (Curative) received same dose of cisplatin on day 1st, and after 6th days extract (200mg / kg p.o.) was administered up to 16th days.

Biochemical assays

After the treatment period, blood was collected from retro-orbital sinus of rat under ether anaesthesia and centrifuged using the table top centrifuge (REMI) at 3000 rpm to get serum. Level of urea and creatinine was estimated using Span diagnostic kit on chemical analyzer (microlab3000) for assessment of renal toxicity. [12&13], After then Kidneys were removed, homogenized and centrifuged at 10,000 rpm at 0°C for 20 min. the supernatant was used for estimation of different antioxidant level by calorimetric method using spectrophotometer (Merck thermo spectronic, Model NO. UV-1, double beam), Glutathione reductase (GSH) estimated by Sedlak and Lindsay method [14 & 15], Lipid peroxidation by thiobarbuturic acid-reactive substances (TBARS) methods [16, 17&18], Superoxide dismutase (SOD) by method developed by Misra and Fridovich (1972). [19], Catalase (CAT) by colorimetric assay [20].

Statistical analysis

Results were expressed as one way analysis of variance (ANOVA) followed by Dunnett's test and $P < 0.05$ was considered as significant.

Results

In present study rats treated with single dose of cisplatin shown significantly (** $P < 0.01$) reduction in body weight (9.00 ± 0.73) in model control group as compared to control group (1.50 ± 0.50). it was significantly (** $P < 0.01$) overcome with treatment of 200mg/kg methanolic extract of *Ficus religiosa* latex L. in protective and curative (fig.1), and excretion of urine volume was significantly (** $P < 0.01$) increased (14.66 ± 0.88) in model control group as compared with control group (5.33 ± 0.33). After injected the single dose of cisplatin (5mg/kg) causes increased urea (76.66 ± 2.24) and creatinine (2.32 ± 0.10) level in model control compare to respective control group (24.16 ± 1.04 and 0.94 ± 0.05) and its was recovered significantly (** $P < 0.01$) in curative and protective groups with treatment of 200mg/kg same extract (Table no.1). In aspect of kidney tissue estimation, it is shown as significantly (** $P < 0.01$) increase the lipid peroxidase (24.50 ± 0.61) and decrease the level of GSH (45.33 ± 1.66), SOD (07.16 ± 0.60) and CAT (201.67 ± 3.33) after single dose injection of cisplatin in model control group. The lipid peroxidase, GSH and CAT were significantly (** $P < 0.01$) monitored with dose 200kg/kg in curative and protective groups and in expect of SOD level, 200mg/kg dose in curative was less significantly ($*P < 0.05$) monitored (fig.4).

Table no.1. Effect of methanolic extract of *Ficus religiosa* L latex on the excretion urine volume, urea, and creatinine in blood serum.

S.No.	Groups	Urine volume (ml/24hr) on lost day of experiment	Urea level in serum (mg/dl)	Creatinine level in serum(mg/dl)
1.	Control	5.33 ± 0.33	24.16 ± 1.04	0.94 ± 0.05
2.	Model control	14.66 ± 0.88^a	76.66 ± 2.24^a	2.32 ± 0.10^a
3.	Protective (200mg/kg)	7.66 ± 0.66^b	46.50 ± 1.38^b	1.59 ± 0.08^b
4.	Curative (200mg/kg)	8.66 ± 0.66^b	49.66 ± 1.94^b	1.70 ± 1.32^b

^a= ** $P < 0.01$ as compared to the Control

^b= ** $P < 0.01$ as compared to the model Control

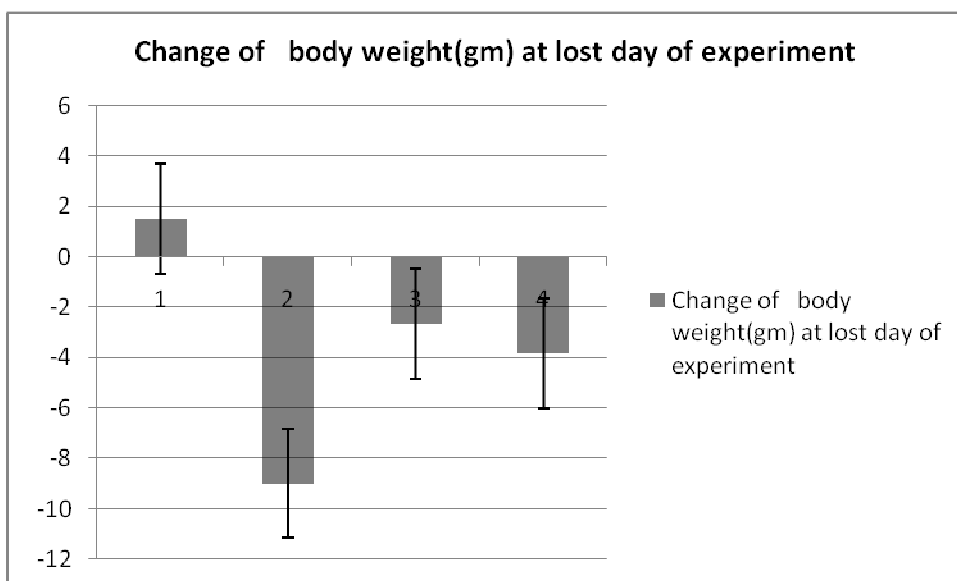


Figure1. Effect of methanolic extract of *Ficus religiosa* L latex on change body weight of various groups. Each group represents mean± S.D. of six animals, **P<0.01, **P>0.01, **P>0.01, as compared to the Model Control.

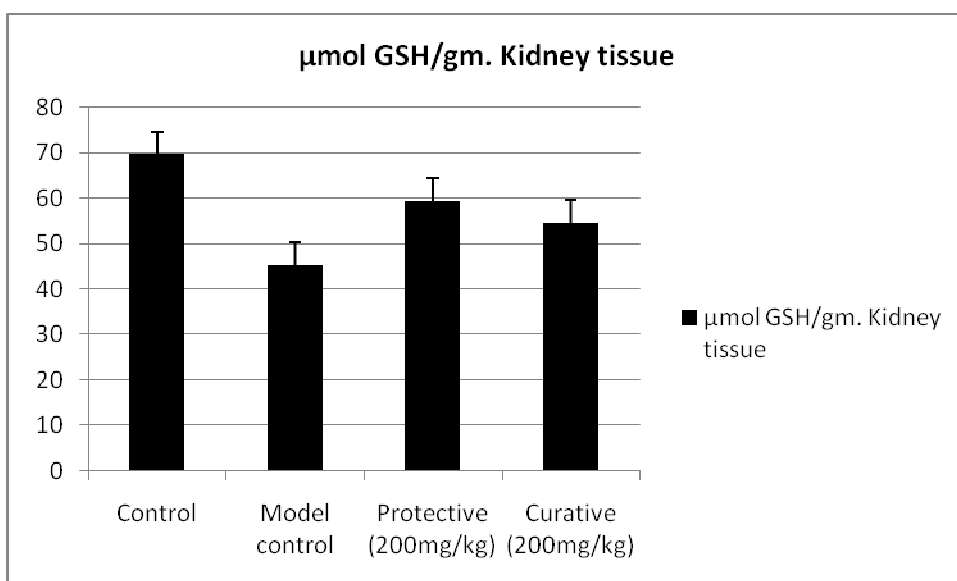


Figure2. Effect methanolic extract of *Ficus religiosa* L latex on GSH content of kidney tissue of various groups. Each group represents mean± S.D. of six animals, **P<0.01, **P>0.01, **P>0.01, as compared to the Model Control

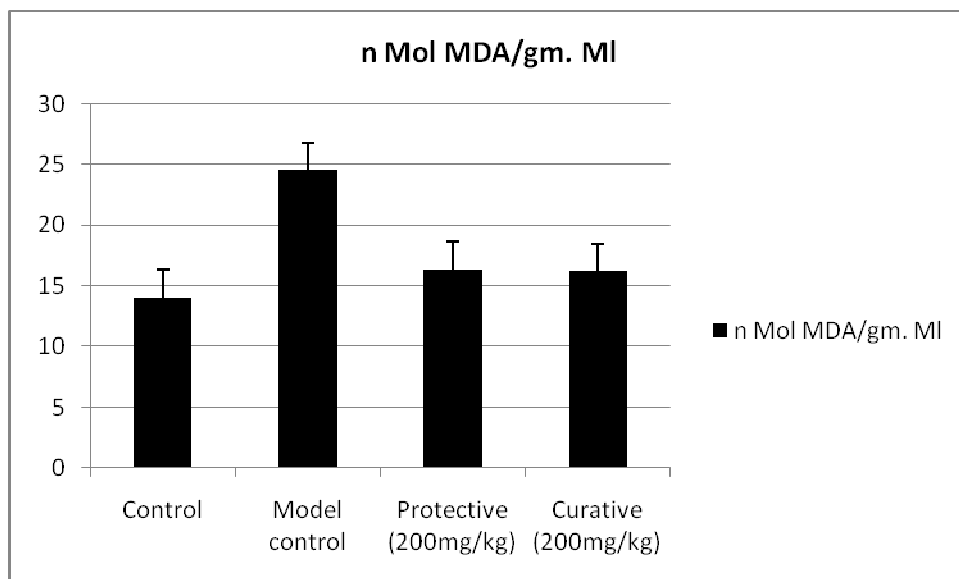


Figure 3. Effect methanolic extract of *Ficus religiosa* L latex on nMol MDA/gm content of kidney tissue of various groups. Each group represents mean± S.D. of six animals, **P<0.01, **P>0.01, **P>0.01, as compared to the Model Control.

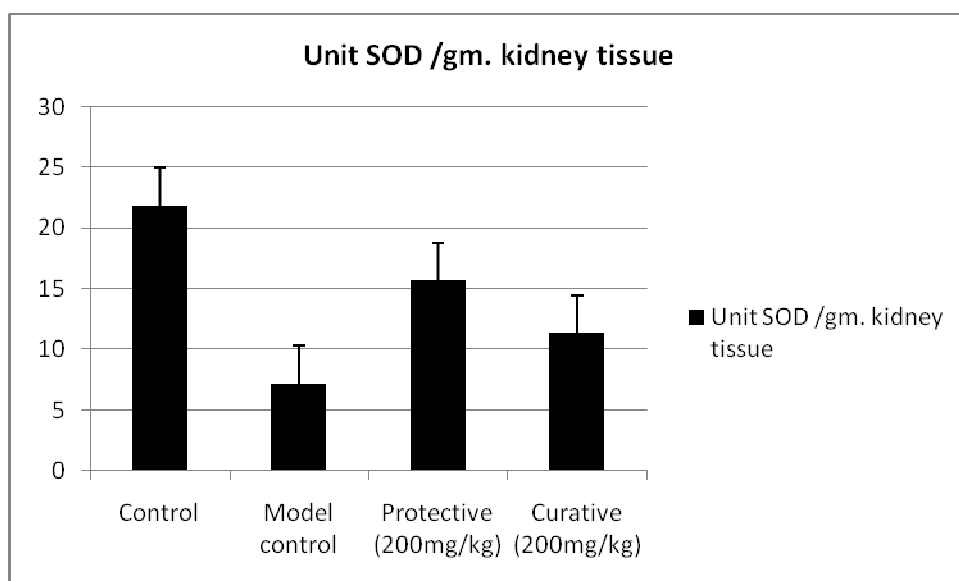


Figure 4. Effect methanolic extract of *Ficus religiosa* L latex on Unit SOD /gm. kidney tissue of various groups. Each group represents mean± S.D. of six animals, **P<0.01, **P>0.01, *P>0.05, as compared to the Model Control.

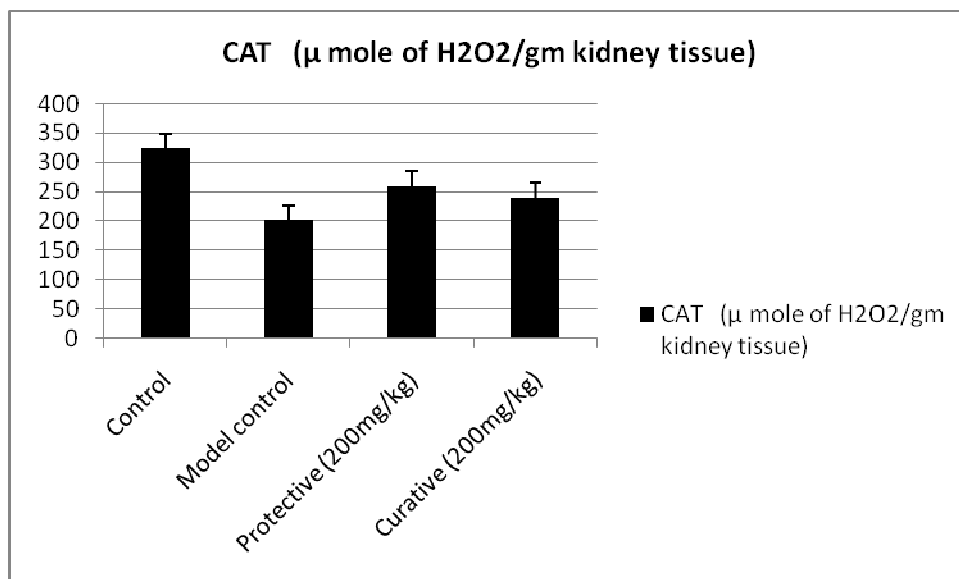


Figure 5. Effect methanolic extract of *Ficus religiosa* L latex on Unit CAT /gm. kidney tissue of various groups. Each group represents mean \pm S.D. of six animals, **P<0.01, **P>0.01, **P>0.01, as compared to the Model Control

Discussion

There are a large number of synthetic drugs induce nephrotoxicity and acute renal failure. The acute renal failure is reversible loss of renal functions. It may be recovered by herbal medicine. After injected the single dose of cisplatin (5mg/kg) causes increased urea (76.66 \pm 2.24) and creatinine (2.32 \pm 0.10) level in model control compare to respective control group (24.16 \pm 1.04 and 0.94 \pm 0.05) and its was recovered significantly (**P<0.01) in curative and protective groups with treatment of 200mg/kg same extract (Table no.1).

The change of renal function observed in the rat correlate well with the nephrotoxicity effect with man (21). The increased urea and creatinine level suggests the reduction of glomerular filtration rate (22). The present study was revealed that significantly decrease the level of urea and creatinine in blood serum after treatment of methanolic extract of *Ficus religiosa* L. latex that indicates increase glomerular filtration rate.

Jeong et al (23) observed that a single injection of cisplatin dose 5mg/kg body weight in rabbit caused a mark reduction of glomerular filtration rate, which is accompanied by increase in serum creatinine level indicating induction of acute renal failure. According to previous findings, we conformed that a single dose cisplatin induced a significantly serum creatinine in wistar rats three to seven days after administration (24, 35). The present study data had shown that significantly recovery of urea and creatinine serum level in curative and protective groups with treatment of both 200mg/kg same extract.

In kidney having some naturally occurring antioxidant enzyme like Superoxide dismutase (SOD), lipid peroxidase, catalase and glutathione (GSH), which protect kidney from free radicals, induce oxidative renal impairment. After single dose cisplatin administration, reduction of body weight and increase urinary volume it was recovered significantly (**P<0.01). Our present result data shown that significantly monitored GSH, SOD, and CAT and lipid peroxidation. This is indicate that extract have antioxidant potential whereas in phytochemical study of the extract have revealed the presence of Flavonoids, and amino

acids. The tannin (Phenolic compound), Flavonoids have antioxidant activity and amino acid were used to synthesis of the endogenous glutathione [26]. It's all may contribute synergistic reason to increase GSH level in kidney tissue significantly.

Conclusion

Finally it is concluded that the present study data conformed nephrotoxicity induced by cisplatin due oxidative stress and methanolic extract of *Ficus religiosa* L latex may have nephroprotective, curative and nephrocurative.

Acknowledgement

This investigation was supported by Dr. D.N. Srivastva and Dr. Vipin Saini help in technical assistance during study. Thanks to all for deep motivation and technical assistance.

References

- [1]. Bergstrom J, Furst P, Norée LO, Vinnars E. Intracellular free amino acid concentration in human muscle tissue. *J Appl Physiol*.1974; 36: 693–6.
- [2]. Bailey, L. H. and E. Z. Bailey. *Hortus*. 3rd ed. Macmillan General Reference, NY. 1976.
- [3] Neal, M.C.. *In Gardens of Hawai'i*. Bernice P. Bishop Museum Special Publication 40, Bishop Museum Press, Honolulu, HI; 1965.
- [4].Husain A, Virmani OP, Popli SP, Misra LN, Gupta MM, Srivastava GN, Abraham Z & Singh AK. Dictionary of Indian Medicinal Plants, CIMAP, Lucknow, India. 1992; 546
- [5]. Mousa O, Vuorela P, Kiviranta J, Wahab SA, Hiltohen R, Vuorela H Bioactivity of certain Egyptian *Ficus* species *J Ethnopharmacol*: 1994; 41:71- 6,
- [6]. Kirana H. ,SS Agarwal, Srinivasan B P., Aqueous extract of *Ficus religiosa* Linn reduce Oxidative stress in experimentally induced type 2 diabetic rats. *Indian Journal of Experimental biology*.2009; 47: pp 822-826,
- [7]. Zafar Iqbal, Qazi khalid Nadeem, M.N. Khan, M.S Akhtar and Faisal Nnouman Waraich In Vitro Anthelmintic Activity of *Allium sativum*, *Zingiber officinale*, *Curcubita mexicana* and *Ficus religiosa* *International journal of agriculture & biology*. 2001;3(4):454–457.2
- [8]. Preethi R., Vimal V. Devanathan and Loganathan M., Antimicrobial and Antioxidant Efficacy of Some Medicinal Plants against Food Borne Pathogens *Advances in Biological Research*.2010; 4 (2): 122-125.
- [9] Gonzalez Ricardo, Romay Cheyla, Borrego A, Merino FH, Zamora MZ, and Rojas E. Lipid peroxides and antioxidant enzyme in cisplatin induced chronic nephrotoxicity in rats. *Mediators Inflamm*. 2005; 3: 139-143.
- [10] Kersten L, Braunlich H, Kepper BK, Gliesing C, Wendelin M, Westphal J. Comparatively Antitumoral - active platinum and ruthenium complexes in rats. *J appl toxicol*.1998; 8(2): 245
- [11] Zhang JG, Lindup WE. Role of mitochondria in cisplatin - induced oxidative damage exl slices. *Biochem pharmacol*. 1993;45 (11): 677 – 683.
- [12] Kaplan A, Lavamen IS. The tests of renal function, in clinical chemistry. Interpretation and techniques 2nd ed., lea and Febiger, Philadelphia. 1983; 109-142.
- [13] Varley, and Alan HG. Tests in renal disease. In *Practical Clinical Biochemistry*. 1984; 1: 123.

- [14] Sedlak M, and Lindsay R. Estimation of total, protein-bound and non-protein sulfhydryl groups in tissue with Ellman's reagent. *Anal Biochem.* 1968; 25:192–205.
- [15] Hartree E. Determination of protein: a modification of long method that gives a linear photometric response. *Anal Biochem.* 1972;48: 4227.
- [16] Zager RA. A focus of tissue necrosis increase of renal susceptibility to gentamicin administration. *Kidney Int.*1998: 33: 84-90.
- [17] Didier Portilla, Richard TP, Safar AM. Cisplatin-induced nephrotoxicity Last literature review version. 2008;16.3.
- [18] Uchiyama M, Mihara M. Determination of malonaldehyde precursor in tissues by thiobarbuturic acid test. *Anal Biochem.* 1978; 86: 271–8.
- [19] Mishra HP, Fridovich I. The role superoxide anion in the auto-oxidation of epinephrine and a simple assay of SOD. *J Bio chem.* 1972; 247: 3170.
- [20] Sinha A. K. Colorimetric assay of catalase, *anal biochem.* 1972; 47:389.
- [21] Daugaard G, Abilgaard U, Holstein-Rathlou NH, Bruunshuus I, Bucher D, Leyssac PP. Renal tubular function in patients treated with high-dose cisplatin. *Clin Pharmacol Ther.* 1988; 44:164–72.
- [22] Naziroglu M, Karaoglu A, Aksoy AO. Selenium and higher dose vitamin E administration protects cisplatin induced oxidative damage of renal, liver, lens, tissue in rats. *Toxicolo.* 2004; 195: 221-239.
- [23]. Jeong JC, HwangWM, Yoon CH, Kim YK. *Salviae radix* prevent cisplatin induced acute renal failure, *nephro.* 2001; 88:241-6
- [24] Francescato HDC, Costa RS, Camargo SMR, Zanetti MA, Lavrador MA, Bianchi MLP. Effect of dietary oral selenium on cisplatin induced nephrotoxicity in rats. *Pharmacol Res.* 2001; 43:77–82.
- [25] Antunes LMG, Darin JDC, Bianchi MLP. Effects of the antioxidants curcumin or selenium on cisplatin-induced nephrotoxicity and lipid peroxidation in rats. *Pharmacol Res*2001; 43:145–50.
- [26] Nelson DL, and Michael M C. *Lehninger principle of biochemistry.* 2005; 4th edition; 857-858.