

## EVALUATION OF WOUND HEALING ACTIVITY OF *AEGLE MARMELOS* SEED

Ganesh N. Sharma\*, Susheel K. Dubey<sup>1</sup>, Nitin Sati<sup>2</sup>, Jyotsana Sanadya<sup>3</sup>

**\*Research Scholar:** Singhania University, Pachheri, Bari, Jhunjunu (Raj.)

<sup>1</sup>\*School of Pharmaceutical Sciences, Jaipur National University, Jaipur Raj., India-302025

<sup>2</sup>Dept. of Pharmaceutical Sciences, HNB Garhwal Central University, Srinagar, Uttarakhand, India

<sup>3</sup>Maharishi Arvind Institute of Pharmacy, Mansarovar, Jaipur, India

### Summary

The present study was aimed to evaluate wound healing activity of *Aegle marmelos* seeds. The ointment containing methanolic and aqueous extract, were prepared in white soft paraffin separately in concentrations of 5 % (w/w) and 10 % (w/w) and were incorporated in excision wound model and incision wound model in rats. Significant increase in percentage wound contraction, tensile strength and decrease in period of epithelialization was observed. Ointment containing methanolic extract shown significant ( $p < 0.01$ ) wound healing activity at the concentration of 5% and 10 % w/w/ in all animal model. The ointment containing aqueous extract was also found to possess significant ( $p < 0.05$ ) wound healing property at the same concentrations as of methanolic extract.

**Keywords:** *Aegle marmelos*, Wound, Excision, Incision

### Introduction

Wounds are physical injuries that result in an opening or break of the skin that causes disturbance in the normal skin anatomy and function <sup>[1]</sup>. They result in the loss of continuity of epithelium with or without the loss of underlying connective tissue. Unhealed wounds constantly produce inflammatory mediators that produce pain and swelling at the wound site. Wounds are a substrate for infection and prolong the recovery of injured patients <sup>[2]</sup>. Wound may be results due to the various physiological, mechanical and chemical factors. On physiological basis wound may be either acute <sup>[3]</sup> or chronic <sup>[4][5]</sup>.

The overall wound healing process can be divided into three continuous and overlapping processes, each one leading smoothly to the next and to a certain extent being dependent on one another; inflammatory phase <sup>[6]</sup>, Proliferative phase <sup>[7]</sup> and Remodelling phase <sup>[8][9]</sup>.

Medicinal plants have been used since time immemorial for treatment of various ailments of skin and dermatological disorders especially cuts, wounds and burns <sup>[10]</sup>.

Bael (*Aegle marmelos*, Linn.), family rutaceae, is also known as Bale fruit tree, is a moderate sized, slender, aromatic tree, 6.0 -7.5 m in height, and 90 to 120 cm in girth, with a somewhat fluted bole of 3.0-4.5 meter growing wild throughout the deciduous forests of India. It is indigenous to Indian sub continents and mainly found in tropical and subtropical regions <sup>[11]</sup>.

### Material and Methods

**Chemical Used:** All the chemicals and reagents used for the study were of analytical grade. Methanol (Merck, Germany), Betadine (Win medicare, containing 5 % w/w) was incorporated in study.

#### Collection and authentication of plant material:

The fresh, unripened fruits of *Aegle marmelos* were collected from healthy trees were growing at very hygiene and polluted free area in the month of may- June, located at various regions of Jaipur, Rajasthan. The seeds and plants were identified and authenticated from the department of Botany, University of Rajasthan, Jaipur, Rajasthan, and voucher specimen was deposited, viz no. RUBL: 20866.

#### Preparation of extract:

Freshly collected seeds of *Aegle marmelos* were dried at 30 °C and at 18.9 % relative humidity condition and milled with sieve to remove excess of mucilaginous hair. The plant extract was prepared using two different laboratory grade solvents (double distilled water & methanol);

- **Preparation of aqueous extract:** The dried powdered plant part (1.0 kg of *Aegle marmelos* seeds) was extracted with 4.0 liters of double distilled water for 72 hours in a round bottom flask, by placing on water bath, attaching reflux water condenser. After filtering and concentrating under vacuum the crude extract (reddish brown) was obtained.
- **Preparation of methanolic extract:** The powdered plant material (1.0 kg of *Aegle marmelos* seeds) was extracted with 4.0 liters of analytical grade methanol for 72 hours in a round bottom flask, on water bath attaching reflux water condenser. After filtering and concentrating under vacuum the crude extract (yellow reddish) was obtained.

The % yields of both the extracts (i.e. aqueous and methanol) were 19.71% and 10.84 %, respectively.

#### Assessment of wound healing activity:

**Animals:** The male wistar rats were (180-200 g) used for the study. They were housed in polypropylene cages and were left for seven days for acclimatization to animal room, was maintained under controlled condition of (12-14 hours light dark cycle, 25 ± 2 °C and relative humidity 45-55%), and were kept on standard pellet diet and water *ad libitum*. Before the study the animals were fasted overnight with the free access to water. The study protocol was approved by the Institutional Animal Ethical Committee (IAEC) of CPCSEA (Committee for the purpose of control and supervision of experiments on experiments on animals).

**Preparation of Ointment:** 5% w/w aqueous extract ointment was prepared by mixing 5g aqueous extract with white soft paraffin and weight was made upto 100 g, and triturated till

homogenization of mixture. Similarly, 10 % w/w aqueous extract ointment was prepared by mixing 10 g aqueous extract with white soft paraffin base, and weight was made upto 100g, followed trituration. Ointments of methanolic extract (5% and 10%) were prepared same as ointment for aqueous extract was prepared <sup>[12]</sup>.

**Grouping animals:** 36 rats were divided into six groups; each containing 6. Group I was treated with simple ointment base only and served as control, group II, IV were treated with 5 % ointment, and group III, V were treated with 10 % ointment, containing aqueous and methanolic extracts of *Aegle marmelos* seeds, sequentially. Group VI, was treated with Betadine ointment (Win medicare, containing 5 % w/w povidone iodine ointment). All the treatments were made topically.

**Excision wound model:** The particular skin area was shaved 1 day prior to the experiment <sup>[13]</sup>. The rats were anesthetized by administrating ketamine (0.5 ml /kg, b. w. I.P.). An impression was made on the dorsal thoracic region, 1 cm away from vertebral column and 5 cm away from ear, using a round seal of 2.5 cm diameter on the anesthetized rat. The skin of impressed area was excised with the help of forceps and sharp scissor in circular area (Approximately 500 mm<sup>2</sup>) and upto depth of 2mm, 30 minute later the administration of ketamine injection. Hemostasis was achieved by blotting the wound with cotton swab soaked in normal saline. The wounds were left undressed. The wounding day was considered as day 0. The wounds were treated topically with application of the ointments daily as mentioned above, till the wounds were completely healed <sup>[14]</sup>. The wounds were monitored and the area of wound was measured on 0, 4, 8, 12, 16, and 20 post wounding day. The wound healing effect was calculated (Taking the initial size of wound i.e. 500 mm<sup>2</sup> as 100 %) as follows;

$$\% \text{ Wound contraction} = \frac{\text{Initial wound size} - \text{Specific day wound size}}{\text{Initial wound size}} \times 100$$

The number of days required for falling scar without any residue raw wound gave period of epithelisation.

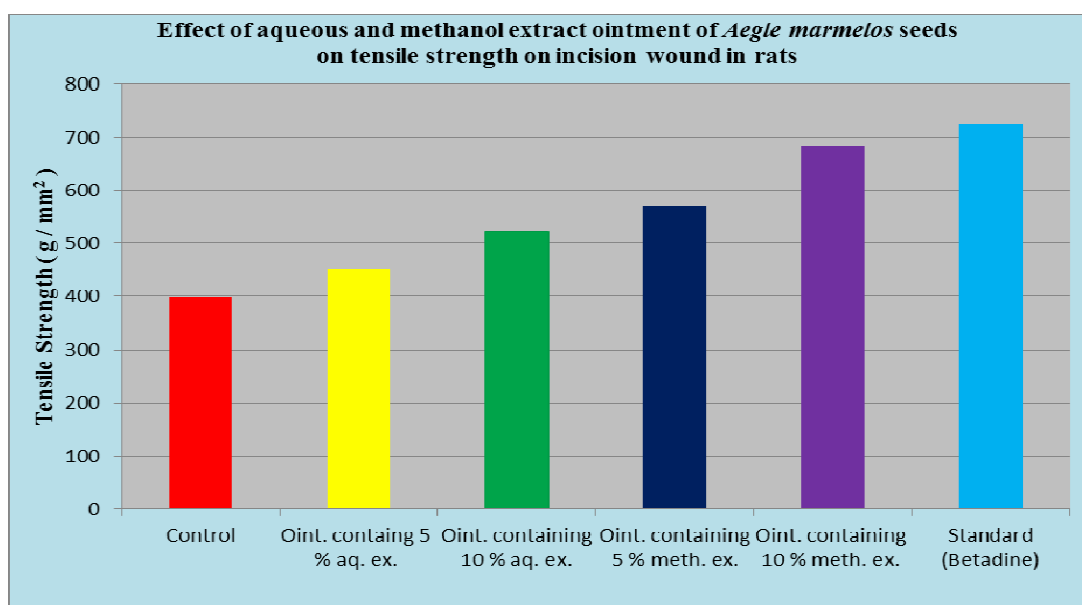
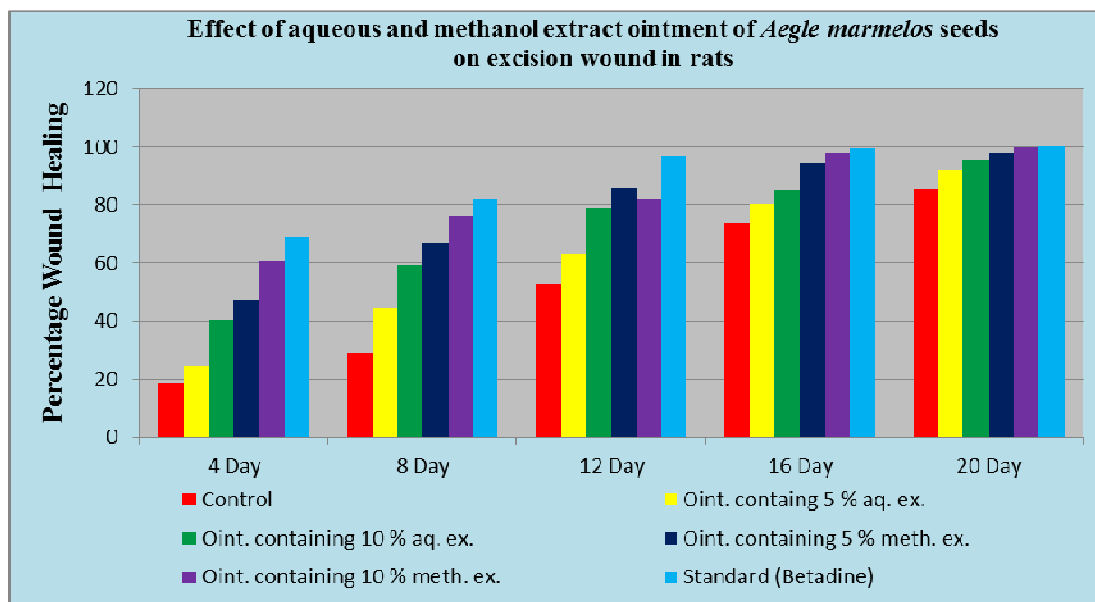
**Incision wound model:** The experiment was performed according to method described by *Ehrlich and Hunt* <sup>[15]</sup>. The particular area was shaved one day before the study. The animals were anesthetized by intra peritoneal administration of 0.5 ml / kg b.w. of ketamine. 30 min after the administration of ketamine, two long incision wounds (about 5 cm long and of 2 mm thickness) were created, through the skin at the distance of 1 cm from midline on each side of the depilated area of rat. After the incision was made the both edges of skin were kept together and stitched with black silk surgical thread (no. 000) and a curved needle (no. 11) at distance of 0.5 cm interval. The continuous threads on both wound edges were tightened for good closure of the wound. The wounds of animals in the different groups were treated with topical application of the ointments as mentioned above, daily for 10 days. The wounding day was considered as day 0. When wounds were cured thoroughly, the sutures were removed on the 9 th post wounding day, and the tensile strength of the skin i.e. weight in grams required to break or open the wound / skin was measured using tensiometer by the method of *Lee* <sup>[16]</sup>. Tensile strength was calculated using the formula <sup>[17]</sup>.

$$\text{Tensile strength} = \frac{\text{Breaking strength (g)}}{\text{Cross sectional area of skin (mm}^2\text{)}}$$

**Statistical Analysis:** Data are expressed as the mean ± standard error of mean (S.E.M.) and statistical analysis was carried out employing one way analysis of variance (ANOVA) followed by Dunnet test.

**Results**

The results of wound healing activity by excision wound model and incision wound model are presented in table 1 and 2.



**Table no.1:** Effect of aqueous and methanolic extract ointment of *Aegle marmelos* seeds on % wound contraction and period of epithelialization in excision wound model in rats

Group	Treatment (Daily) Topically	% Wound contraction (Days)						Period of Epithelialization, in days (Mean + S.E.M.)
		0	4	8	12	16	20	
Group I	Simple ointment base	523±3.24	427±3.84 (18.35)	371±4.23 (29.06)	248±4.92 (52.58)	138±2.94 (73.61)	77±2.62 (85.28)	26.65 ± 0.4831
Group II	5% Aqueous extract containing ointment	517±2.61	392±3.41* (24.18)	287±4.71* (44.49)	191±3.61* (63.06)	101±2.63* (80.46)	42±1.93* (91.88)	24.64 ± 0.2138*
Group III	10% Aqueous extract containing ointment	514±4.62	306±4.82* (40.47)	211±1.91* (58.95)	109±2.72* (78.79)	77±2.61* (85.02)	23±1.41* (95.52)	22.89± 0.5846*
Group IV	5% methanol extract containing ointment	507±2.84	268±3.12** (47.14)	167±4.51** (67.06)	72±1.62** (85.80)	28±1.83** (94.48)	11±1.32** (97.83)	21.72± 0.8942**
Group V	10% methanol extract containing ointment	511±3.13	202±2.91** (60.47)	123±3.24** (75.93)	92±3.93** (81.99)	11±1.63** (97.85)	02 ±0.6** (99.61)	20.83± 0.3941**
Group VI	Betadine Ointment	509±2.93	157±1.6** (69.15)	92±1.6** (81.92)	17±2.1** (96.67)	03±0.22** (99.41)	00±00** (100.00)	17.82± 0.5852**

- Values are given as Mean ± SEM for groups of six animals each.
- \*P<0.05 as compared to vehicle control
- \*\*P<0.01 as compared to vehicle control.

Table.2: Effect of aqueous and methanolic extract ointment of *Aegle marmelos* seeds on healing of incision wound

Group	Treatment (Daily) Topically	Tensile strength (g/mm <sup>2</sup> ) (Mean ± S.E.M)	% increase in tensile strength
Group I	Simple ointment base	398 ± 6.23	
Group II	5% Aqueous extract containing ointment	451 ± 5.84*	13.32
Group III	10% Aqueous extract containing ointment	523 ± 5.92*	31.41
Group IV	5% methanol extract containing ointment	571 ± 6.04**	43.46
Group V	10% methanol extract containing ointment	682 ± 4.93**	71.36
Group VI	Betadine Ointment	725 ± 5.63**	82.16

- Values are given as Mean ± SEM for groups of six animals each.
- \*P<0.05 as compared to vehicle control.
- \*\*P<0.01 as compared to vehicle control.

### Discussion

Wound healing or wound repair is the body's natural process of regenerating dermal and epidermal tissue. The process occurs in three phases; coagulation, inflammation, and repair including cellular proliferation and collagen deposition. Wound healing involves continuous cell-cell and cell-matrix interaction that allow the process to proceed in three overlapping phases; inflammation, cellular proliferation and remodelling.

In our present study, we analysed both methanolic and aqueous extract of *Aegle marmelos* seed for their wound healing activity. For this both the different extracts were formulated in ointment dosage form in 5 % and 10 % individual, and the standard betadine was used.

Data of table no.1 demonstrate that neutrophils migrates towards the fibrin clot speedily in group V and VI respectively being treated with ointment containing 10 % methanolic extract and standard betadine ointment, and both group showed 60.47 % and 69.15 % contraction of wound excised 4 day back, and from the end of 8<sup>th</sup> day of excision made on ointment containing 10 % aqueous extract, ointment containing 5 % methanolic extract and ointment containing 10 % methanolic extract in their respective groups III, VI and V had significantly produced 58.95 %, 67.06 % and 75.93 % contraction in wound made on 8 days before, because at this stage neutrophils would have being largely replaced by macrophages, and the data collected on 12<sup>th</sup> day of group I animals of this group did not treat any kind of aqueous or methanolic extract. Now this experiment proved that wound healing or wound repair is the body's natural process of regenerating dermal and epidermal tissue,

because on this day collected data 52.58 % contraction in wound made on 12 days back, and in group II, III, IV, V and VI the percentage wound contraction was observed 63.06, 78.79, 85.80, 81.99 and 96.67 respectively, because during this period granulation tissue progressively inhibits the incision space and the incisional space is filled with granulation tissue, collagen fibrils become more abundant and being to bridge the incision. After this period two data were also observed on 16<sup>th</sup> and 20<sup>th</sup> day of experiment with each groups, and observed that there was increase in wound contraction on every 4<sup>th</sup> day, till complete epithelialization is not reached.

The observations which have been giving an idea that ointment containing 10 % methanolic extract shorten the period of epithelialization, which was 20.83 days as shown in table no.1, and with the ointment containing 5 % methanolic extract, ointment containing 10 % aqueous extract, ointment containing 5 % aqueous extract and the ointment containing base only had shown the same effect after 21, 22, 24 and 26 days respectively, whereas ointment betadine had shown 17 days to initiate and complete all the phases of wound healing. Therefore, through the model “excision wound model in rats”, ointment containing methanol extract has shown results as clear as produced by standard betadine.

Through table 2 both the aqueous and methanol extracts were evaluated for their healing property of incised wound. On 10<sup>th</sup> day when tensile strength was observed to reopen the incised wound by applying weight in grams, and observing cross sectional area of reopened wound with the same applied weight, we can here quote our statement that the weight in grams needed to reopen the healed wound by minimum 1 mm<sup>2</sup> area.

The more tensile strength of the skin confirms continuous accumulation of collagen and proliferation of fibroblast. There is marked reduction in leucocyte infiltration and edema, which means that if more tensile strength is observed to reopened the healed wound than this is sign that this ruptured surface are firmly knitted by collagen.

In our study our observation from table 2 demonstrates that tensile strength required to reopen the healed wound is increased in order of group II, III, IV, V and VI, in compare to those animals placed in group I and were treated with simple ointment base only. The results are presented as mean weight required to break open the resutured wound were 725 g and 682 g in betadine ointment treated animals and ointment containing 10 % methanolic extract treated animals respectively. When compared with animals of group I, the tensile strength increased to 13.32, 31.41, 43.46, 71.36 and 82.16 in animals treated with ointment containing 5 % aqueous extract, 10 % aqueous extract, 5 % methanolic extract, 10 % methanolic extract of *Aegle marmelos* seed and betadine ointment respectively, Which means that during healing of wound following steps were involved like platelet aggregation and blood clotting, formation of fibrin, an inflammatory response to injury, alteration in the ground substances, angiogenesis and reepithelialisation.

Here through results we can infer that pronounced effects of various concentration of methanolic extract over various concentrations of aqueous extract may be due to presence of tannins, which is responsible for astringency and precipitation of DNA proteins, if any kind of microbial growth may suspect. In addition to this presence of quercetin like substances may also be responsible as it is well known fact that flavonoids are also responsible for lipid peroxidation, enhance the protective mechanism and their excellent antimicrobial activity.

Though the flavonoids are also responsible to maintain the immunity response against many tear and wear damaged bodily tissue, and normal functioning of living tissue.

Our approach to say that healing of excised and incised wound may be due to the high content of quercetin like substance is although correct, and if it deviates this property of extract containing be called due to the presence of tannins or their any kind of hydrolysed products.

### Acknowledgement

Authors are thankful to Dr. Ashish Sharma, Principal, Gyan Vihar School of Pharmacy, Suresh Gyan Vihar University, Jaipur (Raj.) of India for providing necessary support to carry out this study.

### References

1. Strodbeck, F, Physiology of wound healing. Newborn Infant Nurs. Rev. 2001; 1:43-52.
2. Roberts PR., Black KW, Santamauro JT and Zaloga GP, Dietary peptides improve wound healing following surgery. Nutrition 1998; 14: 266-269.
3. Lazarus GS, Cooper DM, Knighton DR, Margolis DJ, Pecoraro RE, Rodeheaver G. and Robson MC, Definitions and guidelines for assessment of wounds and evaluation of healing. Arch. Dermatol. 1994; 130:489-493.
4. Menke NB, Ward KR, Witten TM, Bonchev DG and Diegelmann RF, Impaired wound healing. Clin. Dermatol 2007; 25:19-25.
5. Krishnan P, The scientific study of herbal wound healing therapies: Current state of play. Curr. Anaesthesia Crit. Care 2006; 17:21-27.
6. Jie L, Juan C and Robert K, Pathophysiology of acute wound healing. Clin. Dermatol 2007; 25(1): 9-18.
7. Stadelmann WK, Digenis AG and Tobin GR, Physiology and healing dynamics of chronic cutaneous wounds. Am. J. Surg 1998; 176:26-38.
8. Madden JW and Peacock J, Studies on the biology of collagen during wound healing. I. Rate of collagen synthesis and deposition in cutaneous wounds of the rat. Surgery, 1968; 64:288-294.
9. Prockop DJ, Kivirikko KI, Tuderman L and Guzman NA, The biosynthesis of collagen and its disorders. N. Engl. J. Med.1979; 301:13-23.
10. Govindrajan R, Kumar B, Vijaykumar M and Pushpangadan P, Ethanopharmacological approaches to wound healing –exploring medicinal plants of India. J of Ethnopharmacology 2007; 114:103-113.
11. C.S.I.R., The wealth of India, National Institute of Science communication and Information Resources. 1985; I (A): 86.
12. Cooper and Gunn's, In: Carter S.L. (Ed.): Dispensing for pharmaceutical students.12<sup>th</sup> edition, CBS publisher and distributors, Delhi, 1987; 199-200.
13. Pawar RS, Shivhare Y and Singour PK, Wound healing potential of methanolic extract of *Trichosanthes dioica* Roxb (Fruits) in rats. J. of ethnopharmacology 2010; 127:614-619.
14. Pattanayak SP and Sunita P, Wound healing, anti-microbial and antioxidant potential of *Dendrophthoe falcate* (L.F.) ettingsh. J of ethnopharmacology, 2008; 120:241-247.
15. Ehrlich HP and Hunt TK, The effect of cortisone and anabolic steroids on the tensile strength of healing wounds. Annal Surgery 1968; 57:117.
16. Lee KH, Studies on the mechanism action of salicylates II, effect of vitamin A on wound healing retardation action of aspirin. J Pharmacol Sci, 1968; 57:1238-1240.
17. Diwan PV, Reddy BS, Reddy RKK, Naidu VGM, Madhusudana K, Agwane SB and Ramakrishna S, Evaluation of antimicrobial, antioxidant and wound healing potentials of *Holoptelea integrifolia*. J. of ethnopharmacology, 2008; 115:249-256.