

Hepatotoxicity of Cobalt Chloride in Albino Rat

Nidhi Mathur, G. C. Jain and Geeta Pandey

Center for Advanced Studies, Department of Zoology, University of Rajasthan, Jaipur-302004.

Corresponding author- Nidhi Mathur

Center for Advanced Studies, Department of Zoology,
University of Rajasthan, Jaipur-302004.

E-mail: nidhi.shikha@yahoo.co.in.

Tel.:+91-141-2369747

Summary

Cobalt is natural element found throughout the environment. Cobalt is an essential trace element being an integral part of vitamin B₁₂ but deficiency of cobalt has not been reported in humans. Cobalt has also been used as treatment for anemia because it stimulates RBC production. The present study was undertaken to study the hepatotoxic effect of cobalt chloride (CoCl₂.6H₂O) in male Wistar rats. Cobalt chloride (100 mg/kg b.wt/day) was administered orally in rats for 60 days. Administration of cobalt chloride caused a significant increase in the activity of hepatic marker enzymes like serum glutamate oxaloacetate transaminase (SGOT), serum glutamate pyruvate transaminase (SGPT), alkaline phosphatase and total bilirubin in serum. The level of serum total protein was also decreased. There was significant increase in the lipid peroxidation (TBARs) and decline in total glutathione, ascorbic acid, glycogen, protein and cholesterol in liver of treated rats as compared to control rats. The histopathological study indicates marked degenerative changes in the hepatocytes and infiltration of polymorphonuclear leucocytes. The results of this study indicate that subchronic treatment of cobalt chloride induces hepatotoxicity in rats.

Key words- Lipid peroxidation, SGOT, SGPT, Alkaline phosphatase, Total bilirubin

Introduction

Cobalt, a natural element present in certain ores of the earth's crust, is essential to life in trace amounts, but excess dietary cobalt causes toxic effects in mammals (1). Everyone is exposed to low levels of cobalt in air, water and food. There are few reports which has indicated that exposure to cobalt might cause adverse effects on the liver (2,3).

Occupational exposure to various cobalt compounds is of concern because of their mutagenic (4) and carcinogenic (5) effects. Polycythemia, goiter, cardiomyopathy, hyperglycemia, allergic dermatitis and respiratory impairment have been linked to chronic exposure to cobalt (6). Since cobalt and its salts are widely used in industry as components in paints, grinding wheels, hygrometers and electroplating, varnishes, in vitamin B₁₂, as a foam stabilizer in beer and as a catalyst in the petrochemical industry (7). Cobalt is also being used as a treatment of anemia and as illicit compound by athletes (8).

It has been reported that cobalt chloride produces oxygen-derived free radicals, which leads to a greater oxidative stress damage. Moreover, it has been demonstrated that cobalt salts activate the expression of several stress-responsive proteins, such as heme oxygenase. It is assumed that enhanced heme oxygenase activity may have important antioxidant significance by increasing the liver oxidative-stress defense capacity (9).

In a study Gonzales et al.,(10) observed cobalt chloride (375 $\mu\text{mol/kg}$ body weight, single injection) increase lipid peroxidation and decrease glutathione, SOD and catalase concentration in rat liver. In another study, it was shown that cobalt chloride produced hepatic and renal damage, characterized by increased activity of alanine and aspartate transaminases (GPT, GOT) and alkaline phosphatase. However lactate dehydrogenase activity (LDH) was decreased. In addition, serum urea, serum creatinine, serum total protein and serum bilirubin concentrations were significantly elevated (11).

The aim of the present work is to further investigate the effects of cobalt chloride on rat liver and its functions.

Materials and methods

Test chemicals

Cobalt chloride hexahydrate ($\text{CoCl}_2 \cdot 6\text{H}_2\text{O}$) was obtained from Merck, India Ltd., Mumbai, India.

Animals

Colony bred, adult male Wistar rats, weighing 170 - 210 g, were used in the present study. They were housed in well-ventilated cages and maintained under standard environmental conditions ($22 \pm 3^\circ\text{C}$, 60 - 70% relative humidity, 12 h dark/light cycle) and provided standard rat pellet feed (Lipton, India Pvt. Ltd.) and water *ad libitum*. The study was approved by Institutional ethical committee.

Experimental Protocol

The rats were randomly divided into 2 groups of 8 animals each.

Group A: Control rats received 0.5 ml/day of the vehicle (distilled water).

Group B: Rats treated with cobalt chloride ($100 \text{ mg}^{-1} \text{ kg}^{-1} \text{ day}^{-1}$) dissolved in distilled water.

All the rats received treatment for 60 days duration.

Autopsy

After 60 days of treatment, the overnight fasted animals were sacrificed under light ether anesthesia. Their body weights were recorded. Blood was collected by cardiac puncture. Serum was separated and stored at -20°C for biochemical estimations. Liver was excised immediately, cleaned in ice-cold normal saline, blotted and weighed on digital balance. Pieces of liver tissue were fixed in 10% buffered formaline for histopathological study. The remaining liver tissue samples were frozen at -70°C for biochemical analysis.

Biochemical parameters in serum

Serum samples were used for the estimation of the activities of serum glutamate oxaloacetate transaminase (SGOT) and serum glutamate pyruvate transaminase (SGPT) (12), alkaline phosphatases (ALP) (13) and levels of total bilirubin (14) and total protein (15).

Biochemical parameters in liver

Fresh/frozen liver samples were analyzed for glycogen (16), lipid peroxidation (TBARS) (17), glutathione (18) and ascorbic acid (19).

Statistical analysis

Data are expressed as mean \pm S.E.M. Student's *t* test was used for statistical comparison.

Results**Body and liver weight**

There was significant ($p \leq 0.001$) gain in the mean body weight of control rats when compared to their initial body weight. The rats receiving cobalt chloride treatment at 100 mg/kg b.wt/day dose also exhibited a slight significant ($p \leq 0.05$) increase in their body weight. There was a significant ($p \leq 0.001$) increase in the relative liver weight of cobalt chloride treated rats as compared to normal rats.

Table1. Changes in body weight of rats.

Body weight (gm)	Initial	Final
Group A	180 \pm 2.86	205 \pm 3.19 ^c
Group B	177.51 \pm 2.67	189.12 \pm 4.94 ^a

Data are expressed as Mean \pm SEM of 8 animals, Groups B was compared with Group A, ^aNon significant ($p \leq 0.05$), ^bSignificant ($p \leq 0.01$), ^cHighly significant ($p \leq 0.001$)

Biochemical parameters in serum

A significant increase in the activities of SGOT ($p \leq 0.001$), SGPT ($p \leq 0.001$) and ALP ($p \leq 0.001$) was observed in serum of cobalt chloride treated rats as compared to rats of normal group. Serum total bilirubin concentration also showed an elevation ($p \leq 0.001$) while the protein concentration declined significantly ($p \leq 0.01$).

Table2. Changes in relative liver weight and serum biochemical parameters in rats.

Treatment	Liver weight (mg/100 g b.wt)	SGOT (unit/ml)	SGPT (unit/ml)	ALP (KA units)	Total bilirubin (mg/dl)	Total protein (mg/dl)
Group A	3705.37±90.42	60.81±2.41	42.37±2.76	12.78±0.98	0.79±0.07	6.88±0.31
Group B	4193.52±131.27 ^b	138.04±6.98 ^c	131.54±6.00 ^c	27.23±1.26 ^c	1.75±0.18 ^c	5.65±0.28 ^b

Data are expressed as Mean±SEM of 8 animals, Groups B was compared with Group A, ^aNon significant ($p \leq 0.05$), ^bSignificant ($p \leq 0.01$), ^cHighly significant ($p \leq 0.001$)

Biochemical parameters in liver

Cobalt chloride treatment caused a significant rise ($p \leq 0.001$) in the lipid peroxidation (TBARS) with a concomitant decline in glutathione ($p \leq 0.001$), ascorbic acid ($p \leq 0.001$) and glycogen ($p \leq 0.01$).

Table3. Effect on hepatic glycogen, lipid peroxidation (TBARS), ascorbic acid and glutathione parameters of rats.

Treatment	Glycogen (mg/gm)	Lipid peroxidation (TBARS) (nmoles/mg tissue)	Ascorbic acid (mg/gm tissue)	Glutathione (μ moles/g tissue)
Group A	5.98±0.32	2.41±0.12	1.19±0.07	3.51±0.11
Group B	4.67±0.28 ^b	6.75±0.33 ^c	0.81±0.04 ^c	2.49±0.09 ^c

Data are expressed as Mean±SEM of 8 animals, Groups B was compared with Group A, ^aNon significant ($p \leq 0.05$), ^bSignificant ($p \leq 0.01$), ^cHighly significant ($p \leq 0.001$)

Histology

The sections of the liver of control rats showed normal histological features with the hepatic lobules showing irregular hexagonal boundary defined by portal tract and sparse collagenous tissues. The hepatic portal veins, bile ductules and hepatic artery within the portal tract were all visible. (Fig.1). Following exposure to cobalt chloride (Fig.2), the trabecular structure of the lobules was slightly or distinctly blurred. The cytoplasm of hepatocytes, contained empty vacuole-like spaces and were enlarged. Some sinusoids were overfilled with erythrocytes and the walls of most sinusoids showed numerous Kupffer cells.

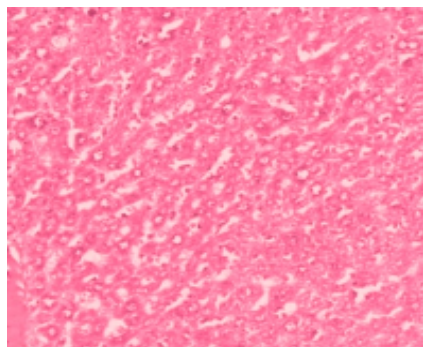
Figure

Figure 1-Group A: Control section of the liver (Mag. X100).

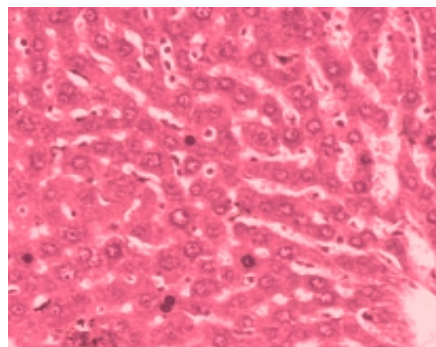


Figure 2-Group B: Treatment section of the liver, showing atrophic and degenerative changes (Mag. X100).

Discussion

It is well established that normal body weight gain is a sign of optimal health and efficient metabolic homeostasis (20,21,22). The control rats showed normal body weight gain throughout the dosing period. The body weight gain of the animal treated with cobalt chloride was markedly less in comparison to control. Cherroret *et al.* (23) suggested that the reduction in body weight of metal treated rats could be attributed to the decrease in food consumption and absorption or may be due to increase degeneration of lipids and proteins as a result of the direct effect of cobalt (24). Subchronic administration of cobalt chloride (100 mg/kg b.wt./day) for 60 days in rats caused a significant increase in the relative liver weight. A significant increase in the relative weight of liver observed in present study may be the first reaction of liver to the toxic agent. The liver accumulates cobalt to the greatest extent (25). Cobalt chloride caused a significant decrease in glycogen content of liver, which corroborates the findings of previous workers who have reported that insulin release was inhibited by cobalt (26). Assessment of liver function can be made by estimating the activities of marker parameters like SGOT, SGPT and ALP, which are originally present in higher concentration in cytoplasm. When there is hepatocellular damage these enzymes leak in the blood circulation (27). Elevated levels of these marker enzymes in serum of cobalt chloride treated rats correspond to extensive liver damage. Hyperbilirubinemia observed in cobalt chloride treated rats indicates impairment of glucuronyltransferase system leading to inhibition of bilirubin elimination (28). In the present investigation a significant increase in lipid peroxidation (TBARS) and a concomitant decline in liver glutathione (GSH) and ascorbic acid concentration, was observed in cobalt chloride treated rats. Similar enhancement in lipid peroxidation and decline in antioxidants defense system after cobalt chloride treatment in animals were observed by earlier workers (9). Thus, it is plausible to speculate that cobalt treatment may result in peroxidation of polyunsaturated fatty acids, leading to the degradation of phospholipids and ultimately result in cellular deterioration in the liver. Cytotoxic hydroxyl radicals may form when cobalt ions interact with ROS. Hydroxy radicals may then cause production of further free radicals which reduce cellular glutathione, ascorbic acid

concentration and NADPH activity. The resulting oxidative stress leads to DNA and cellular protein damage (29).

Cobalt chloride caused degenerative and necrotic changes in the histology and function of liver. Similar or more advanced changes in liver histology and function under cobalt influence have been reported by others (10). The cellular damage observed in this experiment may have been caused by the cytotoxic effect of cobalt on the liver. This obviously will affect the normal detoxification processes and other functions of the liver.

Acknowledgments

We are greatly indebted to Professor Reena Mathur for providing facilities. The authors are also thankful to the Center for Advanced Studies, Department of Zoology, University of Rajasthan, Jaipur. Ms. Nidhi Mathur is thankful to University Grants Commission, India for providing Research Fellowship.

References

1. Domingo J. Cobalt in the environment and its toxicological implications. *Rev Environ Contam Toxicol* 1989; 108: 105-132.
2. Bucher JR, Hailey JR, Roycroft JR, Haseman JK, Sills RC. Inhalation toxicity and carcinogenicity studies of cobalt sulfate. *Toxicol Sci* 1999; 49:56-67.
3. Mathur N, Pandey G, Jain GC. Male reproductive toxicity of some selected metals: A review. *Journal of Biological Sciences* 2010b; 10:396-404.
4. Hassan NHA, Fahmy MA, Farghaly AA, Hassan ES. Antimutagenic effect of selenium and vitamins against the genotoxicity induced by cobalt chloride in mice. *Cytologia* 2006; 71(3):213-222.
5. Bucher JR, Elwell MR, Thompson MB, Chou BJ, Renne R, Ragan HA. Inhalation toxicity studies of cobalt sulphate in F344/N rats and B6c3f1 mice. *Fund Applied Toxicol* 1990; 15:357-372.
6. Vengellur A, LaPres JJ. The role of hypoxia inducible factor 1alpha in cobalt chloride induced cell death in mouse embryonic fibroblasts. *Toxicol Sci* 2004; 82(2):638-646.
7. Neve J. The nutritional importance and pharmacologic effects of cobalt and vitamin B₁₂ in man. *J Pharm Belg* 1991; 46:271-280.
8. Lippi G, Montagnana M, Guidi GC. Albumin cobalt binding and ischemia modified albumin generation: An endogenous response to ischemia?. *Int J Cardiol* 2006; 108:410-411.
9. Christova TY, Duridanova DB, Setchenska MS. Enhanced heme oxygenase activity increases the antioxidant defense capacity of guinea pig liver upon acute cobalt chloride loading: comparison with rat liver. *Comp Biochem Physiol C Toxicol Pharmacol* 2002; 131(2):177-184.
10. Gonzales S, Polizio AH, Erario MA, Tomaro ML. Glutamine is highly effective in preventing in vivo cobalt-induced oxidative stress in rat liver. *World J Gastroenterol* 2005; 11(23):3533-3538.

11. Kechrid ZF, Dahdouh RM, Djabar N, Bouzerna N. Combined effect of water contamination with cobalt and nickel on metabolism of albino (Wistar) rats. *Iran J Environ Health Sci Eng* 2006; 3(1):65-69.
12. Reitman S, Frenkel AS. A calorimetric method for the determination of serum glutamic oxaloacetate and glutamic pyruvic transaminases. *Am J Clin Pathol* 1957; 28:56-63.
13. Kind PRN, King EJ. Estimation of plasma phosphatase by determination of hydrolysed phenol with antipyrine. *J Clin Pathol* 1954; 7:322-326.
14. Malloy HT, Evelyn KA. The determination of bilirubin with the photoelectric colorimeter. *J Biol Chem* 1937; 119:481-490.
15. Lowry OH, Rosenbrough MJ, Farr AL, Randall RJ. Protein measurement with the folin-phenol-reagent. *J Biol Chem* 1951; 193:256-275.
16. Montgomery R. Determination of glycogen. *Arch Biochem Biophys* 1957; 67:378-381.
17. Ohkawa H, Ohishi N, Yagi K. Assay for lipid peroxide formation in animal tissues by thiobarbituric acid reaction. *Anal Biochem* 1979; 95:351-358.
18. Moron MJ, Depieare JW, Mannivik B. Levels of glutathione reductase and glutathione transferase activities in rat lung and liver. *Biochem Biophys Acta* 1979; 582:67-68.
19. Roe JH, Kuether CA. Determination of ascorbic acid in whole blood and urine through the 2,4-DNPH derivative of dehydroascorbic acid. *J Biol Chem* 1943; 147:399-407.
20. Palou A. From nutrigenomics to personalised nutrition. *Genes Nutr* 2007; 2:5-7.
21. Mathur N, Jain GC, Pandey G. Effect of *Tecoma stans* leaves on the reproductive system of male albino rats. *Int J of Pharmacol* 2010a; 6(2):152-156.
22. Mathur N, Pandey G, Jain GC. Pesticides: A review of the male reproductive toxicity. *J Herbal Med Toxicol* 2010c; 4(1):1-8.
23. Cherroret G, Bemuzzi V, Desor D, Hutin MF, Burnel D, Lehr PR. Effects of postnatal aluminum exposure on choline acetyltransferase activity and learning-abilities in the rat. *Neurotoxicol Teratol* 1992; 14:259-264.
24. Galbraith RA, Kappas A. Regulation of food intake and body weight by cobalt porphyrins in animals. *Proc Nall Acad Sci USA* 1989; 86:7653-7657.
25. Ayala-Fierro F, Firriolo JM, Carter DE. Disposition, toxicity and intestinal absorption of cobaltous chloride in male Fischer 344 rats. *J Toxicol Environ Health Part A* 1999; 56:571-591.
26. Wollheim CB, Janjic D. Cobalt inhibition of insulin release: evidence for an action not related to Ca²⁺ uptake. *Am J Physiol* 1984; 246:57-62.
27. Jain GC, Pareek H, Khajja BS, Jain K, Jhalani S, Agarwal S, Sharma S. Modulation of di-(2-ethylhexyl) phthalate induced hepatic toxicity by *Apium graveolens* L. seeds extract in rats. *Afri J Biochem Res* 2009; 3(5):222-225.
28. Tkachenko AV. The effect of cobalt chloride on hemoxygenase activity, on bilirubin metabolic homeostasis in the brain and on serum albumin transport function in animals. *Eksp Klin Farmakol* 1995; 58(5):41-45.
29. Timbrell JA. Factors Affecting Metabolism and Disposition. In: *Principles of Biochemical Toxicology*. 2nd ed. London: Taylor and Francis, 1994; 125-191.