

EVALUATION OF HEPATOPROTECTIVE ACTIVITY OF AQUEOUS EXTRACT OF AZADIRACHTA INDICA (NEEM) LEAVES AGAINST PARACETAMOL INDUCED HEPATOTOXICITY IN ALBINO RATS.

Shivashankaramurthy K G and Kiran L J

Department of Pharmacology, J. M. Medical College Davangere, Karnataka, India

E-mail: drkiranlakkol@gmail.com, drkiranphar06@yahoo.com

E-mail: drkiranlakkol@gmail.com

Summary

The present study was conducted to evaluate the hepatoprotective activity of aqueous extract of *Azadirachta indica* and its comparison with Silymarin on paracetamol induced hepato-toxicity in albino rats. The aqueous extract of *Azadirachta indica* leaves (500mg/kg) was given orally to the animals with hepatotoxicity induced by paracetamol (2g/kg, single dose). Silymarin (100mg/kg) was given as reference standard. All the test drugs were administered orally by suspending in normal saline. The plant extract was effective in protecting the liver against the injury induced by paracetamol in rats. This was evident from significant reduction in serum enzymes alanine aminotransferase (ALT), aspartate aminotransferase (AST), bilirubin and significant rise in serum proteins. Histopathology of paracetamol treated group rat liver showed intense centrilobular necrosis, congestion of sinusoids with small lipid globules. Whereas in aqueous extract of *Azadirachta indica* leaves and Silymarin showed almost normal lobular architecture with mild centrilobular degeneration of hepatocytes without necrotic changes. It was concluded from the result that the aqueous extract of *Azadirachta indica* leaves possesses hepatoprotective activity against paracetamol induced hepatotoxicity in rats and it is less when compared to Silymarin as evidenced by the significant difference in biochemical parameters.

Key words: Hepatoprotective, Aqueous extract of *Azadirachta indica* leaves, Silymarin, Biochemical parameters, Histopathology.

Introduction

The liver supports many essential physiological processes including the production of albumin and plasma proteins, regulation of post absorptive glucose concentrations, lipid synthesis, endogenous and exogenous detoxification and other regulatory functions.^[1]

Hepatocyte injury is commonly encountered in the practice of medicine. The incidence of acute viral hepatitis has markedly decreased in the past decade due to the introduction of vaccines for hepatitis A and B. Other forms of acute hepatic injury have not changed appreciably in incidence, and recognition of chronic hepatic injury has increased. More than 400 million persons are chronically infected with HBV infection. The carrier rate in India is around 3-4% accounting for 30-40 million people with chronic HBV infection. Worldwide prevalence of HCV infection is 1% with marked geographical variation. HCV carrier state in India is around 1-2% accounting for 15 million people with chronic HCV infection^[2].

Hepatotoxic drugs can injure the hepatocyte directly via a free radical and metabolic intermediate that causes peroxidation of membrane lipids and that result in liver cell injury,^[3] such injuries may lead to necrosis of hepatocytes, cholestasis, inhibition of protein synthesis and fatty acid oxidation.

The liver disorders are a world problem. Despite its frequent occurrence of high morbidity and mortality, the medical management is currently inadequate, no therapy has successfully prevented the progression of hepatic diseases, even though newly developed drugs have been used to treat chronic liver disorders, these drugs have often side effects. Therefore this is an essential research about suitable herbal drugs that could replace the chemical ones. The plant extracts have been used by traditional medical practitioners for the treatment of liver disorders for centuries. Silybum marianum extracts were used as early as the 4th century B.C. for liver problems.^[4]

Plants like Picrorhizakurroa, Andrographis paniculata, Phyllanthus amarus, have been evaluated against carbon tetrachloride, paracetamol and alcohol induced liver damage. Azadirachta indica is one such plant used extensively in Ayurvedic practice as an anti-inflammatory, anti-malarial, anti-emetic etc.^[5] It needs to be evaluated experimentally for hepatoprotective effect in animal screening models. Thus the present study was conducted to evaluate the hepatoprotective activity of aqueous extract of Azadirachta indica and its comparison with Silymarin on paracetamol induced hepato-toxicity in albino rats.

Materials and methods

Animals : Animals used were albino rats, of Wister strain, weighing between 150-200gm of either sex. The animals were fed with standard laboratory food and water.

Equipments: Mouth gag, Polythene feeding tube and Syringes (2 ml).

Drugs:

1) Paracetamol: Tab Paracetamol 500mg **dissolved** in 2ml of 0.9% sodium chloride solution (normal saline) is used in this study. It produces a white coloured solution in water. It should be stored in a cool, dry and dark place. Protect from direct sunlight. It should be freshly made into solution for inducing in rats.

2) Sodium chloride: It is used to prepare normal saline in distilled water. Normal saline should be freshly prepared by adding 0.45gm of sodium chloride in 50ml of distilled water.

3) Silymarin: Tab. Silymarin 140mg dissolved in 7ml of 0.9% sodium chloride solution (normal saline) is used in this study. It produces brown coloured solution.

4) Aqueous extract of Azadirachta indica (neem) leaves:

Method of extraction: One kg of freshly collected, shade dried, powdered leaves of Azadirachta indica (neem) were ground in 4 liters of distilled water and allowed to soak overnight. The suspension was centrifuged at 5000 rpm for 20 min and filtered through a Whitman No. 1 filter paper. The supernatant fluid was allowed to evaporate in glass Petri dishes under tube light to provide heat and to prevent dampness so that no organism growth occurs. When completely dry, the powder was collected by scraping and was stored in cool, dry place. Protect from direct sun light. The ready extracted form was procured from Natural Remedies, Bangalore. The solution was prepared by adding 1gm of powder in 10ml of normal saline.

Albino rats of Wister strain with body weight of 150-200gm were used for this study. Animals were obtained from central animal house of Department of Pharmacology, J.J.M. Medical College, Davangere inbred and grown under suitable laboratory conditions. The present study was conducted in the department of Pharmacology J.J.M. Medical College, Davangere with the approval of institutional ethical committee.

Inclusion criteria:

- Body weight of 150-200gms
- Healthy with normal behavior and activity
- The rats were previously unused for any other experiment.

Exclusion criteria:

- Rats weighing more than 200gms and less than 150gms.
 - Pregnant female and those which have delivered once
- 24 albino rats of either sex weighing 150-200 gms were selected and randomly divided into 4 equal groups, each containing 6 rats.

Group I: Control

This group received normal saline (1ml/kg/day) for 7 days.

Group II: Hepato-toxic

In this group, acute hepatic injury was induced by oral administration of paracetamol at a single dose of 2gm/kg body weight on 5th day of experiment.

Group III: Test group

In this group, rats were received aqueous extract of Azadirachta indica (neem) leaves at dose of 500mg/kg/day orally for 7 consecutive days and same group was received paracetamol, orally at a single dose of 2gm/kg body weight on 5th day of extract administration.

Group IV: Standard

In this group, rats were received standard drug silymarin at dose of 100mg/kg/day orally for 7 consecutive days and same group was received paracetamol, orally at a single dose of 2gm/kg body weight on 5th day of drug administration.

After 48 hours of paracetamol administration or on 7th day of experiment, the animals were anaesthetized by using ether. Then blood was withdrawn directly from heart and serum was separated by centrifugation for study of biochemical parameters like,

- 1) Serum protein
- 2) Serum bilirubin
- 3) Aspartate aminotransferase (AST)
- 4) Alanine aminotransferase (ALT).

Then whole livers were removed after sacrificing the animal by decapitation and preserved in 10% formalin for Histopathological studies.

Statistical analysis:

Mean, standard deviations were calculated for each parameter in each group. One way Analysis of Variance (ANOVA) was used for multiple group comparisons followed by Post Hoc Dunnett's test for inter group comparisons of biochemical parameters. P values less than 0.05 were considered to be significant.

Results

Biochemical parameters: Rats in the control group were received normal saline 1ml/kg, and they showed mean values of serum AST, ALT, Bilirubin and Protein of about 34.7 IU/L, 44.6 IU/L, 0.68 mg/dl and 7.27 g/dl respectively. Administration of paracetamol 2g/kg, as a single dose to rats were showed a significant increase in mean values of serum AST, ALT and Bilirubin to 61.8 IU/L, 75.9 IU/L and 1.33 mg/dl respectively, and significant decrease in serum protein level to 5.92 g/dl when compared to control group.

Rats in the third group were received aqueous extract of neem leaves 500mg/kg and paracetamol 2g/kg, they showed significant decrease in mean values of serum AST, ALT and Bilirubin to 38.2 IU/L, 50.4 IU/L and 0.90 mg/dl respectively, and significant elevation of serum protein level to 6.90g/dl when compared to the group treated with paracetamol alone, although the serum transaminase and serum bilirubin levels still remained higher in this group as compared to control.

Rats in the fourth group were received silymarin 100mg/kg and paracetamol 2g/kg, they showed significant decrease in mean values of serum AST, ALT and Bilirubin to 34.8 IU/L, 45.1 IU/L and 0.70 mg/dl respectively, and significant elevation of serum protein level to 7.33g/dl when compared to the group treated with paracetamol alone, although the serum AST, ALT, Bilirubin and Protein levels were remained same as control group. When we compare the biochemical parameters of 3rd and 4th group rats, they showed significant difference (p value < 0.05) in serum levels. This concludes that rats pretreated with silymarin provide more hepatoprotective effect than rats pretreated with aqueous extract of azadirachta indica leaves.

Histopathological study: Gross examination of rat liver from control group showed normal appearance, red colour, smooth and regular under surface without any evidence of haemorrhage and necrosis. paracetamol treated liver showed multiple areas of necrosis and massive haemorrhagic patches. Most of the livers were covered with white slough and there were multiple white patches indicating necrotic areas. Liver weights were decreased in paracetamol treated group as compared to control group. Livers from aqueous extract of azadirachta indica leaves and silymarin groups were almost normal in appearance regarding colour and under surfaces and organ weight.

Histology of liver from control group showed portal triad, rows of hepatocytes or normal arrangements of hepatocytes with nuclei, while paracetamol treated liver sections showed abundant centrilobular necrosis (3rd and 2nd zone), bridging type of necrosis, cloudy swelling, pyknotic nuclei, loss of ribosome, cytoplasmic matrix swelling and eosinophilic cytoplasm. There were small lipid globules in surviving hepatocytes, congestion of central vein and sinusoids and gross hydropic vacuolation was prominent. Histology of liver sections from aqueous extract of azadirachta indica leaves + paracetamol treated rats revealed mild centrilobular hepatocytes degeneration with lymphocyte infiltration, few areas of congestion with mild fatty changes. Histology of liver section from silymarin + paracetamol treated rats showed marked decrease in inflammation, very scanty degeneration of hepatocytes without any necrotic changes, and mild fatty degeneration.

Table 1: Comparison of serum protein levels in different groups

Groups	Serum protein (g/dl)	Difference between groups **		
	Mean ±S.D	Groups compared	Mean difference	P-Value
1	7.27 ± 0.33	1-2	1.35	<0.001 HS
2	5.92 ± 0.25	1-3	0.37	0.19 NS
3	6.90 ± 0.14	1-4	0.06	0.99 NS
4	7.33 ± 0.55	2-3	0.98	<0.001 HS
		2-4	1.42	<0.001 HS
		3-4	0.43	<0.05 S

One way ANOVA F= 40.2, P <0.001, ** Post-hoc Dunnet’s test
 S-Significant, HS- Highly Significant, NS- Non Significant

Table 2: Comparison of serum bilirubin levels in different groups

Groups	Serum bilirubin (mg/dl)	Difference between groups **		
	Mean ±S.D	Groups compared	Mean difference	P-Value
1	0.68 ± 0.10	1-2	0.65	<0.01 S
2	1.33 ± 0.22	1-3	0.22	<0.05 S
3	0.90 ±0.09	1-4	0.02	1.00 NS
4	0.70 ±0.09	2-3	0.43	<0.05 S
		2-4	0.63	<0.05 S
		3-4	0.20	<0.05 S

One way ANOVA F= 30.4, P <0.001, ** Post-hoc Dunnet’s test
 S-Significant, HS- Highly Significant, NS- Non Significant

Table 3: Comparison of serum AST levels in different groups

Groups	Serum AST (IU/L)	Difference between groups **		
	Mean ±S.D	Groups compared	Mean difference	P-Value
1	34.7 ± 0.8	1-2	27.1	<0.001 HS
2	61.8 ± 2.7	1-3	3.5	<0.05 S
3	38.2 ± 1.3	1-4	0.1	1.00 NS
4	34.8 ± 1.9	2-3	23.6	<0.001 HS
		2-4	27.0	<0.001 HS
		3-4	3.4	<0.05 S

One way ANOVA F= 309.6, P <0.001, ** Post-hoc Dunnet’s test
 S-Significant, HS- Highly Significant, NS- Non Significant

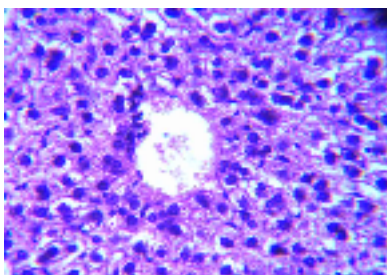
Table 4: Comparison of serum ALT levels in different groups

Groups	Serum ALT (IU/L)	Difference between groups **		
	Mean ±S.D	Groups compared	Mean difference	P-Value
1	44.6 ± 0.8	1-2	31.3	<0.001 HS
2	75.9 ± 5.1	1-3	5.8	<0.05 S
3	50.4 ± 2.7	1-4	0.5	0.87 NS
4	45.1 ± 0.9	2-3	25.5	<0.001 HS
		2-4	30.8	<0.001 HS
		3-4	5.3	<0.05 S

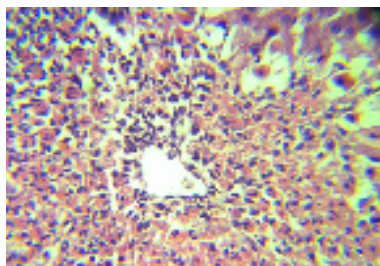
One way ANOVA F= 150.8, P <0.001, ** Post-hoc Dunnet's test
 S-Significant, HS- Highly Significant, NS- Non Significant

Figures showing histopathological findings of different groups

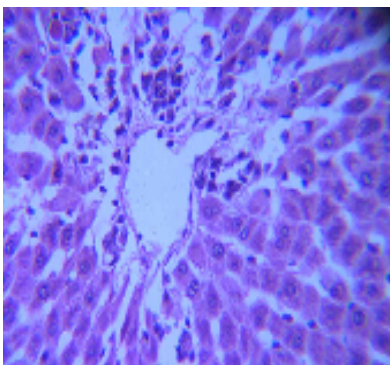
Group I: Control



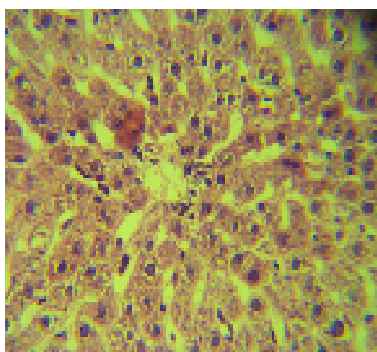
Group II: Hepato-toxic



Group III: Test



Group IV: Standard



Discussion

As the major drug metabolizing and detoxifying organ in the body, the liver is subject to potential damage from the pharmaceutical and environmental chemicals. Many of the widely used therapeutic drugs, including over the counter drugs can cause hepatic injury. Of the numerous remedies, medicinal agents, chemicals, and herbal remedies in existence, more than 600 are recognized as being capable of producing hepatic injury. ^[6]

Acetaminophen is the active metabolite of phenacetin, a so called coal tar analgesic. Acetaminophen has analgesic and antipyretic effects similar to those of aspirin. It has weak anti-inflammatory effects and has been thought to have a generally poor ability to inhibit COX in the presence of high concentrations of peroxides, as are found at sites of inflammation.

It is a weak COX-I and COX-II inhibitor in peripheral tissues. It may inhibit a third enzyme, COX-III in the central nervous system. COX-III appears to be a splice variant product of the COX-I gene.^[7] The most serious acute adverse effect of over dosage of acetaminophen is a potentially fatal hepatic necrosis. The mechanism by which over dosage with acetaminophen leads to hepatocellular injury and death involves its conversion to the toxic N-acetyl-p-benzoquinoneimine metabolite. This is eliminated rapidly by conjugation with glutathione and then further metabolizes to a mercapturic acid and excreted into the urine. In the setting of acetaminophen overdose, hepatocellular levels of glutathione become depleted. Depletion of intracellular glutathione renders the hepatocytes highly susceptible to oxidative stress and apoptosis.

In the previous study done by B. P. Kale and coworkers, it was observed that hepatoprotective effect of aqueous extract of *Azadirachta indica* leaves on hepatotoxicity induced by antitubercular drugs in rats. They concluded that aqueous extract of *Azadirachta indica* significantly prevents and reverses the hepatotoxic damage induced by antitubercular drugs in rats.^[8]

This study was undertaken to find the effectiveness of aqueous extract of *Azadirachta indica* leaves on hepatotoxicity induced by paracetamol, and its comparison with known, widely used hepatoprotective drug silymarin. As can be seen from results, the test product aqueous extract of *Azadirachta indica* leaves provides good hepatoprotective effect on paracetamol induced hepatic injury. But on the basis of biochemical parameters and histopathology study, the aqueous extract of *Azadirachta indica* leaves provides significantly ($p < 0.05$) less hepatoprotective effect when compared to silymarin.

Results of histological studies showed a marked reduction in the congestion of sinusoids and cloudy swelling in liver sections of pretreated aqueous extract of *Azadirachta indica* leaves group rats and silymarin group rats as compared to rats treated with paracetamol alone. This indicates that aqueous extract of *Azadirachta indica* leaves and silymarin possesses some anti-inflammatory properties which may contribute to its hepatoprotective effects since cloudy swelling and sinusoidal congestion are prominent features of paracetamol hepatotoxicity.^[9, 10]

The highly significant ($p < 0.001$) reduction in the levels of serum AST, ALT, and Bilirubin and significant increase in serum protein levels in rats treated with aqueous extract of *Azadirachta indica* leaves + paracetamol and silymarin + paracetamol as compared to paracetamol alone, also indicates that aqueous extract of *Azadirachta indica* leaves and silymarin affects important biochemical reactions

which may be beneficial in reducing hepatic damage. The hypolipidaemic effect^[11] of neem leaf extract may be beneficial in reducing paracetamol induced hepatotoxicity, since fatty changes have been reported in paracetamol induced hepatic damage.

The anti-lipoperoxidative property of aqueous extract of *Azadirachta indica* leaves and silymarin may also be contributing towards their hepatoprotective property, since they have been shown to be rich in flavonoid contents^[12] and flavonoids are well known antioxidants.^[13]

Depletion of intracellular glutathione renders the hepatocytes highly susceptible to oxidative stress and apoptosis. This depletion of glutathione is caused by paracetamol overdose.^[14] In this study, aqueous extract of *Azadirachta indica* leaves and Silymarin reverse the hepatic injury, which is caused by paracetamol due to oxidative stress and apoptosis. The possible mechanism of hepatoprotective effect of aqueous extract of *Azadirachta indica* leaves and Silymarin may be due to anti-oxidant and anti-apoptotic properties.

Conclusion

- Aqueous extract of *Azadirachta indica* leaves provides hepatoprotective effect on paracetamol induced hepatotoxicity in rats, as evidenced by significant difference in biochemical parameters and histopathological study.
- The efficacy of hepatoprotective effect of aqueous extract of *Azadirachta indica* leaves is less when compared to silymarin, as evidenced by significant difference in biochemical parameters.
- According to the histopathological features, I can conclude that both silymarin and aqueous extract of *Azadirachta indica* leaves produce equal effect of hepatoprotection on paracetamol induced hepatotoxicity.
- Further studies are required to elucidate exact molecular and biochemical mechanisms involved and to establish its therapeutic role as a hepatoprotective agent.

Acknowledgements

We are very much thankful to Dr. H.S. Siddappa Devaru, Professor and Head, Department of Pharmacology, J.J.M.M.C. Davangere, and Dr. N. Suryanarayana Babushaw, Professor, Department of Pharmacology, J.J.M.M.C. Davangere, for their kind co-operation and help.

References

1. Kamal GI, Rodney SM. Liver. Anderson's Pathology. 10th ed. 1996; 2: 1781.
2. Deepak A. Viral hepatitis B& C. API Text book of Medicine. 8th ed.,p 683-687.
3. Jules LD, Kurt JI. Toxic and Drug induced hepatitis. Harrison's principles of Internal Medicine. Mc Graw-Hill. 17th ed. 2008; 2:1949-1955.
4. Madani H, Talebolhosseini M, Asgray S, Naderi GH. Hepatoprotective activity of Silybum marianum and Cichorium intybus against Thioacetamide in rats. Pakistan Journal of Nutrition. 2008; 7: 172-176.
5. Biswas K, Chattopadhyay I, Ranajit KB, Uday B. Biological activities and medicinal properties of Neem (Azadirachta indica). Current Science 2002; 82 (suppl.11):1336-1345.
6. Porth CM. Disorders of Hepatobiliary and Exocrine Pancreas Function: pathophysiology. Concepts of altered health status. Lippincott Williams & wilkins. 7th ed. 2005. p. 925-926.
7. Zimmerman HJ, Acetaminophen hepatotoxicity: Clinical liver disease. Philadelphia, Lippincott Williams & Wilkins. 2nd ed. 1998. p. 523-541.
8. Kale BP, Kothekar MA, Tayade HP, Jaju JB, Mateenuddin M. Effect of aqueous extract of Azadirachta indica leaves on hepatotoxicity induced by antitubercular drugs in rats. Ind J Pharmacol. 2003; 35: 177-180
9. Chattopadhyay RR, Chattopadhyaya RN, Maitra SK. Possible mechanism of anti-inflammatory activity of Azadirachta indica leaf extract. Indian J Pharmacol. 1997; 27: 99-100.
10. Saller R, Meier R, Brignoli R. The use of Silymarin in the treatment of liver diseases. Drugs. 2001; 61: 2035-2063.
11. Bopanna KN, Kannan J, Gadgil S, Balaraman R, Rathod SP. Antidiabetic and antihyperlipaemic effects of of neem seeds Kernal powder on alloxan diabetic rabbits. Indian J pharmacol. 1997; 29(3):162-167.
12. Khan M, Schneider B Wassilew SW, Splanemann V. Experimental study of the effect of raw materials of the neem tree and neem extract on dermatophytes, yeasts and moulds. Z-Hautkr. 1988; 63(6): 499-502.
13. Cavallini L, Bindoli A, Siliprandi N. Comparative evaluation of antiperoxidative action of silymarin and other flavonoids. Pharmacol Res Commun. 1978; 10: 133-136.
14. Daniel E, Furst, Robert WU. Nonsteroidal Anti-inflammatory Drugs, disease modifying anti-rheumatic drugs, Non opioid analgesics, and Drugs used in Gout. In Katzung BG: Basic and clinical pharmacology. Mc Graw-Hill. 10th ed. 2007. p.591-592.