

**CHEST X-RAY:**

**OFF LABEL USE IN BREAST IMPLANT EVALUATION**

Di Grezia G<sup>1</sup>, Polizzi I<sup>2</sup>, Musto L<sup>1</sup>, Gatta G<sup>2</sup>

<sup>1</sup> Radiology Department, “G Criscuoli” Hospital, ASI AV It

<sup>2</sup> Radiology Department, University of Campania “Luigi Vanvitelli” Naples, IT

[graziella.digrezia@unicampania.it](mailto:graziella.digrezia@unicampania.it)

**Abstract**

We describe a case of a very old patient with breast implants detected during a chest radiograph. The patient underwent a bilateral mastectomy for a multifocal lobular cancer diagnosed at the age of 64yo and a subsequently subglandular breast implant surgery. A conventional thorax radiography after 25 years identifies in this case the presence of breast implants thanks to wall calcifications. An off label use of chest x-ray allows to evaluate the presence, the localization and some information of breast implants, especially in old patients.

**Keywords:** *breast implant, chest radiography, incidentaloma.*

## Introduction

Chest radiograph is a widely available, cheap and easy to perform modality and represents the first imaging technique in respiratory, cardiovascular and systemic diseases.

First, it can reduce the lung cancer mortality with low rate of false positive results [1,2] and can be useful in the prognosis assessment of critically ill patients also in the evaluation of position of various tubes, lines, and other devices [3]

**Correctness criteria** include adequate inspiration, that can be confirmed by the visibility of ten ribs in the mid clavicular line on PA chest radiography; a poor inspiration can determine an erroneous cardiac failure diagnosis; furthermore there should not be rotation to avoid increased transradiancy, especially in supine position [4]

The most frequent diagnosis are cardiac failure, lobar consolidation, pneumothorax, pleural effusion, lines and tubes [5]; however, incidentaloma may occur during the examination. Usually, not only pulmonary nodules or ectopic thyroid gland can be detected but also medical devices or implants and their status can be evaluated.

We describe a case of a very old patient with breast implants detected during a chest radiograph.

## Case Report

CF, 89 yo, went to our Institution to perform a chest radiograph.

*Anamnesis:* Bilateral mastectomy and breast reconstruction 25 years before

*Symptoms:* Caught since two months before and pain referred to right breast.

*Clinical examination:* obtuseness of sound on percussion in inner right lung.

*X-ray:*

Clear both lung fields

Clear costophrenic angles.

Normal cardiac size and shape

Aortic atheromatosis

**Additional finding:** breast implants with calcified wall and irregular thickness in upper outer quadrant.

**BREAST ULTRASONOGRAPHY:** confirmed, in the upper outer quadrant of right breast, the presence of stepladder sign with an intact fibrous capsule and without silicone extravasation.

## Discussion

The patient underwent a bilateral mastectomy for a multifocal lobular cancer diagnosed at the age of 64yo and a subsequently subglandular breast implant surgery [6]

This intervention could be associated to a higher risk of complications if compared with autologous that can determine better results with minor hazard [7,8]

Even if the age is not a contraindication to breast implants, the comorbidity and the frailty of old patients, preference should be given to microsurgery reconstruction that has also better long-term follow-up [9].

In a patient with bilateral breast prostheses, breast MRI is recommended to evaluate complication or to detect postsurgical cancer [10]

However, many contraindication can occur in old patient for the execution of breast MRI, first of all the claustrophobia; for this reason often the patients refuse imaging and oncologic and prosthesis evaluation is missing.

A conventional thorax radiography can identify only in some cases the presence of breast implants and in very old patient the also the wall can be evaluated, thanks to calcification.

Profile irregularity can be identify and breast ultrasonography can help in the diagnosis also in patients that cannot undergo a breast MRI.

Management of intracapsular rupture of breast implant in this old patient is of short term follow-up and no surgery has been planned.

## References

- 1 Gossner Lung cancer screening-don't forget the chest radiograph World J Rad 2014; 6(4):116-118
- 2 Sagawa M et al. The efficacy of lung cancer screening conducted in 1990s: four case-control studies in Japan Lung Cancer 2003;41:29-36
- 3 Hill JR, Horner PE, Primack SL. ICU imaging. Clin Chest Med. 2008;29:59-76
- 4 ACR-AAPM-SIIM PRACTICE PARAMETER FOR DIGITAL RADIOGRAPHY 2014 [https://www.acr.org/-/media/ACR/Documents/PGT/S/guidelines/Digital\\_Radiography.pdf](https://www.acr.org/-/media/ACR/Documents/PGT/S/guidelines/Digital_Radiography.pdf)
- 5 Rounds G The Chest Radiograph Ulster Med J 2012;81(3):143-148
- 6 Gatta G, Pinto A, Romano S et al Clinical, mammographic and ultrasonographic features of blunt breast trauma Eur J Rad 2006 Sep;59(3):327-30
- 7 Laporta R et al Breast reconstruction in elderly patients: risk factors, clinical outcomes and

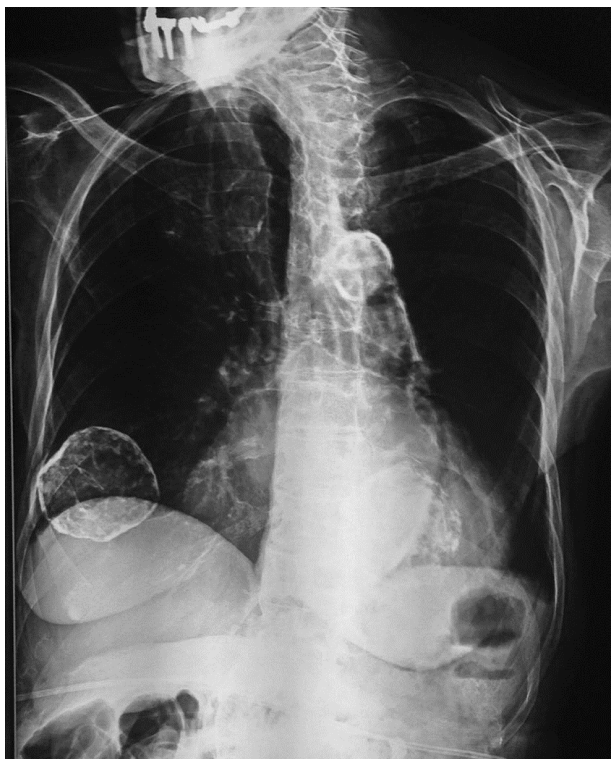
---

aesthetic results *Reconstr Microsurg* 2017 Jan 6  
doi: 10.1055/s-0036-1597822

8 Di Grezia G et al. Breast ultrasound in the management of gynecomastia in Peutz-Jeghers syndrome in monozygotic twins: Two case reports *J Medical case reports* 2014,8;440

9 Hamnett KE et al. Breast reconstruction in older patients: a literature review of the decision-making process *J Plast Reconstr Aesthet Surg* 2016 Oct;69(10):1325-34

10 Margolis NE, Morley C, Lotfi P, Shaylor SD, Palestrant S, Moy L, Melsaether AN. Update on imaging of the postsurgical breast. *Radiographics*. 2014 May-Jun;34(3):642-60. doi: 10.1148/rg.3431350



**Fig 1** Chest x-rays; CF, 89yo – the figure shows breast implants in good position with calcified wall and irregular thickness in upper outer quadrant