

VISUALIZATION OF THE CLINICAL OBSERVATIONS IN THE DIFFERENT STAGES OF THE DENTAL PROSTHETIC TREATMENT PROCESS

Brizdana Hadjieva¹, Mariana Dimova²

1. Department of Prosthodontics, Faculty of Dental Medicine, Medical University, Sofia, Bulgaria
2. Department of Prosthodontics, Faculty of Dental Medicine, Medical University, Sofia, Bulgaria

Summary

In the treatment process the documentation of the information of the observations makes a ground on which the treatment plan is built, conclusions and prognosis are made, a card index is made and data bases are created too. To this effect the detailed photo documentation and casts documentation, following the continuity of the treatment procedures has an important meaning in diagnostics and prognostics and serves also as a proof and demonstrative materials.

A method for consecutive visualization of the clinical findings in the different stages of the treatment process with the help of photo documentation and situational casts models is suggested.

Examples are suggested, using patients from the clinical exercises of the students in the fifth form from the Faculty of Dental Medicine-Sofia.

The collecting of such a data bases demands an extra time but it contributes to create a clinical thinking, enhances the abilities of finding the characteristics and changes during the observational appointment, betters the diagnostic process and building up of the different treatment variances.

Key words: photo documentation, casts documentation, dental prosthetic treatment

Address for correspondence:

Assist. Prof. Brizdana Hadjieva
Faculty of dental medicine
Department of Prosthetic Dentistry
1.St. G. Sofiiski Blvd., 1431 Sofia
E-mail: [hrishadj@abv.bg](mailto:hkishadj@abv.bg)

Introduction

Since three years in the Faculty of Dental Medicine in the Medical University of Sofia has been practicing the method of integrated education of the dental students in the two semesters of the fifth form. At the end of the second semester the students have to present two or three clinical cases in which he had used his abilities in all disciplines - periodontology, cariesology or endodontics and prosthodontics (1, 3). The estimation of the treatment plan and the treatment results of it are made by the professors from the departments of the above mentioned disciplines. To optimize the educational and treatment process of the students the authors suggest an approach for documentation, systematization and visualization of the treatment phases.

Materials and methods

For this purpose a written statement for photo documentation of the patients is submitted, except the radiographic examination and the situation models from the beginning and the end of the treatment should accompany all the patients' clinical records.

A). The protocol for photo documentation by fixed prosthetic treatment includes:

I. Photo documentation of the first clinical appointment.

1. Extra oral picture-formal smile (2).
2. Intraoral pictures of the prosthetic area of upper and lower jaws.
3. Additional pictures if special characteristic or peculiarities of the prosthetic area exist.
4. Intraoral pictures of central occlusion- in full face and in side view.
5. Picture of the panoramic rhoentgenography.

II. Photo documentation after finishing the preprosthetic preparation phase.

1. Intraoral pictures of the prosthetic area of upper and lower jaws.
2. Intraoral pictures of central occlusion- in full face and in side view (when leveling of the occlusal plane is achieved).

III. Photo documentation of the real prosthetic treatment.






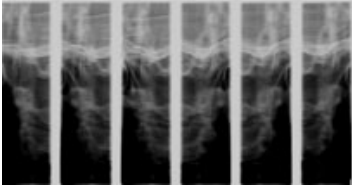




1. Intraoral pictures with the temporary prosthetic constructions.
2. Intraoral pictures with the final prosthetic constructions.
3. Intraoral pictures of central occlusion- in full face and in side view.

B). The protocol for photo documentation of prosthetic treatment by partially edentulous patients includes:

1. Extra oral pictures at the first clinical appointment.
2. Intra oral pictures of the prosthetic site - of upper and lower jaw.
3. Focusing on the characteristics of the prosthetic area and the surrounding soft oral tissues.
4. Pictures of the situation models of both jaws.
5. Pictures of the old dentures (if such exist).
6. Picture of panoramic rhongenography.
7. Picture of the prosthetic construction on the working models (if possible).
8. Pictures of the new prostheses.
9. Intraoral pictures of the new prosthetic treatment - on upper jaw, on lower jaw, in central occlusion in full face and in side view-left and right.
10. Extra oral picture with the new prostheses - smile.

C). The protocol of the cast models consists of three main parts connected with fixed, removable and combined prosthodontics:

1. Gathers of casts by fixed prosthodontics.
 - Situation casts from the first clinical appointment
 - Situation casts with diagnostic ascendant wax modeling (in cases when needed)
 - Situation casts from the fixed provisional prostheses in the mouth.
 - Laboratory casts for making the final prosthetic constructions.
 - Situation casts from the fixed final prostheses.
2. Gathers of casts by combined prosthodontics.
 - Situation casts from the first clinical appointment
 - Situation casts after the preprosthetic preparation of the treated area.
 - Situation casts from the fixed prostheses in the mouth.
 - Situation casts of the final combined treatment in the mouth.
3. Gathers of casts by removable prosthodontics.
 - Situation casts from the first clinical appointment.
 - Situation casts after the preprosthetic preparation of the treated area.
 - Situation casts of the final removable treatment.

Photo documentation at the first clinical appointment:			
<i>Patient 1:</i>			
		<i>Fig.1.Extra oral picture –formal smile</i>	
			
<i>Fig.2. Intra oral picture of central occlusion-full face</i>	<i>Fig.3. Intra oral picture of the prosthetic site of upper jaw.</i>	<i>Fig.4. Intra oral picture of the prosthetic site of lower jaw.</i>	<i>Fig.5. Prosthetic constructions with short margins of the crowns.</i>
			
<i>Fig.6. Rhoentgenographic examination of TMJ-sagittal projections P6</i>		<i>Fig. 7: Panoramic rhoentgenography</i>	
<i>Patient 2:</i>			
			
<i>Fig.8. Intra oral picture of central occlusion-full face.</i>	<i>Fig.9. Intra oral picture of central occlusion-side-view. Godon's phenomenon.</i>	<i>Fig.10. Focusing on prosthetic site characteristics-poor oral hygiene, dental plaque and calculus.</i>	
<i>Patient 3.</i>			





















		
<i>Fig. 11. Intra oral picture of central occlusion – the prosthetic treatment didn't restore the occlusal plane.</i>	<i>Fig. 12. Intra oral picture at 2 cm open mouth –the prosthetic treatment didn't restore the occlusal plane and the articulation interrelations.</i>	
Patient 4:		
		
<i>Fig. 13. Intra oral picture of central occlusion-full face.</i>	<i>Fig. 14. Intra oral picture of central occlusion -right side-view</i>	<i>Fig. 15. Intra oral picture of central occlusion -left side-view</i>
Focusing on prosthetic site and surrounding soft tissues' characteristics:		
		
<i>Fig. 16: Incorrect planning and poor laboratory realization of a bridge accompanied with poor oral hygiene.</i>	<i>Fig. 17: Incorrect planning and poor laboratory realization of a bridge – 37 is not included in the construction, missing occlusal relief, poor oral hygiene.</i>	<i>Fig. 18: Allergic reaction to Ni containing alloy – proliferating changes of the gingival margin and lichenoid reaction of the mucosa.</i>

Photo documentation during the prosthetic treatment:*		
		
<i>Fig. 19: Intra oral picture before preparation for crowns of upper frontal teeth</i>	<i>Fig. 20: Intra oral picture two days after the fixing of the provisional crowns of upper frontal teeth.</i>	<i>Fig. 21: Intra oral picture after the fixing of the final construction of upper frontal teeth.</i>
		
<i>Fig. 22: Intra oral picture of upper jaw with the final prosthetic construction.</i>	<i>Fig. 23: Intra oral picture of lower jaw with the final prosthetic construction.</i>	

*Pictures 19-23 are from the clinical private practice of Assoc. Prof. M. Dimova

Photo documentation in cases with combined Prosthodontics-fixed and removable constructions:	
	
<i>Fig. 24 and 25: Frontal and occlusal view of a fixed construction in upper jaw.</i>	
	
<i>Fig.26: Pictures of the new prosthetic constructions.</i>	<i>Fig.27: Intraoral picture with the new prosthesis in the upper jaw.</i>
	
<i>Fig.28: Intraoral picture with the new prosthesis in central occlusion in full face.</i>	
	
<i>Fig.29 and 30: Intraoral pictures with the new prosthesis in central occlusion in right and left side-view.</i>	

Pictures of the prosthetic constructions on the working casts:

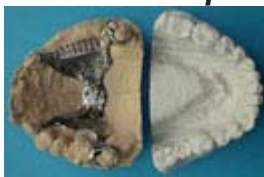

Fig 31: A model cast removable denture -metal frame.

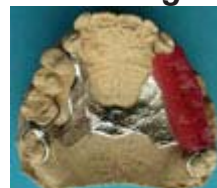

Fig.32: A wax record of central occlusion

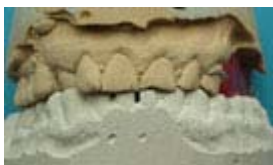

Fig.33. A full face view of the central occlusion on working casts.



Fig.34. A side –view of the jaw interrelation.

Results and Conclusions

The photo and other documentation help the students in preparing their treatment plan even the patient is not present. By photography the students create habits and abilities to collect and analyze the clinical and paraclinical data and to record the complex clinical data. The so collected information betters the collaboration among the teaching stuff and the evaluating team of professors.

The integrated education as a new and more progressive form of teaching achieves one good advantage in the arranged and precise photo documentation in the complex clinical cases.

The so suggested protocol can be used by post graduating persons for documenting of their cases. The photo documentation can serve as visualization of clinical cases with educational purpose when presenting the cases at students' or at teaching stuff's seminars.

References:

1. Gallegos A.G. Enhancing interprofessional communication through digital photography. *J.Cal Dent Assoc.* 29,752-7,2001.
2. Morley J., Eubank J. Macroesthetic elements of smile design. *JADA* 132,39-47, 2001.
3. Salehiah, J., Little R., Frangadakis, K. Prerestorative considerations for cosmetic dentistry. *J.Cal Dent Assoc.* 30,52-9,2002.