

**RICKETS AND ITS MANAGEMENT: A REVIEW.**

Shashikant.R.Pattan<sup>1</sup>, Mira.P.Doke<sup>1</sup>, Prashant V. Nigwekar<sup>2</sup> Sonali.B.Pawar<sup>1</sup>, Utkarsha D Gharate<sup>1</sup>,  
Shashikant S. Pawar<sup>1</sup>, Sainath Pawar<sup>1</sup>, Komal D. Pansare<sup>1</sup>.

1) Department of Pharmaceutical Chemistry, Pravara Rural College of Pharmacy, Pravaranagar,  
M.S., India.

2) Asst. Professor, Dept. of Pediatrics, Pravara Medical College Loni.

**Summary**

Rickets is bone disorder characterized by mostly soft, weak and deformed bones. The main cause of rickets is mainly lack of adequate calcium and impaired metabolism of vitamin D. It is most frequent disease occurring in children. This vitamin is very important to the body because it helps in the absorption of calcium and phosphate, the minerals responsible for the strength and hardness of the bones. Hereditary rickets is an inherited form of the disease caused when the kidneys are unable to retain phosphate. Nutritional Rickets, Vitamin D Resistant Rickets, Vitamin D Dependant Rickets, Congenital Rickets these are some common types of rickets that are reported. The symptoms disappear with the replacement of deficient calcium, phosphorous, or vitamin D. mainly obtained from food and sunlight. Diagnosis can be done with the help of Blood tests: serum alkaline phosphatase may be high, serum calcium may show low levels of calcium, serum phosphate may be low, arterial blood gases may reveal metabolic acidosis

**Key words-** Rickets, Vitamin D

**Address of correspondence**

Dr. S.R.Pattan,

Head, Department of Medicinal Chemistry, Pravara Rural College of Pharmacy, Pravaranagar, Pin-413736, Maharashtra, India.

Phone: +91 9423787413

*E-mail address:* [shahipattan@yahoo.com](mailto:shahipattan@yahoo.com)

## INTRODUCTION

Rickets is a softening of bones in children due to deficiency of phosphorus or calcium,<sup>[1]</sup> potentially leading to fractures and deformity. Rickets is among the most frequent childhood diseases in many developing countries. The predominant cause is a vitamin D deficiency, but lack of adequate calcium, impaired metabolism of vitamin D, in the diet may also lead to rickets (cases of severe diarrhea and vomiting may be the cause of the deficiency) Although it can occur in adults, the majority of cases occur in children suffering from severe malnutrition, usually result from famine or starvation during the early stages of childhood. Osteomalacia is the term used to describe a similar condition occurring in adults, generally due to a deficiency of vitamin D.<sup>[2]</sup> The origin of the word "rickets" is probably from the Old English dialect word 'wrickken', to twist. The Greek derived word "rachitis" (ραχίτις, meaning "inflammation of the spine") was later adapted as the scientific term for rickets, due chiefly to the words' similarity in sound. *Rickets*, a disease that affects the developing skeletal system of children and other young animals, is the result of the body's inability to absorb calcium and phosphate. The disease is characterized by soft, weak and deformed bones. *Rickets* also occurs in adults, but it is then called osteomalacia because the affected bones are already formed. In adults, Osteomalacia causes the bones of the skeletal system to become weak and soft. Rickets is usually the result of a Vitamin D deficiency. Vitamin D is consumed through a Proper diet and produced by the body with adequate exposure to sunlight. This vitamin is very important to the body because it helps in the absorption of calcium and phosphate. The minerals are responsible for the strength and hardness of the bones. A person with rickets may have severely bowed legs, deformation of the spine, chest and pelvis, bones that break easily and severely stunted growth. In severe cases, the knees bulge or appear very large, and there may also be other visible bone deformations characterized by posture and gait.

**Causes:**

The main cause of rickets is the deficiency of vitamin D caused in the body during childhood. Vitamin D is a fat-soluble vitamin that may be absorbed from the intestines or may be produced by the skin when the skin is exposed to sunlight (ultraviolet light of sunlight helps the body to form vitamin D). The absorbed vitamin D is converted into its active form to act as a hormone to regulate calcium absorption from the intestine and to regulate levels of calcium and phosphate in the bones.

If there is a deficiency of Vitamin D, the body is unable to properly regulate calcium and phosphate levels. When the blood levels of these minerals become too low, it results in destruction of the support matrix of the bones. In rickets, another mechanism in the body works to increase the blood calcium level. The parathyroid gland (four numbers of hormone producing glands, usually located in the neck) may increase its functioning rate to compensate for decreased levels of calcium in the bloodstream. To increase the level of calcium in the blood the hormone destroys the calcium present in the bones of the body and this result in further loss of calcium and phosphorous from the bones. In severe cases, cysts may develop in the bones. Vitamin D deficiency could be caused due to numerous reasons. Vitamin D may be absorbed from food by the intestines or may be produced by the skin when the skin is exposed to sunlight. In its active form, vitamin D acts as a hormone to regulate calcium absorption from the intestine and to regulate levels of calcium and phosphate in the bones. Sunlight is important to skin for production of vitamin D and environmental conditions where sunlight exposure is limited may reduce this source of vitamin D. Lack of vitamin D production by the skin may occur if a person is confined indoors, or works indoors during the daylight hours, or lives in climates with little exposure to sunlight. Because vitamin D is a fat-soluble vitamin, conditions that reduce digestion or absorption of fats will decrease the ability of vitamin D to be absorbed from the intestines. When the body is deficient in vitamin D, it is unable to properly regulate calcium and phosphate levels. If the blood levels of these minerals become too low, other body hormones may stimulate release of calcium and phosphate from the bones to the bloodstream to elevate the blood levels.

Rickets is a bone disease that affects children when these deficiencies occur. It causes progressive softening and weakening of the bones structure. There is a loss of calcium and phosphate from the bones which eventually causes destruction of the supportive matrix. Nutritional causes of rickets occur because of a lack of vitamin D in the diet or in association with malabsorption disorders characterized by poor fat absorption. A dietary lack of vitamin D may occasionally occur in people on a vegetarian diet who do not drink milk products or in people who are lactose intolerant (have trouble digesting milk products). A dietary lack of calcium and phosphorous may also play a part in the nutritional causes of rickets. Rickets caused by a dietary lack of these minerals is rare in developed countries because calcium and phosphorous are present in milk and green vegetables.

Hereditary rickets is an inherited form of the disease caused when the kidneys are unable to retain phosphate. Rickets may also be caused by kidney disorders involving renal tubular acidosis. Occasionally, it can also affect children who have disorders of the liver, do not adequately absorb fats and vitamin D, or cannot convert vitamin D to its active form. Renal osteodystrophy occurs in people with chronic renal failure. The manifestation is virtually identical to that of rickets in children and that of osteomalacia or osteoporosis in adults.

- Hypophosphatemic rickets Etidronate

- Nephropathic early-onset cystinosis
- Sarrouy disease - rickets
- Pseudophosphatasia - rickets
- Avitaminosis - rickets
- Adult hypophosphatasia - childhood rickets
- X-linked hypophosphataemia

- Ethotoin
- Bile acid synthesis defects, congenital, 1 - rickets
- Abderhalden-Kaufmann-Lignac syndrome - rickets
- Autosomal dominant hypophosphatemic rickets
- Proximal renal tubular acidosis
- Hypophosphatasia
- Renal tubular acidosis, distal -- type I - rickets
- McCune-Albright Syndrome - rickets
- Bile acid synthesis defects, congenital, 2 - rickets
- Malabsorption syndrome
- Renal tubular acidosis, distal -- type III - rickets
- Renal tubular acidosis progressive nerve deafness - rickets
- Renal osteodystrophy - rickets
- Lightwood-Albright syndrome - rickets
- Bile acid synthesis defects, congenital, 3 - rickets
- Bile acid synthesis defects - rickets
- Baber's syndrome - rickets
- Hypokalaemic distal renal tubular acidosis
- Vitamin D dependent rickets type 2a

- Nephrolithiasis type 1 - rickets
- Fanconi syndrome - rickets
- Bile acid synthesis defects, congenital, 4 - rickets
- Bartter Syndrome - rickets
- Glutethimide
- Vitamin D dependent rickets type 1
- Nephrolithiasis type 2 - rickets
- Dent syndrome - rickets
- Renal Tubular Acidosis - rickets
- Oncogenic hypophosphatemic osteomalacia - rickets
- Manz syndrome - rickets
- Lowe oculocerebrorenal syndrome - rickets
- Hypophosphatemia, Familial - rickets
- Acid phosphatase deficiency - rickets
- Wilson's disease

The main cause of rickets is the deficiency of vitamin D caused in the body during childhood. Vitamin D is a fat-soluble vitamin that may be absorbed from the intestines or may be produced by the skin when the skin is exposed to sunlight (ultraviolet light of sunlight helps the body to form vitamin D). The absorbed vitamin D is converted into its active form to act as a hormone to regulate calcium absorption from the intestine and to regulate levels of calcium and phosphate in the bones.

If there is a deficiency of Vitamin D, the body is unable to properly regulate calcium and phosphate levels. When the blood levels of these minerals become too low, it results in destruction of the support matrix of the bones. Three common causes of rickets include nutritional rickets, Hypophosphatemic rickets, and renal rickets.

### **Types**

- Nutritional Rickets
- Vitamin D Resistant Rickets
- Vitamin D Dependant Rickets

Type I, Type II

- Congenital Rickets

### **Nutritional rickets**

Nutritional rickets, also called osteomalacia, is a condition caused by vitamin D deficiency. Vitamin D is a fat-soluble vitamin that is essential for the normal formation of bones and teeth and necessary for the appropriate absorption of calcium and phosphorus from the bowels. It occurs naturally in very small quantities in some foods such as saltwater fish (salmon, sardines, herring, and fish-liver oils). Vitamin D is also naturally synthesized by skin cells in response to sunlight exposure. It is necessary for the appropriate absorption of calcium from the gut.

Infants and children most at risk for developing nutritional rickets include dark-skinned infants, exclusively breastfed infants, and infants who are born to mothers who are vitamin D deficient. In addition, older children who are kept out of direct sunlight or who have vegan diets may also be at risk.

### **Hypophosphatemic rickets**

Hypophosphatemic rickets is caused by low levels of phosphate. The bones become painfully soft and pliable. This is caused by a genetic dominant X-linked defect in the ability for the kidneys to control the amount of phosphate excreted in the urine. The individual affected is able to absorb phosphate and calcium, but the phosphate is lost in the urine. This is not caused by a vitamin D deficiency. Patients with Hypophosphatemic rickets typically have obvious symptoms by 1 year of age. Treatment is generally through nutritional supplements of phosphate and calcitriol (the activated form of vitamin D).

### **Renal (kidney) rickets**

Similar to hypophosphatemic rickets, renal rickets is caused by a number of kidney disorders. Individuals suffering from kidney disease often have decreased ability to regulate the amounts of electrolytes lost in the urine. This includes calcium and phosphate, and therefore the affected individuals develop symptoms almost identical to severe nutritional rickets. Treatment of the underlying kidney problem and nutritional supplementation are recommended for these patients. Your body needs vitamin D to absorb calcium and phosphorus from food. Rickets can occur if your child's body doesn't get enough vitamin D or if his or her body has problems using vitamin D properly.

### **You receive vitamin D from two sources**

**Sunlight:** Your skin produces vitamin D when it's exposed to sunlight. But children in developed countries now tend to spend less time outdoors. They're also more likely to use sunscreen, which blocks the rays that trigger the skin's production of vitamin D.

**Food:** Fish oils, fatty fish and egg yolks contain vitamin D. Vitamin D also has been added to some foods, such as milk, cereal and some fruit juices. Children who don't eat enough of these fortified foods can develop a vitamin D deficiency.



## Sign & Symptoms

Signs and symptoms of rickets include:

- Bone pain or tenderness
- dental problems
- muscle weakness (rickety myopathy or "floppy baby syndrome" or "slinky baby" (where the baby is floppy or slinky-like)
- increased tendency for fractures (easily broken bones), especially greenstick fractures
- Skeletal deformity
- Toddlers: Bowed legs (Genu varum)
- Older children: Knock-knees (Genu valgum) or "windswept knees"
- Cranial, spinal, and pelvic deformities
- Growth disturbance
- Hypocalcemia (low level of calcium in the blood), and
- Tetany (uncontrolled muscle spasms all over the body).
- Craniotabes (soft skull)
- Costochondral swelling (aka "rickety rosary" or "rachitic rosary")
- Harrison's groove
- Double malleoli sign due to metaphyseal hyperplasia
- Widening of wrist raises early suspicion, it is due to metaphysial cartilage hyperplasia.[1]

An X-ray or radiograph of an advanced sufferer from rickets tends to present in a classic way: bow legs (outward curve of long bone of the legs) and a deformed chest. Changes in the skull also occur causing a distinctive "square headed" appearance. These deformities persist into adult life if not treated. Long-term consequences include permanent bends or disfiguration of the long bones, and a curved back.

- Bone pain i.e.

Arms , Pelvis, Legs, Spine

- Dental deformities

Delayed formation of teeth

Decreased muscle tone (loss of muscle strength)

Defects in the structure of teeth; holes in the enamel

Increased cavities in the teeth (dental caries)

- Impaired growth
- Increased bone fractures
- Muscle cramps
- Short stature (adults less than 5 feet tall) Skeletal deformities

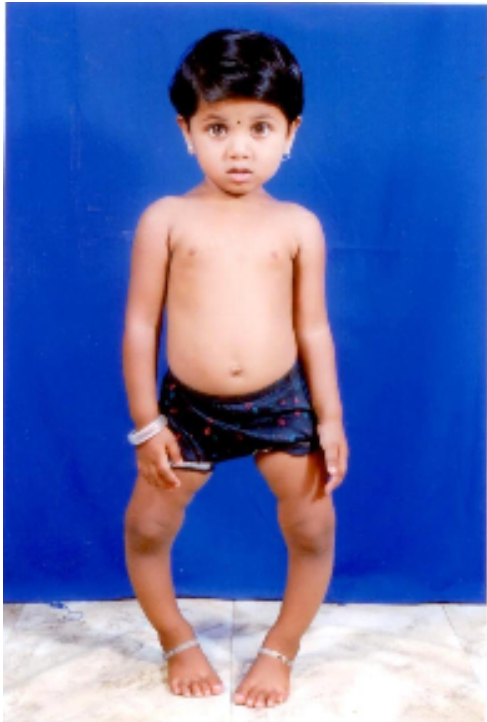Asymmetrical or odd-shaped skull

Bowlegs

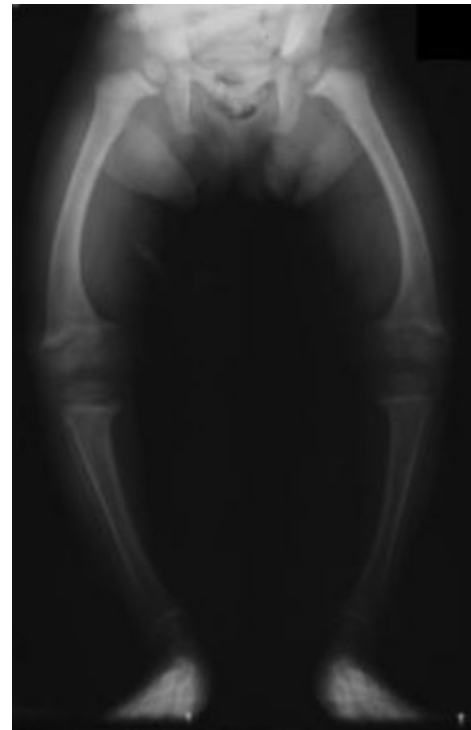
Bumps in the ribcage (rachitic rosary)

Breastbone pushed forward (pigeon chest) Pelvic deformities

- Spine deformities (spine curves abnormally, including scoliosis or kyphosis)



Pravara Rural College of Pharmacy , Loni.  
Has treated this disease under the guidance  
of Dr.Pattan. S.R.



Radiograph of a two-year old rickets sufferer, with a  
marked genu varum (bowing of the femurs)  
and decreased bone opacity, suggesting poor bone  
mineralization.

The symptoms of rickets include bowed legs and bowed arms. The bowed appearance is due to the softening of bones and their bending, if the bones are weight bearing.

Bone growth occurs through the creation of new cartilage, a soft substance at the ends of bones. When the mineral calcium phosphate is deposited on to the cartilage, a hard structure is created. In vitamin D deficiency, though calcium is not available to create hardened bone, and the result is soft bone. Other symptoms of rickets include particular bony bumps on the ribs called rachitic rosary (beadlike prominences at the junction of the ribs with their cartilages) and knock-knees. Seizures may also occasionally occur in a child with rickets, because of reduced levels of dissolved calcium in the

bloodstream. Hypophosphatemic rickets usually begins in the first year of life. It ranges from so mild that it produces no noticeable symptoms to so severe that it produces bowing of the legs and other bone deformities, bone pain, and a short stature. Bony outgrowth where muscles attach to bones may limit movement at those joints. A baby's skull bones may close too soon, leading to seizures pain in the bones of Arms, Legs, Spine, Pelvis.

Skeletal deformities including Bow legs, Forward projection of the breastbone (pigeon chest or pectus carinatum), Funnel chest (pectus excavatum), "Bumps" in the rib cage (rachitic rosary) and Asymmetrical or odd-shaped skull.

- Spine deformities (spine curves abnormally, including scoliosis or kyphosis).
- Pelvic deformities.
- Increased tendency toward bone fractures.
- Dental deformities.
- Delayed formation of teeth.
- Defects in the structure of teeth, holes in the enamel.
- Increased incidence of cavities in the teeth (dental caries).
- Progressive weakness.
- Decreased muscle tone (loss of muscle strength)
- Muscle cramps.
- Impaired growth.
- Short stature (adults less than 5 feet tall).
- Fever or restlessness, especially at night.

### **Epidemiology:**

In developed countries, rickets is a rare disease<sup>[7]</sup> (incidence of less than 1 in 200,000).

Those at higher risk for developing rickets include:

- Breast-fed infants whose mothers are not exposed to sunlight
- Breast-fed infants who are not exposed to sunlight
- Babies with dark complexions (e.g. brown skin, South African), particularly when breastfed and exposed to little sunlight
- Individuals not consuming milk, such as those who are lactose intolerant

Individuals with red hair have been speculated to have a decreased risk for rickets due to their greater production of vitamin D in sunlight.

Children ages 6 months to 24 months are at highest risk, because their bones are rapidly growing. Long-term consequences include permanent bends or disfiguration of the long bones, and a curved back.

### **Pathophysiology**

Rickets/osteomalacia is a disorder causing mineralization defect and bone and skeletal fragility, although production of bone matrix proteins and their architecture is not impaired. The disease is called rickets and osteomalacia in children during skeletal development and in adults, respectively. Pathophysiology in rickets/osteomalacia is defect in vitamin D actions and/or hypophosphatemia. Vitamin D deficiency, inability of activation of vitamin D in vivo or functional derangement in vitamin D receptor is involved in impaired actions of vitamin D. Common causes of hypophosphatemia are excessive actions of fibroblast growth factor (FGF) 23 and renal tubular dysfunction. Among them

FGF23 could be a principal regulator for phosphate metabolism, and many investigators are engaged in exploration of physiological and pathophysiological roles of FGF23 in human.

**To improve understanding of the biochemical events in vitamin D-deficiency rickets (VDR).**

**Methods:** We investigated 51 untreated patients, 2 to 36 months of age, during three stages of VDR. Nineteen of these patients were also studied during therapy with 5000 to 10,000 U vitamin D<sub>3</sub> (cholecalciferol) and 0.5 to 1 gm calcium. Together with calcium and inorganic phosphate in serum and urine, we measured (1) parathyroid hormone (PTH) secretion (intact serum PTH) and action on the kidney (urinary adenosine 3',5'-cyclic monophosphate (cAMP)/creatinine ratio; (2) serum alkaline phosphatase level; (3) urinary hydroxyproline/ creatinine ratio; and (4) serum 1,25-dihydroxyvitamin D (1,25[OH]<sub>2</sub>D) level. Results: The untreated patients had secondary hyperparathyroidism (high serum PTH and urinary cAMP/creatinine ratio), low calcium and phosphate concentrations in serum, and increased bone turnover (elevated serum alkaline phosphatase and OHP/creatinine ratio), whereas serum 1, 25(OH)<sub>2</sub>D was low, normal, or even slightly elevated. Serum calcium level was positively correlated to serum 1, 25(OH)<sub>2</sub>D and to OHP/creatinine ratio, indicating that normocalcemia in untreated rickets (stage 2) is at least partially maintained by 1,25(OH)<sub>2</sub>D- induced calcium mobilization from bone. There was no correlation between serum calcium and serum PTH, or between serum PTH and urinary cAMP/creatinine ratio or serum phosphate, indicating disturbed regulation and action of PTH. During vitamin D treatment, serum 1, 25(OH)<sub>2</sub>D values increased to supranormal concentrations in association with the restoration of the physiologic relationship of PTH to serum calcium and phosphate concentrations and urinary cAMP/creatinine ratio. Conclusion: Circulating 1, 25(OH)<sub>2</sub>D has an important role in the pathophysiology of VDR before and during treatment, mainly by influencing the bone and kidney response to endogenous PTH. (J P EDIATR)

**Diagnosis:**

Rickets may be diagnosed with the help of:

- Blood tests: serum alkaline phosphatase may be high. Serum calcium may show low levels of calcium, serum phosphorus may be low
- Arterial blood gases may reveal metabolic acidosis
- X-rays of affected bones may show loss of calcium from bones or changes in the shape or structure of the bones.
- Bone biopsy is rarely performed but will confirm rickets.

Other tests that are helpful in diagnosing rickets are:

- 1) PTH
- 2) Urine Calcium
- 3) Calcium(ionized)
- 4) ALP (alkaline phosphate) isoenzyme

**Treatment**

- The treatment goals include relieving the symptoms and correcting the underlying cause to prevent recurrence. If the condition is not corrected while children are still growing, skeletal deformities and short stature may be permanent, but if it is corrected while the child is young, skeletal deformities often reduce or disappear with time.
- The symptoms disappear with the the replacement of deficient calcium, phosphorous, or vitamin D.

- Biologically active form of vitamin D could be used in people who have difficulty in converting vitamin D in to its active form.
- Including fish, liver and processed milk which are rich sources of vitamin D in diet.
- Exposure to moderate amounts of sunlight.
- Skeletal deformities could be corrected by maintaining a good posture and bracing could help in reducing the deformities.
- Some skeletal deformities can be corrected only with surgical correction.

The goals of treatment are to relieve symptoms and correct the cause of the condition. The cause must be treated to prevent the disease from returning. Replacing calcium, phosphorus, or vitamin D that is lacking will eliminate most symptoms of rickets. Dietary sources of vitamin D include fish, liver, and processed milk. Exposure to moderate amounts of sunlight is encouraged. If rickets is caused by a metabolic problem, a prescription for vitamin D supplements may be needed. Positioning or bracing may be used to reduce or prevent deformities. Some skeletal deformities may require corrective surgery.

### **Vitamin D Deficiency Rickets: Treatment of Rickets In Children**

Vitamin D deficiency can have serious consequence on health. Called as a sunshine vitamin, vitamin D is responsible for absorption of calcium and regulating it for proper mineralization of bones.

### **Vitamin D Deficiency Rickets**

Deficiency of vitamin D is associated with childhood disease called rickets. In this disease, the bones become soft and form skeletal deformity, this happens because the tissue surrounding the bones becomes weak. The list of treatments mentioned in various sources for Rickets includes the following list. Always seek professional medical advice about any treatment or change in treatment plans.



- Adequate diet
- High-calcium high-phosphorous diet
- Vitamin D supplements
- Cod liver oil
- Calcium - possibly used if condition is caused by calcium deficiency
- Vitamin D - possibly used if condition is caused by vitamin D deficiency
- Sensible sun exposure
- Diet rich in vitamin D - fortified milks, juices and cereals, oily fish
- High-calcium high-phosphorous diet
- Vitamin D supplementation

### **Treating rickets**

Rickets that is caused by a dietary deficiency or a lack of sun exposure is treated by:

- regular (daily) calcium and vitamin D supplements
- a vitamin D injection each year, or
- by eating more calcium-rich food

### **Treating complications**

If your child has a bone deformity as a result of rickets, such as bowed legs or a curvature of the spine, your doctor may suggest treatment to correct it. This might be a special brace to position your child's body appropriately as their bones grow, or they may need to have surgery.

### **Side effects of treatment**

It is very unusual to get side effects from vitamin D, calcium or phosphates if they are given in the right dose. However, if doses are too high this can raise calcium levels in the blood, causing a condition called hypercalcaemia. Symptoms of hypercalcaemia include:

- passing a lot of urine
- thirst and a reduced appetite
- nausea and vomiting
- dizziness and headaches

The treatment goals include relieving the symptoms and correcting the underlying cause to prevent recurrence. If the condition is not corrected while children are still growing, skeletal deformities and short stature may be permanent, but if it is corrected while the child is young, skeletal deformities often reduce or disappear with time.

The symptoms disappear with the replacement of deficient calcium, phosphorous, and/or vitamin D.

Biologically active form of vitamin D could be used in people who have difficulty in converting vitamin D to its active form.

Including fish, liver and processed milk, which are rich sources of vitamin D in the diet.

Exposure to moderate amounts of sunlight.

Skeletal deformities could be corrected by maintaining a good posture and bracing could help in reducing the deformities. Some skeletal deformities can be corrected only with surgical correction.

**Prevention:**

Methods of prevention of Rickets mentioned in various sources include those listed below. This prevention information is gathered from various sources, and may be inaccurate or incomplete. None of these methods guarantee prevention of Rickets.

- Sunlight exposure
- Vitamin D
- Adequate diet
- Cod liver oil - a good source of Vitamin D

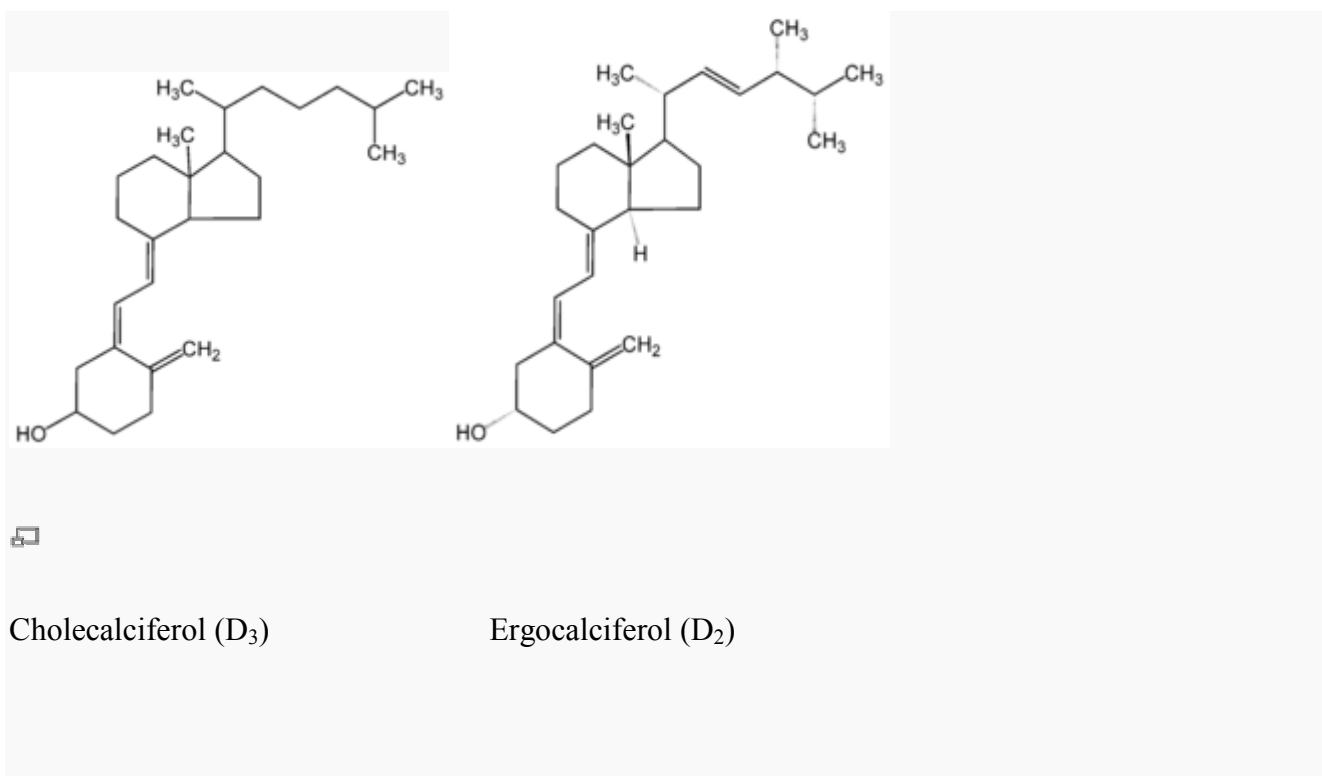
A blood test may be done to measure the amounts of the minerals calcium and phosphorus. X-rays of the affected bones are obtained and a musculoskeletal examination reveals tenderness or pain of the bone itself, rather than in the joints or muscles. In some occasions, a bone biopsy, in which a small sample of bone tissue is removed for analysis, also may be needed to confirm the diagnosis.

Other tests that are helpful in diagnosing rickets are:

- 1.PTH
- 2.Urine calcium
- 3.Calcium (ionized)
- 4.ALP (alkaline phosphatase) isoenzyme

**Treatment & Prevention :**

The treatment and prevention of rickets is known as *antirachitic*.



Treatment involves increasing dietary intake of calcium, phosphates and vitamin D. Exposure to ultraviolet B light (sunshine when the sun is highest in the sky), cod liver oil, halibut-liver oil, and viosterol are all sources of vitamin D.

A sufficient amount of ultraviolet B light in sunlight each day and adequate supplies of calcium and phosphorus in the diet can prevent rickets. Darker-skinned babies need to be exposed longer to the ultraviolet rays. The replacement of vitamin D has been proven to correct rickets using these methods of ultraviolet light therapy and medicine.

Recommendations are for 400 international units (IU) of vitamin D a day for infants and children. Children who do not get adequate amounts of vitamin D are at increased risk of rickets. Vitamin D is essential for allowing the body to uptake calcium for use in proper bone calcification and maintenance.

### **Supplementation**

Sufficient vitamin D levels can also be achieved through dietary supplementation and/or exposure to sunlight. Vitamin D<sub>3</sub> (cholecalciferol) is the preferred form since it is more readily absorbed than vitamin D<sub>2</sub>. Most dermatologists recommend vitamin D supplementation as an alternative to unprotected ultraviolet exposure due to the increased risk of skin cancer associated with sun exposure. Endogenous production with full body exposure to sunlight is approximately 250 µg (10,000 IU) per day. <sup>[5]</sup>

### **CONCLUSION**

The present review reveals the causes and disorder of rickets results in the improper bone formation, teeth and cartilage etc. Various type of ricketcia have been studied here, genetic factor and hereditary is one of the reason for such disorder. Lack of retention of “phosphate” results in the hyperphosphatase enzyme in such cases phosphate supply should be given with other calcium supplements. Ricket is a disease but causes permanent disorder.

**REFERENCES:**

1. Nield LS, Mahajan P, Joshi A, Kamat D. Rickets: not a disease of the past. *Am Fam Physician*. 2006; 74: 619-62
2. MedlinePlus Medical Encyclopedia: Osteomalacia
3. *Daily Telegraph*, page 4, Wednesday 19 January 2011
4. Vieth R (May 1999). "Vitamin D supplementation, 25-hydroxyvitamin D concentrations, and safety". *The American Journal of Clinical Nutrition* 69 (5): 842–56. PMID 10232622.
5. Gartner LM, Greer FR (April 2003). "Prevention of rickets and vitamin D deficiency: new guidelines for vitamin D intake". *Pediatrics* 111 (4 Pt 1): 908-10
6. National Health Service of England > Rickets Last reviewed: 28 January 2010
7. London: HMSO,1986
8. Anderson HR. Increase in hospitalization for childhood asthma. *Arch Dis Child* 1978;53:295-300
9. Narchi H, El Jamil M, Kulaylat N. Symptomatic rickets in adolescence. *Arch Dis Child* 2001;84:501-3
10. Harrison HE, Harrison HC: Disorders of calcium and phosphate metabolism in childhood and adolescence. Philadelphia: WB Saunders Co. 1979.
11. Kreiter SR, Schwartz RP, Kirkman HN Jr, Charlton PA, Calikoglu AS, Davenport ML. Nutritional rickets in African American breast-fed infants. *J Pediatr*. 2000;137:153-157
12. Fuller KE, Casparian JM. Vitamin D: balancing cutaneous and systemic considerations. *South*

Med J. 2001;94:58-64

13. Okonofua F, Gills DS, Alabi ZO, Thomas M, Bell JL, Dandona P. Rickets in Nigerian children: a consequence of calcium malnutrition. *Metabolism* 1991;40:209-13
14. Juppner H. Receptors for parathyroid hormone and parathyroid hormone-related peptide: exploration of their biological importance. *Bone* 1999;25:87-90
15. <http://bone-muscle.health-cares.net/rickets-causes.php>
16. [http://www.medindia.net/patients/patientinfo/rickets\\_causes.htm#ixzz1DkiTJIU4](http://www.medindia.net/patients/patientinfo/rickets_causes.htm#ixzz1DkiTJIU4).
17. [http://www.medindia.net/patients/patientinfo/rickets\\_symptoms.htm#ixzz1DkjiPpdJ](http://www.medindia.net/patients/patientinfo/rickets_symptoms.htm#ixzz1DkjiPpdJ)